


Understand first, then memorize and apply



100 must important GA conceptions

Dr. Mavrych, MD, PhD, DSc
Professor of Gross anatomy, SMU

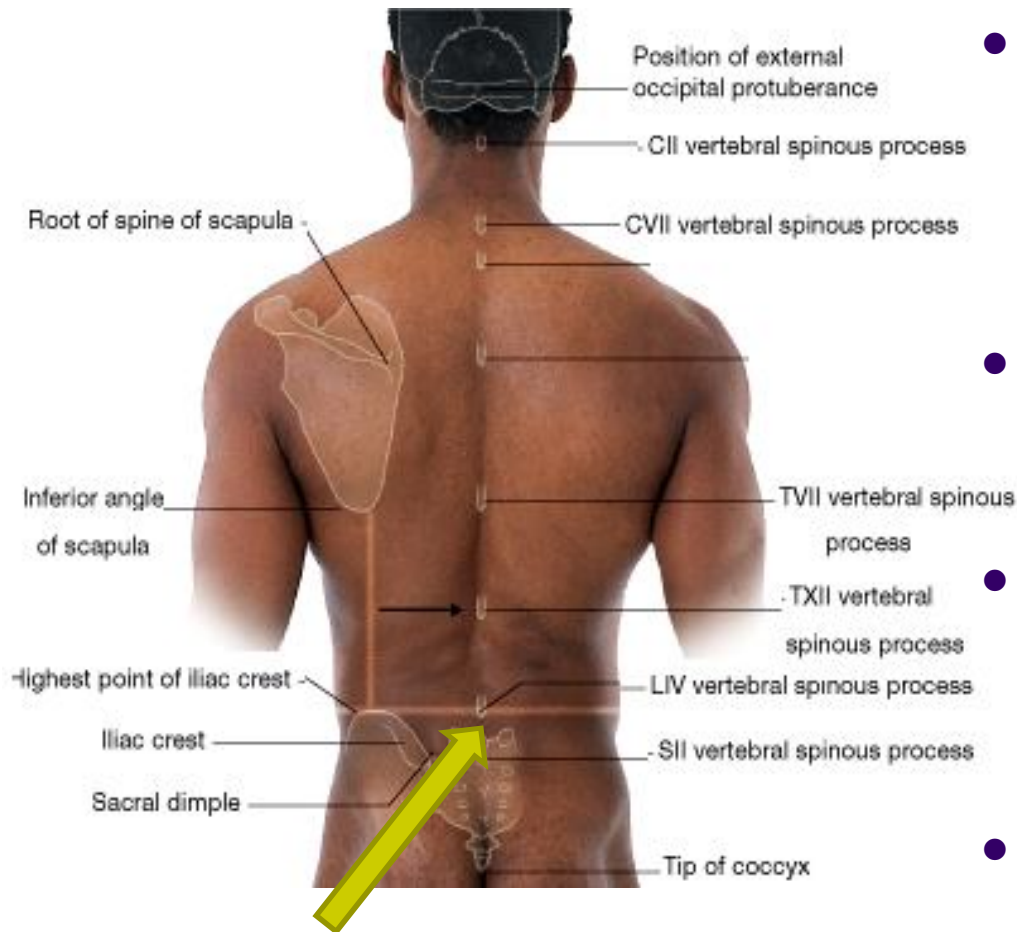




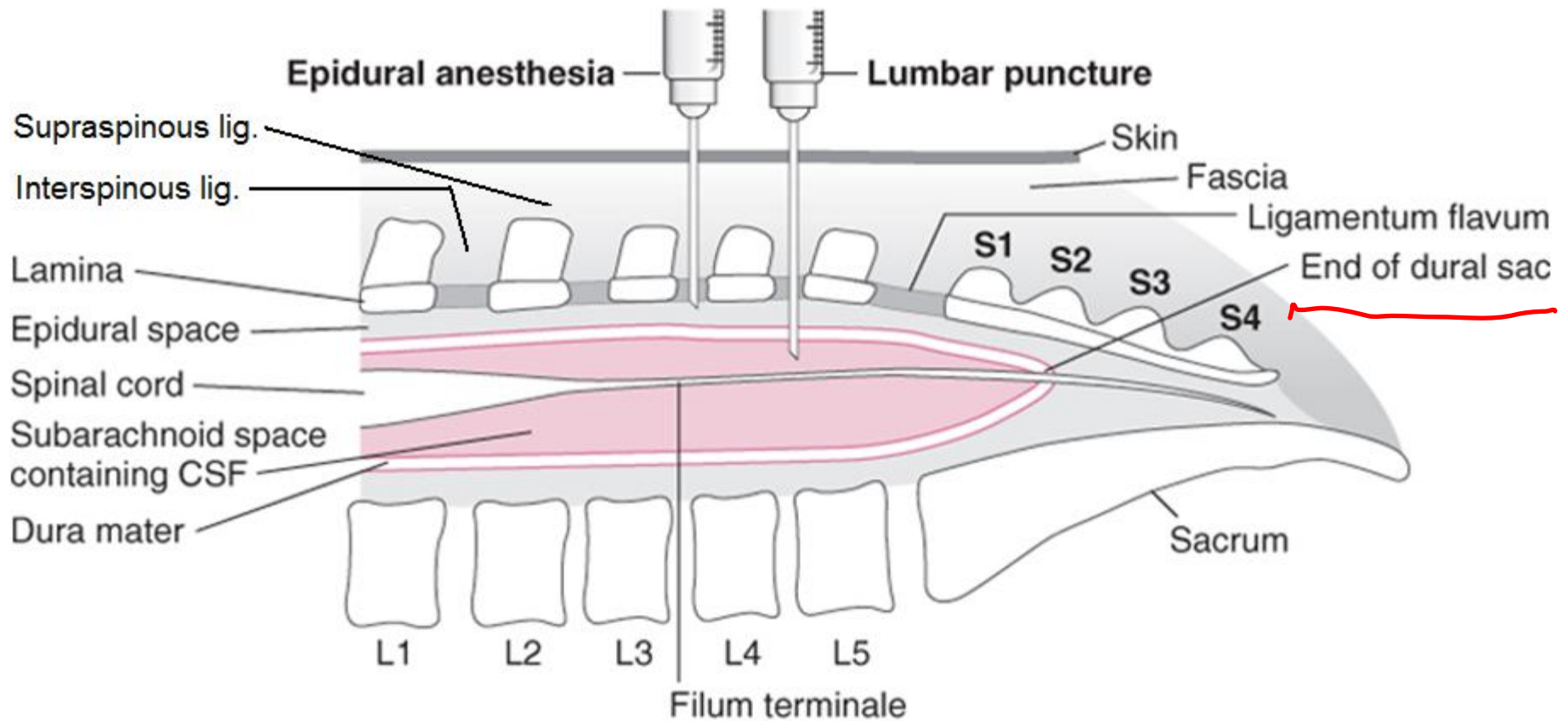

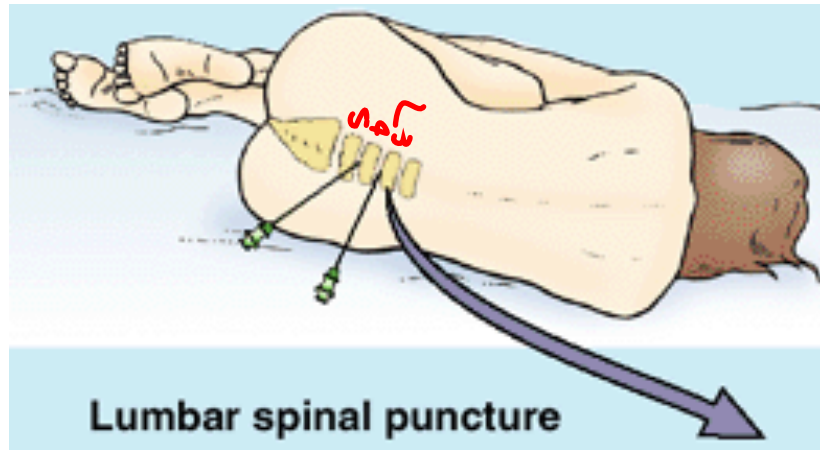
- *You can use this presentation like a guide during your preparing for final GA exam.*
- *It does NOT cover all the material of the Gross Anatomy course.*
- *To complete GA material you have to work with ALL professor's presentations.*
- *Good Luck and All the best!*

Dr. Mavrych

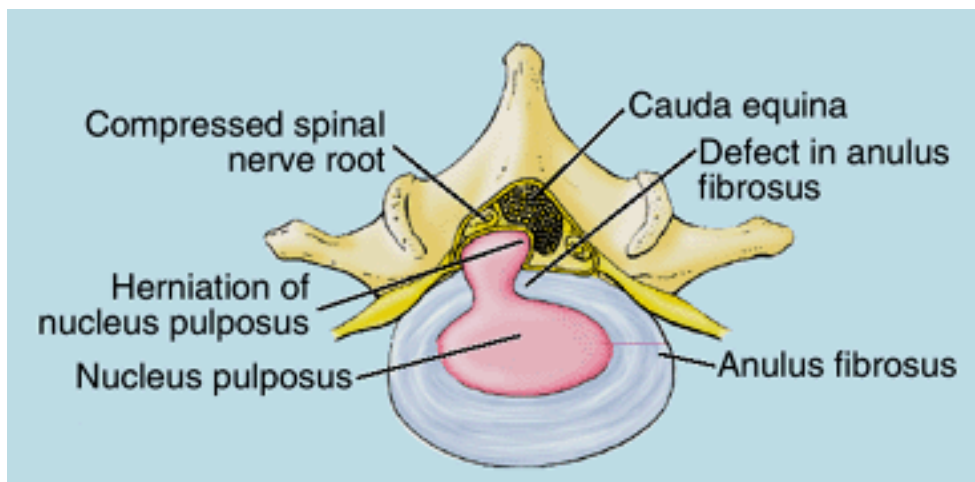
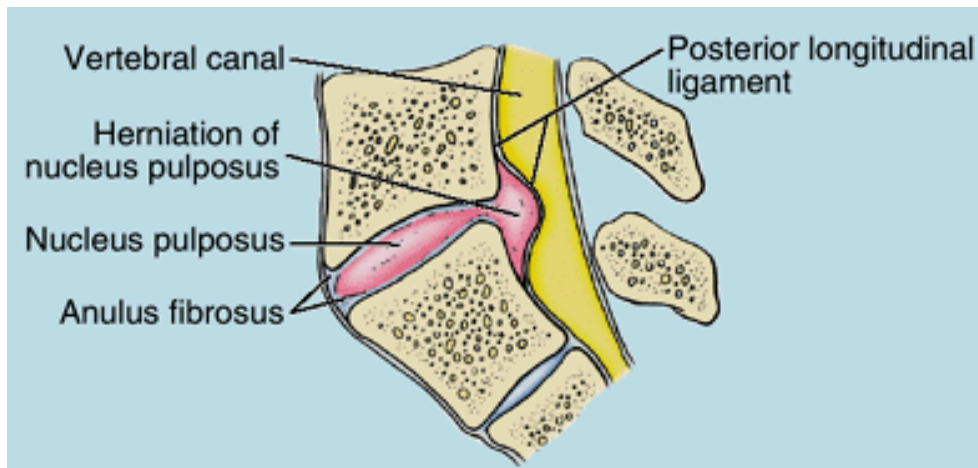
1. Lumbar puncture (tap) and Epidural anesthesia



- When a **lumbar puncture** is performed, the needle enters the subarachnoid space to extract cerebrospinal fluid (spinal tap) or to inject anesthetic (spinal block) or contrast material.
- The needle is usually inserted between **L3/L4** or **L4/L5**. Level of horizontal line through upper points of iliac crests.
- Remember, the spinal cord may end as low as **L2** in adults and does end at L3 in young children and dural sac extends caudally to level of **S2**.
- Before the procedure, the patient should be examined for signs of **increased intracranial pressure** because cerebellar tonsils may herniate through the foramen magnum.

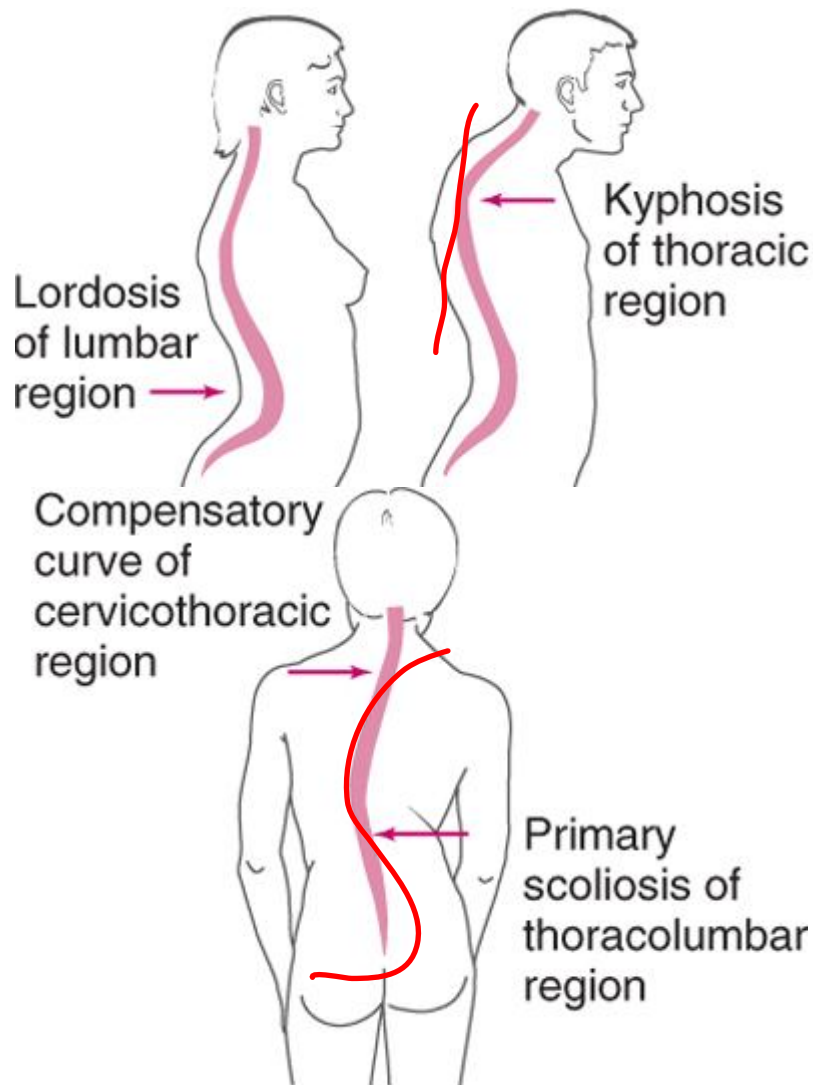


2. Herniated IV disc



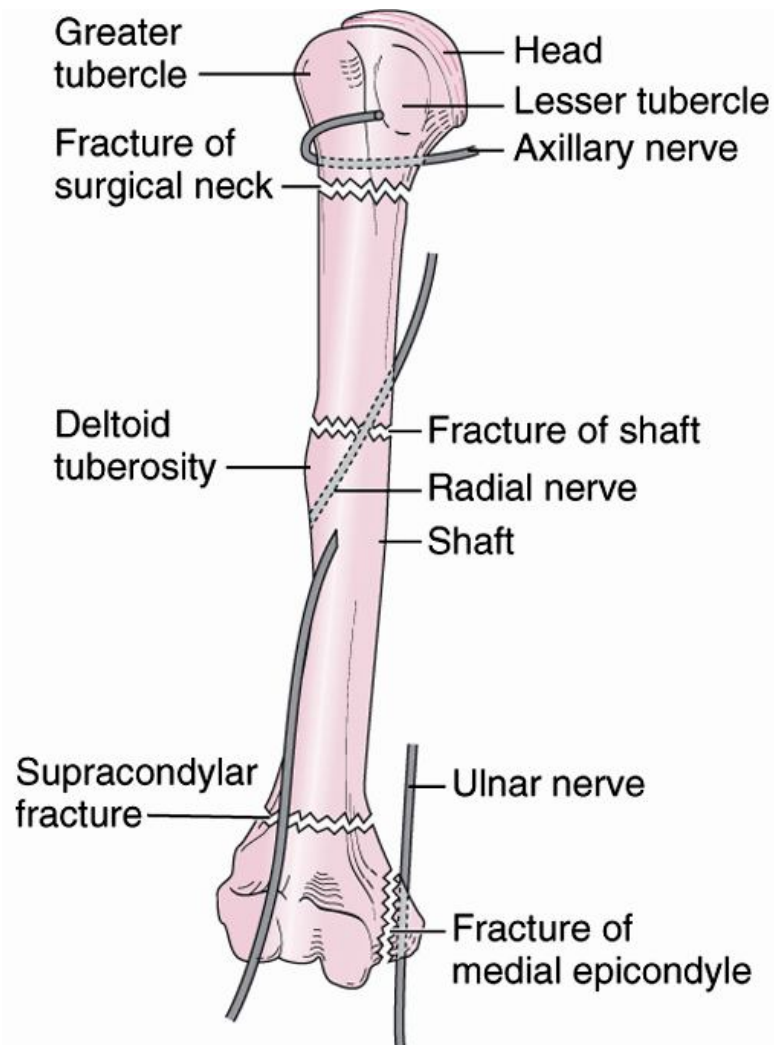
- Herniated discs usually occur in lumbar (**L4/L5** or **L5/S1**) or cervical regions (**C5/C6** or **C6/C7**) of individuals **younger than** age 50. *انزل*
- Herniations may follow **degenerative** changes in the anulus fibrosus and be caused by **sudden compression** of the nucleus pulposus.
- Herniated lumbar discs usually involve the nerve root **one number below** - traversing root (e.g., the herniation L4/L5 will compress L5 root).

3. Abnormal curvatures of the spine



- **Kyphosis** is an exaggeration of the thoracic curvature that may occur in elderly persons as a result of **osteoporosis** (multiply compression fracture of vertebral bodies) or disk degeneration.
- **Lordosis** is an exaggeration of the lumbar curvature that may be temporary and occurs as a result of pregnancy, **spondylolisthesis** or potbelly.
- **Scoliosis** is a complex **lateral deviation**, or torsion, that is caused by poliomyelitis, a leg-length discrepancy, or hip disease.

4. Upper limb fractures: Humerus fractures



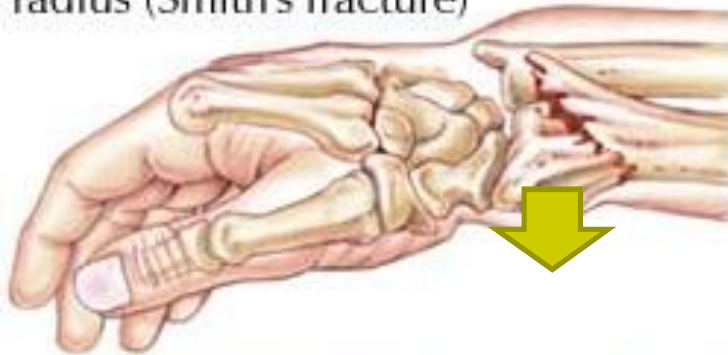Sites of potential injury to major nerves in fractures of the humerus:

1. **Axillary nerve** and posterior humeral circumflex artery at the **surgical neck**.
2. **Radial nerve** and profunda brachii artery at **midshaft**.
3. Brachial artery and **median nerve** at the **supracondylar region**.
4. **Ulnar nerve** at the **medial epicondyle**.

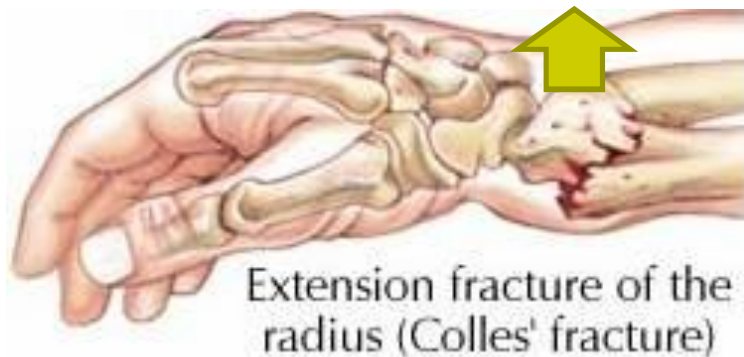


Fracture of distal radius:

Flexion fracture of the radius (Smith's fracture)



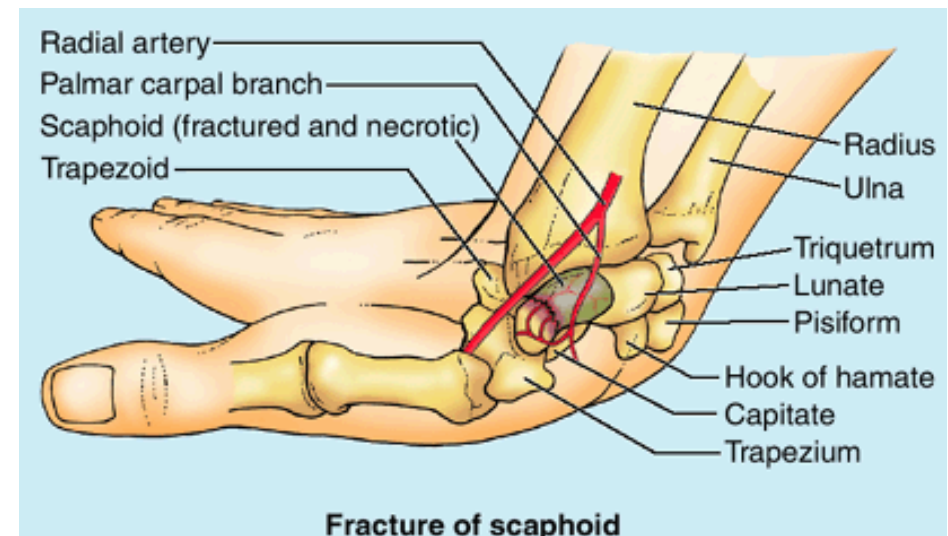
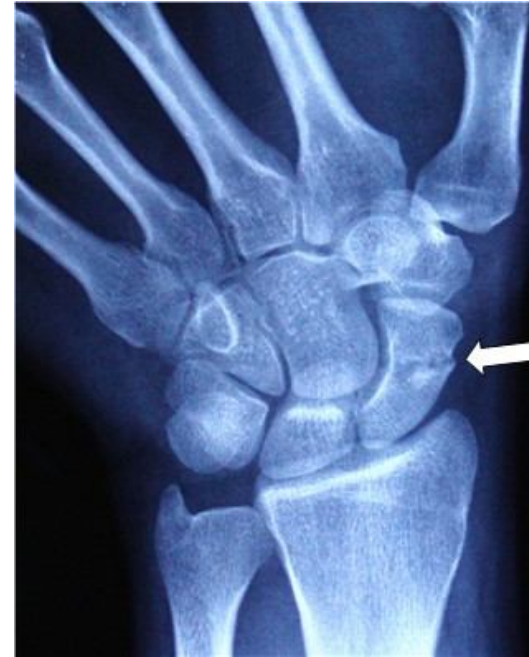- Transverse fracture within the **distal 2 cm** of the radius. Most **common** fracture of the forearm (after 50).
- **Smith's fracture** results from a fall or a blow on the **dorsal aspect** of the **flexed wrist** and produces a ventral angulation of the wrist. The distal fragment of the radius is **ANTERIORLY** displaced.
- **Colles' fracture** results from forced **extension** of the hand, usually as a result of **trying to ease** a fall by outstretching the upper limb. Distal fragment is **displaced DORSALLY** - "**dinner fork deformity**". Often the **ulnar styloid** process is **avulsed** (broken off)



Extension fracture of the radius (Colles' fracture)

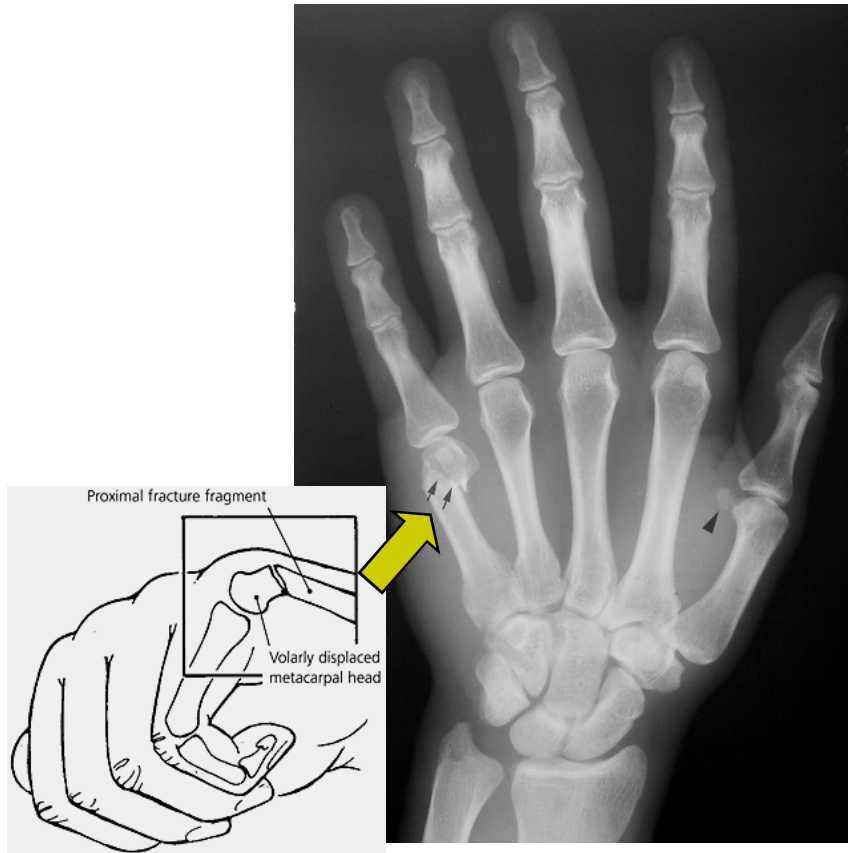Scaphoid fracture

- Occurs as a result of a **fall onto the palm** when the hand is abducted
- Pain occurs primarily on the **lateral side** of the wrist, especially during wrist extension and abduction
- Scaphoid fracture may not show on X-ray films for 2 to 3 weeks, but a **deep tenderness** will be present in the **anatomical snuffbox**.
- The proximal fragment may undergo **avascular necrosis** because the blood supply is interrupted.





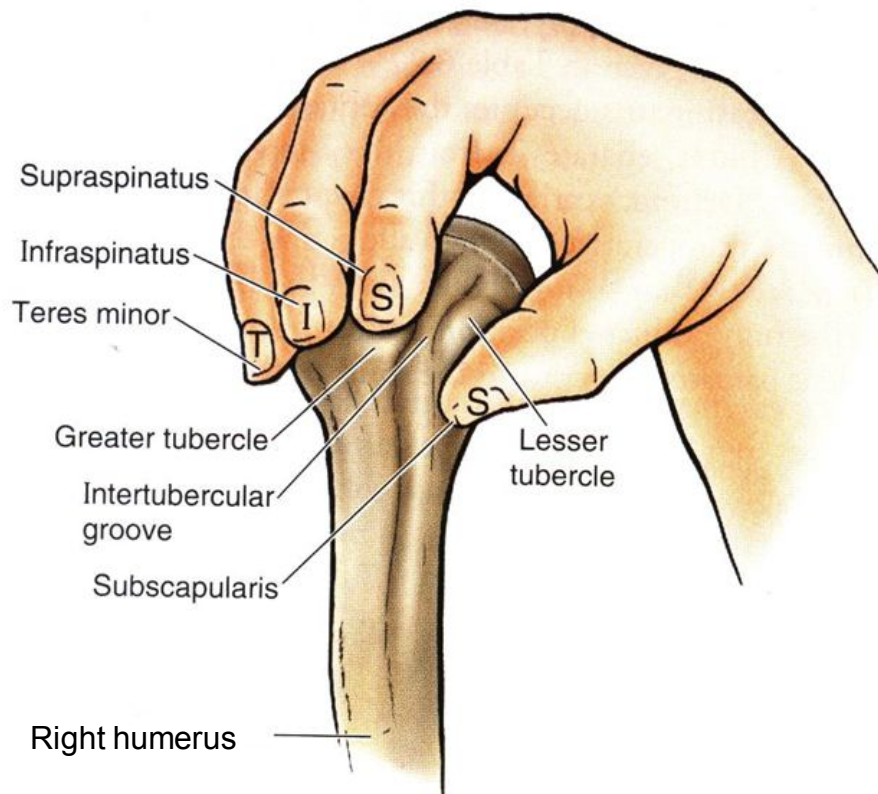
Boxer's fracture



- **Necks of the metacarpal bones are frequently fractured** during fistfights.
- Typically, fractured **2^d** and **3^d** metacarpals are seen in **professional** boxers, and fractured **5th** and sometimes **4th** metacarpals are seen in **unskilled** fighters.



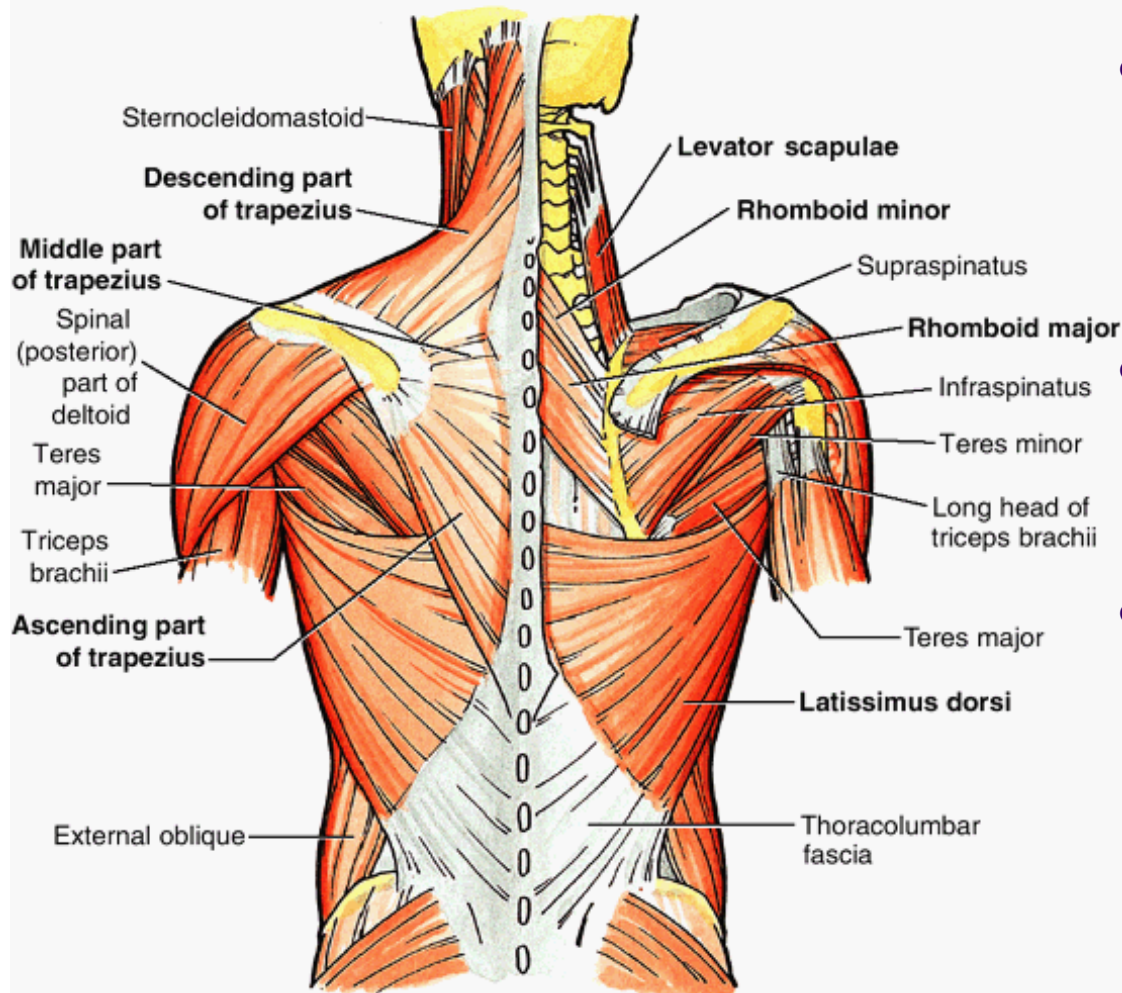
5 Rotator cuff muscles – SITS



- **Support** the shoulder joint by forming a musculotendinous rotator cuff around it
- **Reinforces joint** on all sides **except inferiorly**, where dislocation is most likely
- Rotator cuff muscles are Supraspinatus, Infraspinatus, Teres minor, Subscapularis: **SITS.**

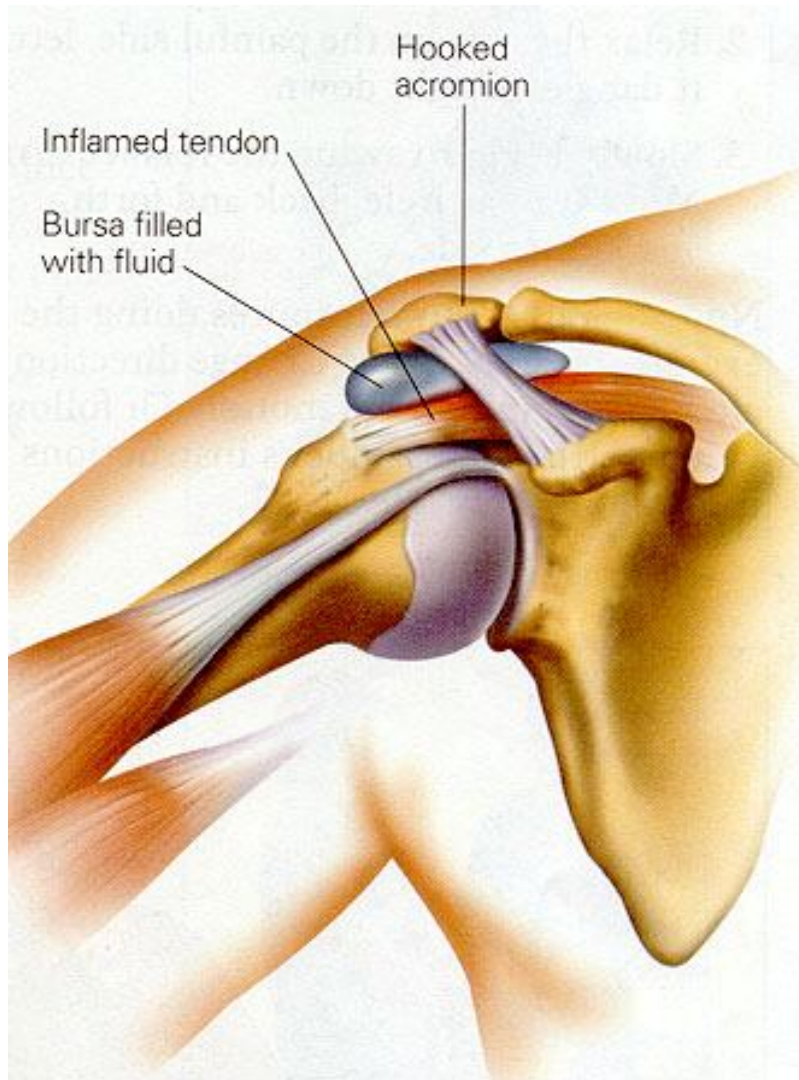


6. Abduction of the upper limb

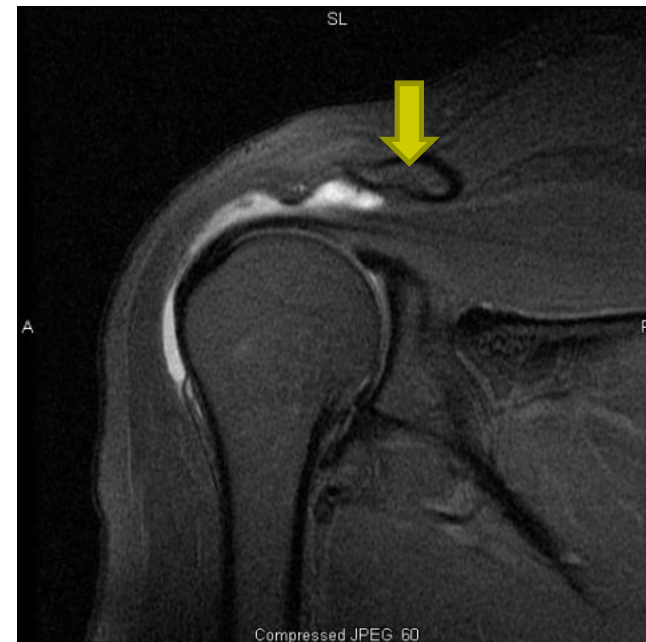

- (0° - 15°) Abduction of the upper extremity is initiated by the **supraspinatus muscle** (suprascapular nerve).
- (15° - 110°) Further abduction to the horizontal position is a function of the **deltoid muscle** (axillary nerve).
- (110° - 180°) Raising the extremity above the horizontal position requires scapular rotation by action of the **trapezius** (accessory nerve CNXI) and **serratus anterior** (long thoracic nerve).

Subacromial bursitis



- **Subacromial bursitis** (inflammation of the subacromial bursa) is often due to **calcific supraspinatus tendinitis**, causing a painful arc of abduction.



7. Medial (golfer's elbow) and lateral (tennis elbow) epicondylitis

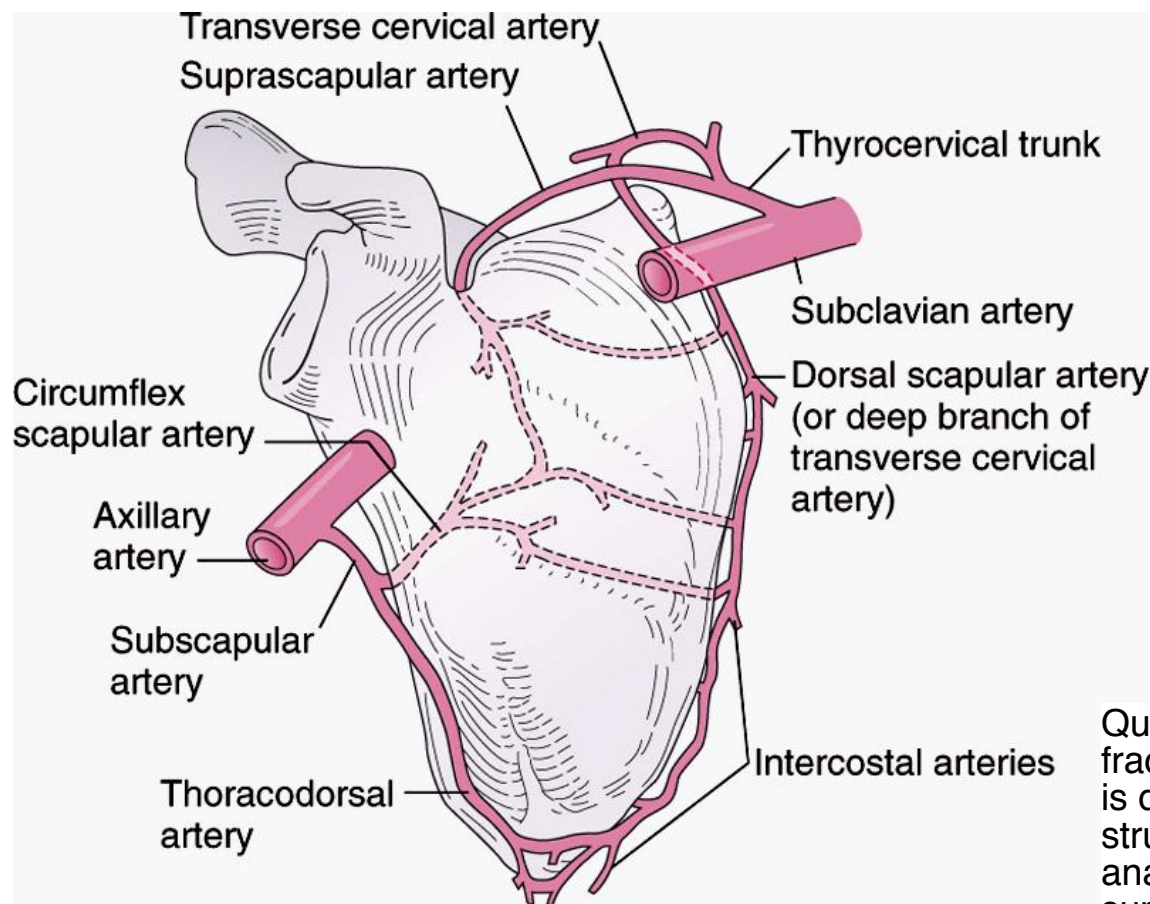


- **Medial epicondylitis** is inflammation of the common **flexor tendon** of the wrist where it originates on the **medial epicondyle** of the humerus.



- **Lateral epicondylitis:** repeated forceful flexion and extension of the wrist resulting strain attachment of **common extensor tendon** and inflammation of periosteum of **lateral epicondyle**. Pain felt **over lateral epicondyle and radiates down posterior aspect of forearm**. Pain often felt when **opening a door or lifting a glass**

8. Arterial anastomoses around the scapula

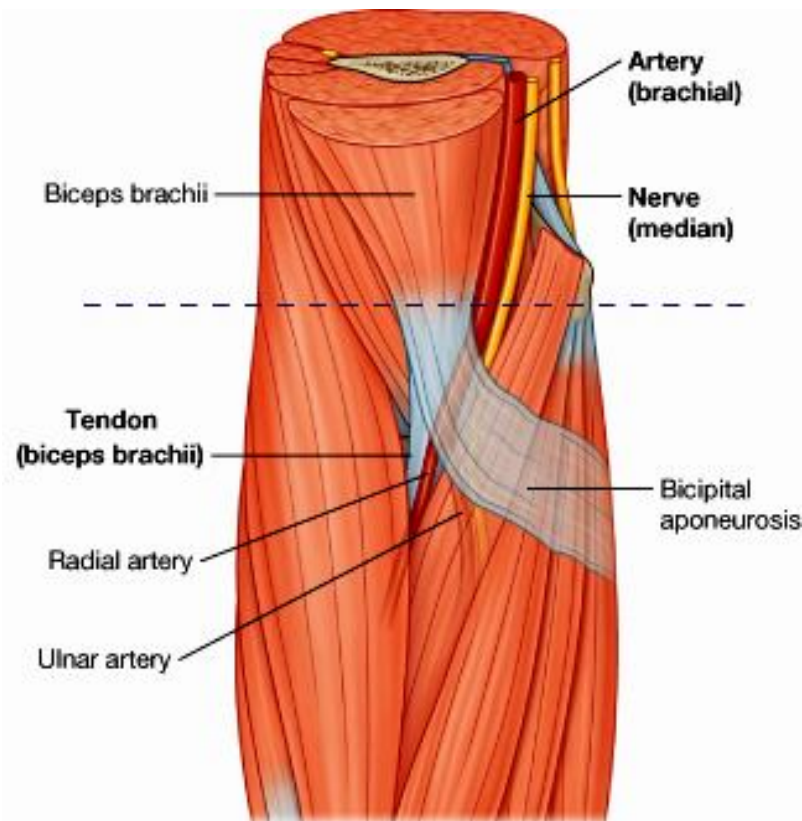


- **Blockage of the Subclavian or Axillary artery** can be bypassed by anastomoses between branches of the **Thyrocervical** and **Subscapular** arteries:

- **Transverse cervical**
- **Suprascapular**
- **Subscapular**
- **Circumflex scapular**

Question tells you that there's a surgical neck fracture, and they also tell you that the axillary nerve is damaged, so the QUESTION is asking you what 2 structures (veins/arteries, I can't remember) will anastomose here so that the limb will still get supplied

9. Cubital fossa

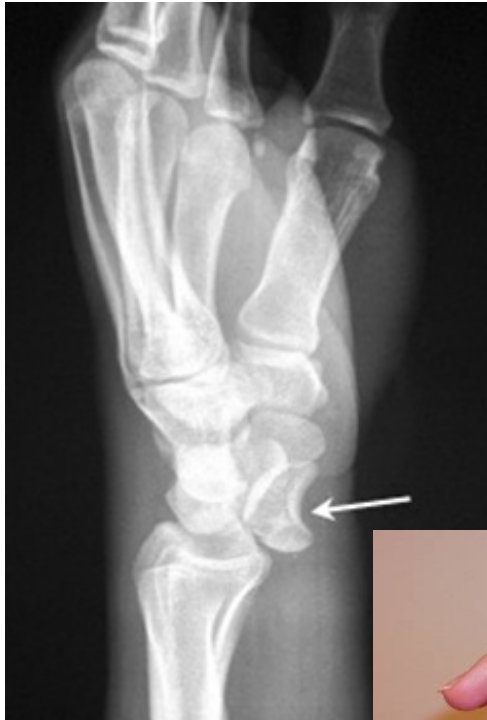


- Contents from **lateral to medial**:
 1. **Biceps brachii tendon**
 2. **Brachial artery**
 3. **Median nerve**
- Subcutaneous structures from **lateral to medial**:
 1. **Cephalic vein**
 2. **Median cubital vein**: joins cephalic and basilic veins
 3. **Basilic vein**
- Sites of venipuncture is usually **median cubital vein** because:
 - Overlies bicipital aponeurosis, so deep structure protected
 - Not accompanied by nerves

TAN

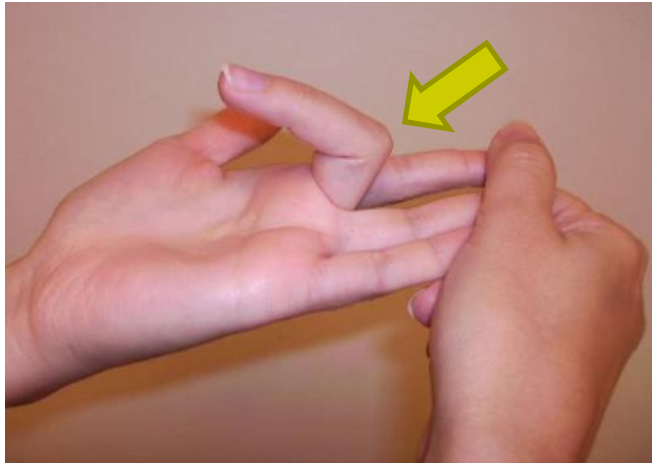


10. Carpal Tunnel Syndrome



- Results from a lesion that **reduces** the size of the carpal tunnel (fluid retention, infection, **dislocation of lunate bone**)
- **Median** nerve – most sensitive structure in the carpal tunnel and is the most affected
- **Clinical manifestations:**
 - Pins and needles or anesthesia of the **lateral 3.5 digits**
 - **palm** sensation **is not affected** because superficial palmar cutaneous branch passes superficially to carpal tunnel
 - **Apehand deformity** - **absent of OPPOSITION**

11. Test of the proximal and distal interphalangeal joints



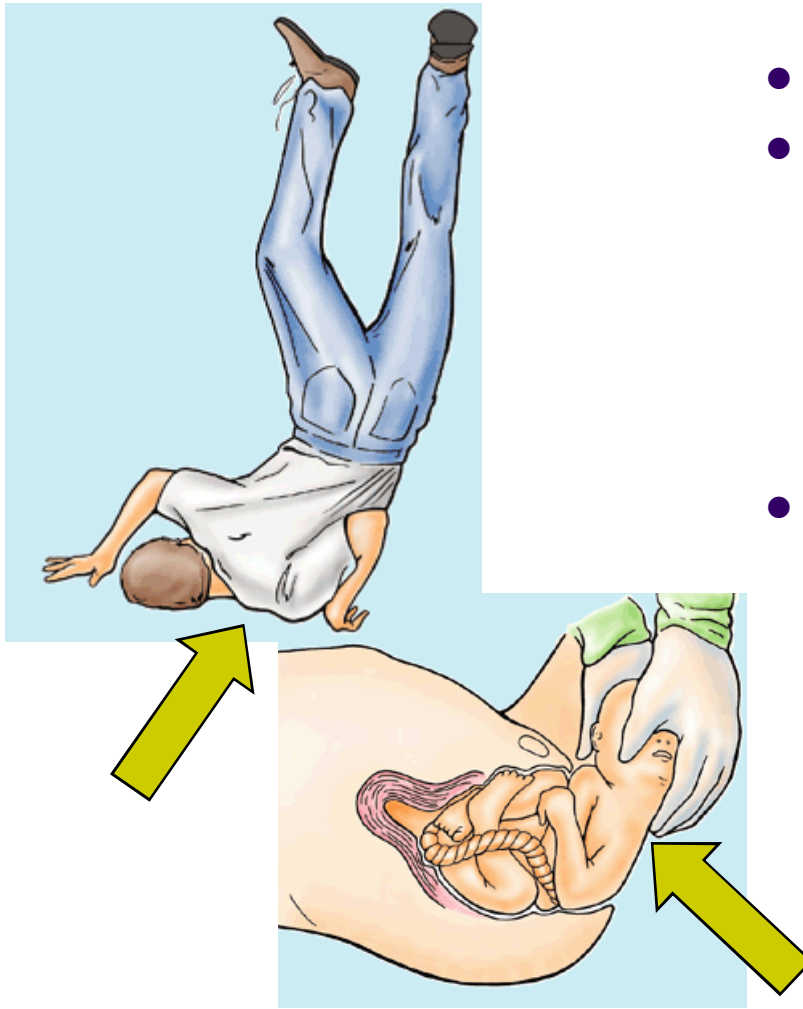
- PIP – FDS



- DID - FDP

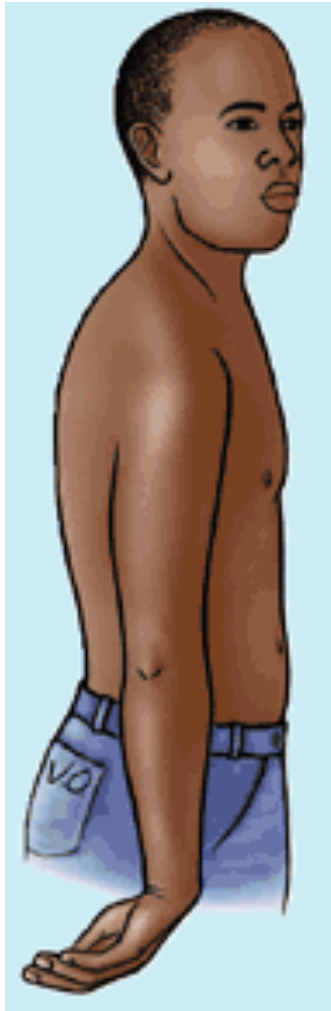12. Lesion of UL nerves

Upper Brachial Palsy



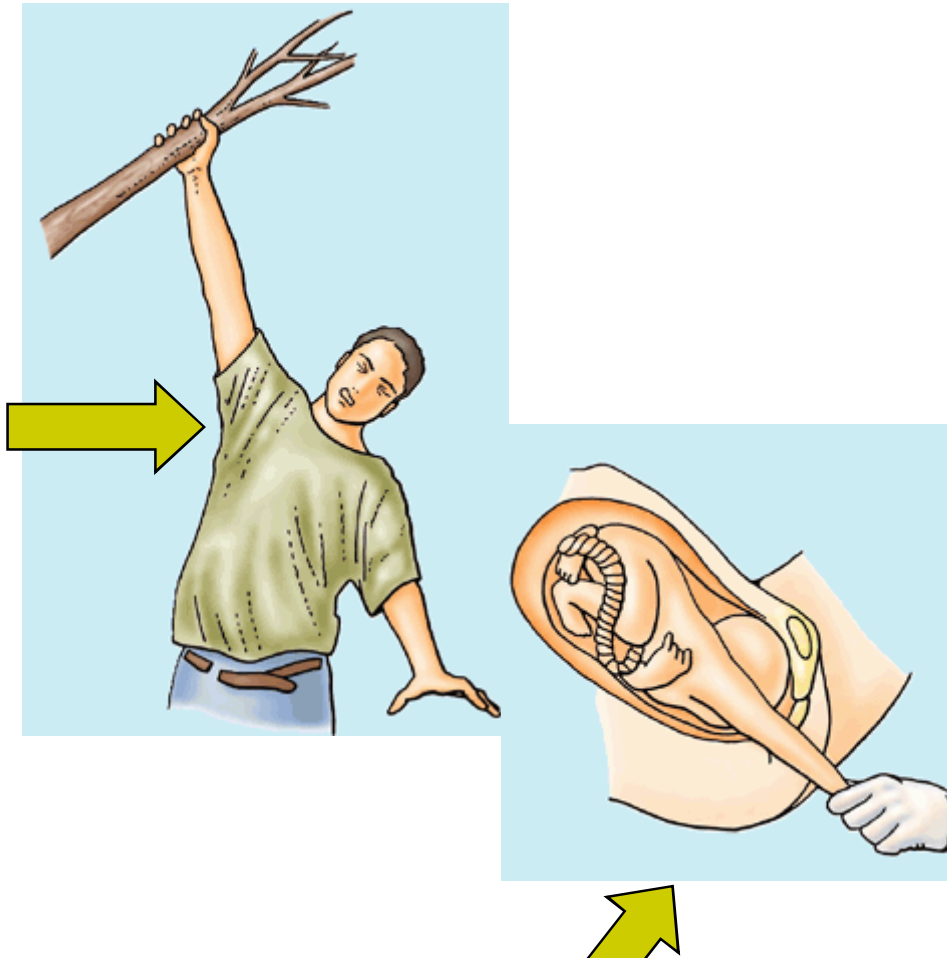
- Injury of upper roots and trunk
- Usually results from excessive **increase in the angle** between the neck and the shoulder stretching or tearing of the superior parts of the brachial plexus (**C5** and **C6** roots or **superior trunk**)
- May occur as **birth injury** from forceful pulling on infant's head during difficult delivery

Upper Brachial Palsy (Erb-Duchenne palsy)



- In all cases, paralysis of the muscles of the shoulder and arm supplied by **C5** and **C6** spinal nerves (roots) of the upper trunk.
- Combination lesions of **axillary**, **suprascapular** and **musculocutaneous** nerves with loss of the shoulder mm and anterior arm.
- As result patient have “**waiter’s tip**” hand:
 - **adducted** shoulder
 - **medially rotated** arm
 - **extended** elbow
 - loss of sensation in the **lateral aspect** of the upper limb

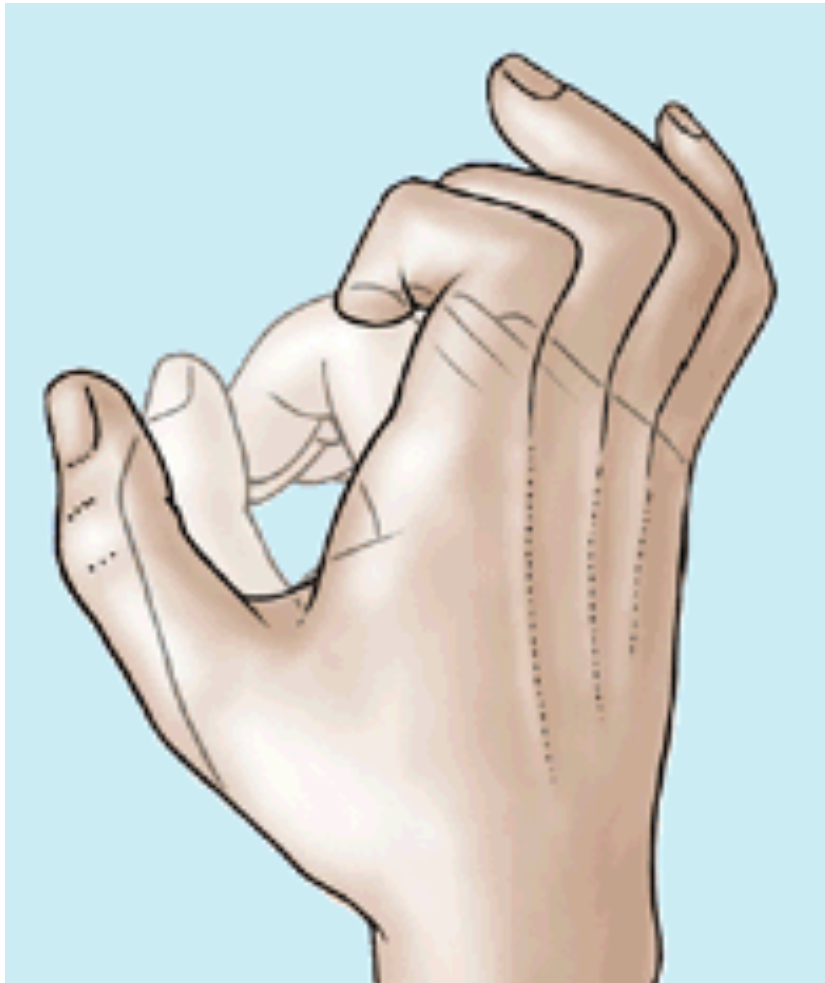Lower Brachial Palsy (Klumpke paralysis)



- Injury of lower roots and trunk
- May occur when the upper limb is suddenly **pulled superiorly**: stretching or tearing of the inferior parts of the brachial plexus (**C8** and **T1** roots or **inferior trunk**)
- E.g., **grabbing** support during **fall from height** or as a **birth injury**, or **TOS** – thoracic outlet syndrome

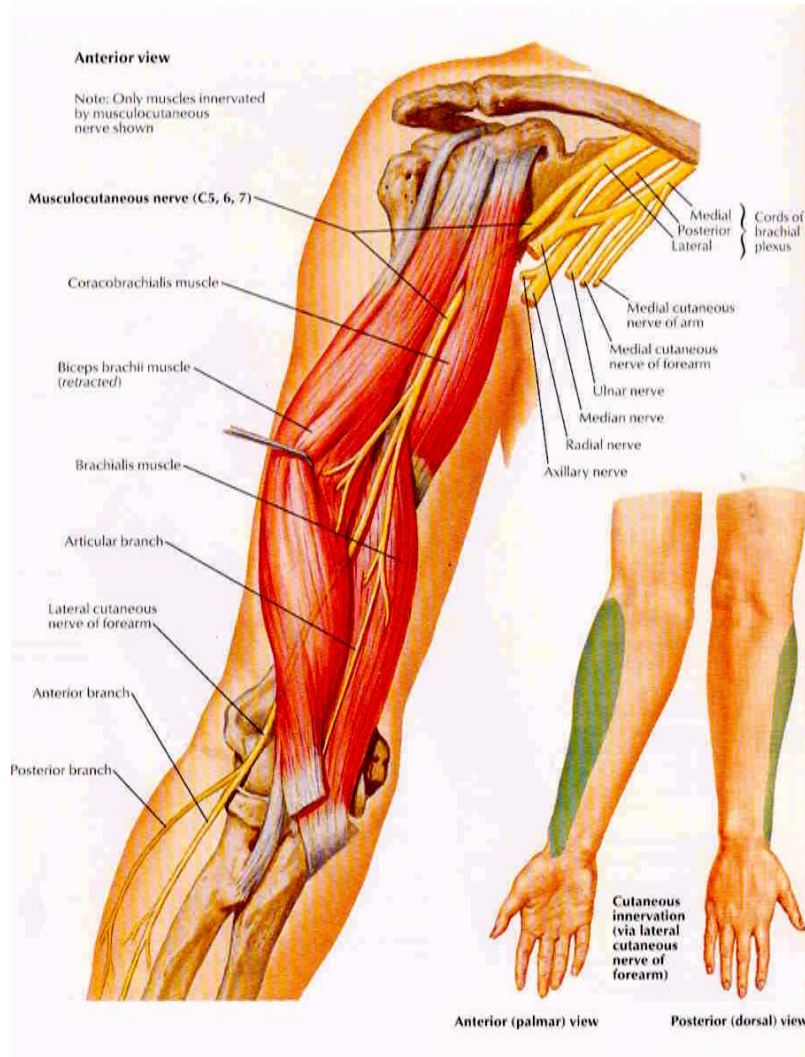
Im not sure exactly how its asked: But know that C8/T1 is lower brachial plexus injury and know its dermatomes in the arm and also know that dermatome of the thumb and index finger are C6....i think the qestion was something about a hand injury with sensory loss "in the space between the thumb and index finger", so know C6 also know the nerve here is median n.

Lower Brachial Palsy (Klumpke paralysis)



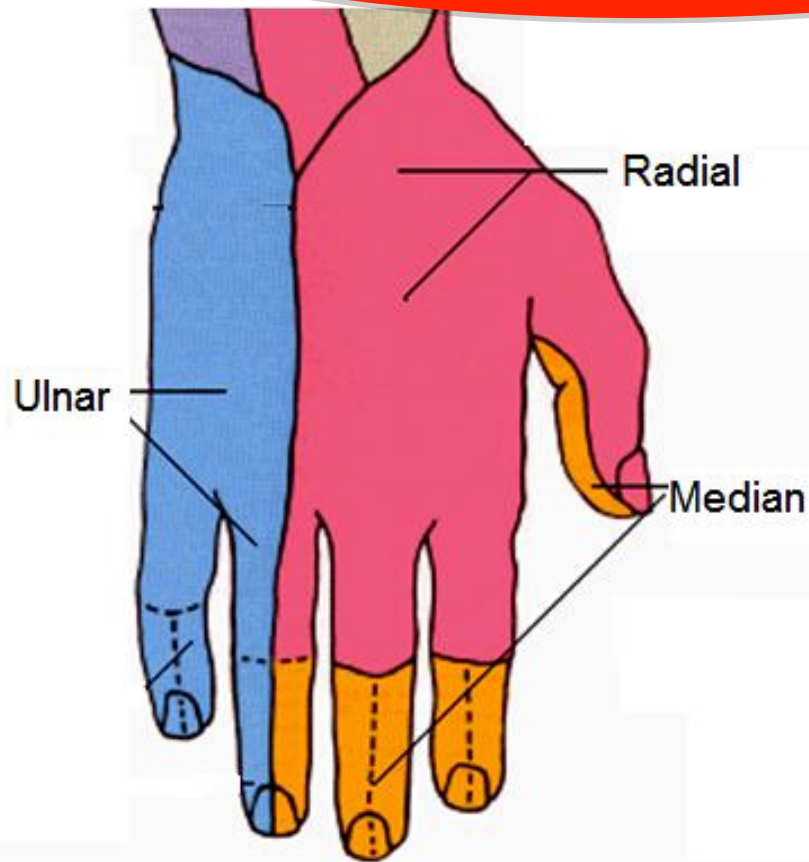
- All **intrinsic muscles** of the **hand** supplied by the **C8** and **T1** roots of the **lower trunk** affected.
- Combination lesions of **ulnar** nerve (“**claw hand**”) and **median** nerve (“**ape hand**”)
- Loss of sensation in the **medial aspect** of the upper limb and medial 1,5 fingers.
- May include a **Horner** syndrome

Injury to musculocutaneous nerve

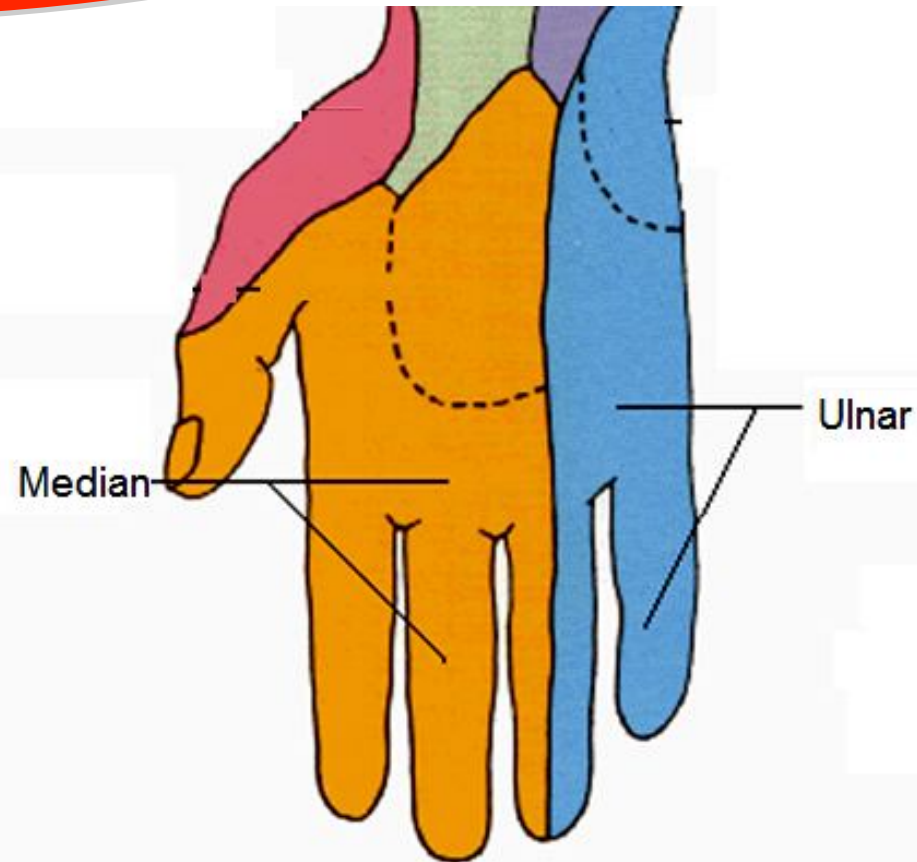


- Usually results from **lesions of lateral cord**
- Greatly weakens **flexion of elbow** (biceps and brachialis muscles) and **supination of forearm** (biceps muscle)
- May be accompanied by **anesthesia over lateral aspect of forearm**

Cutaneous innervation of the hand

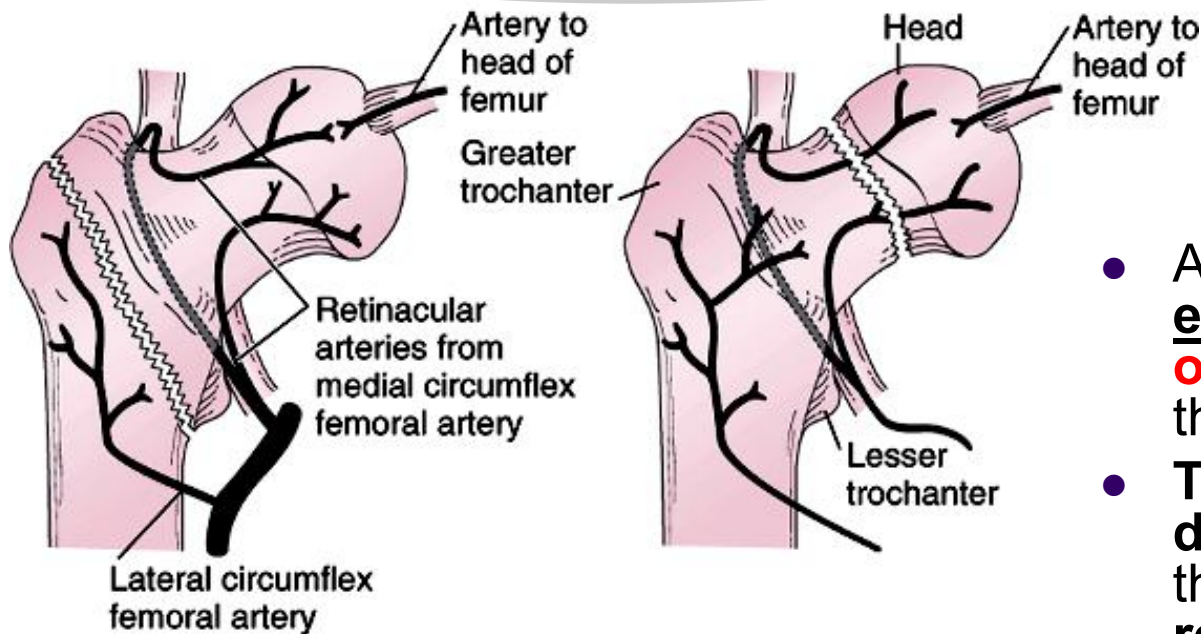


Dorsum: 1,5-U and 3,5 R



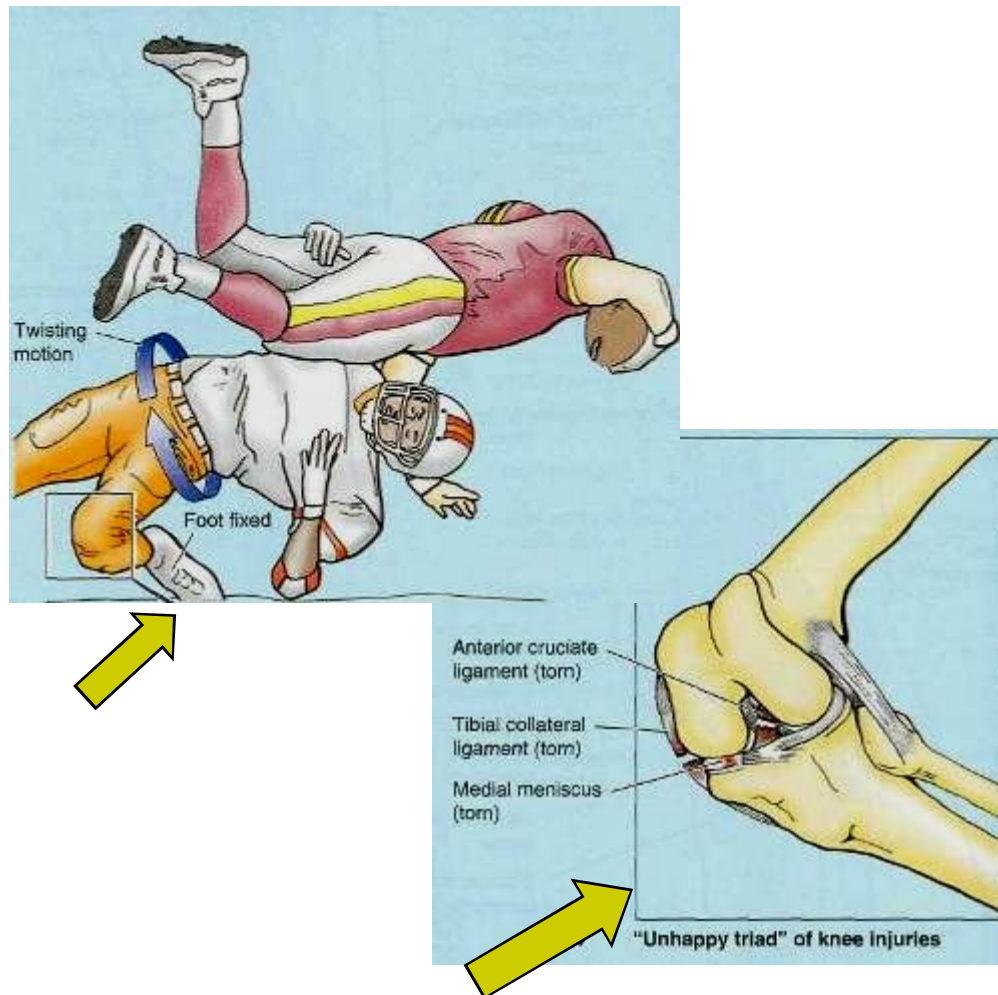
Palm: 1,5-U and 3,5 M

13. Avascular necrosis of femoral head



- A common fracture in **elderly women** with **osteoporosis** is fracture of the **femoral neck**.
- **Transcervical** fracture **disrupts blood supply** to the head of the femur via **retinacular arteries** (from **medial circumflex femoral artery**) and may cause **avascular necrosis** of the **femoral head** if blood supply through the ligament to the head is inadequate.

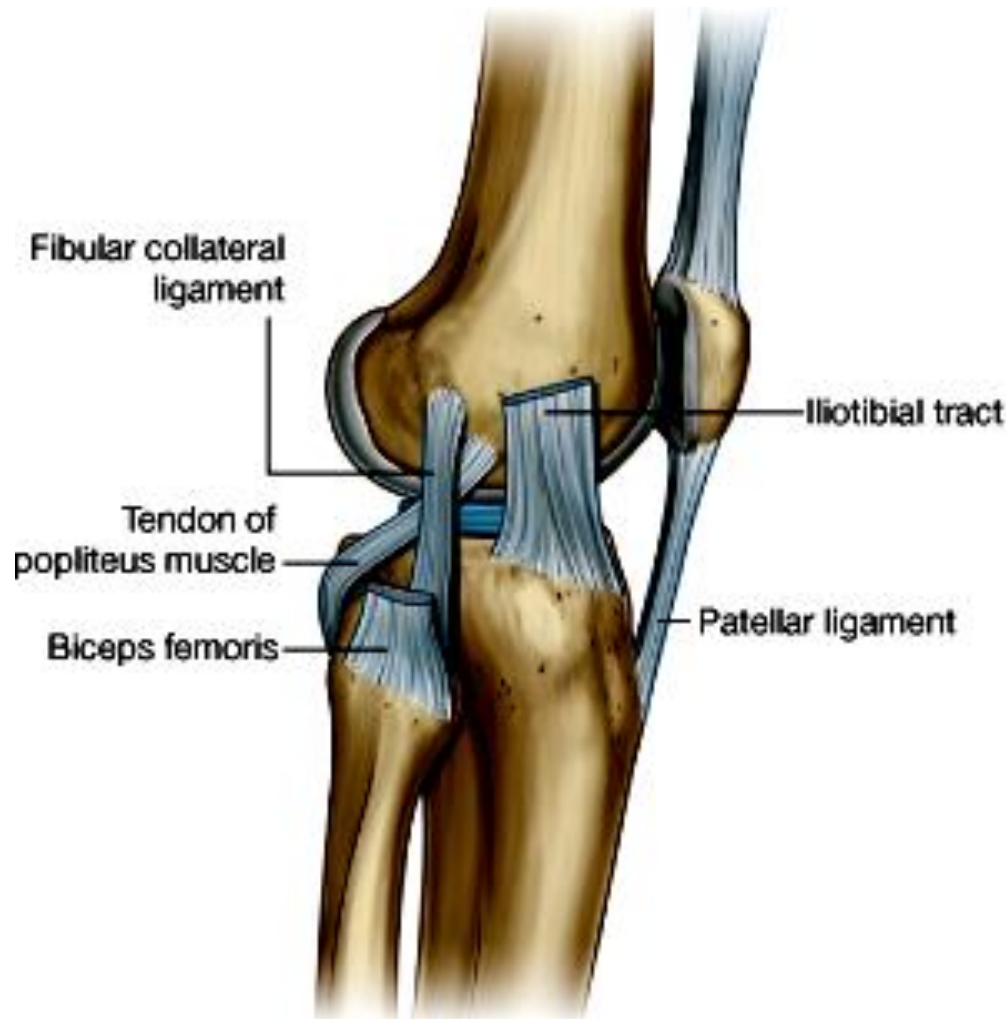
14. Knee joint injury: Unhappy triad



- Because the lateral side of the knee is struck more often (e.g., in a football tackle), the **tibial collateral ligament** is the **most frequently torn** ligament at the knee.
- The **unhappy triad** of athletic knee injuries involves:

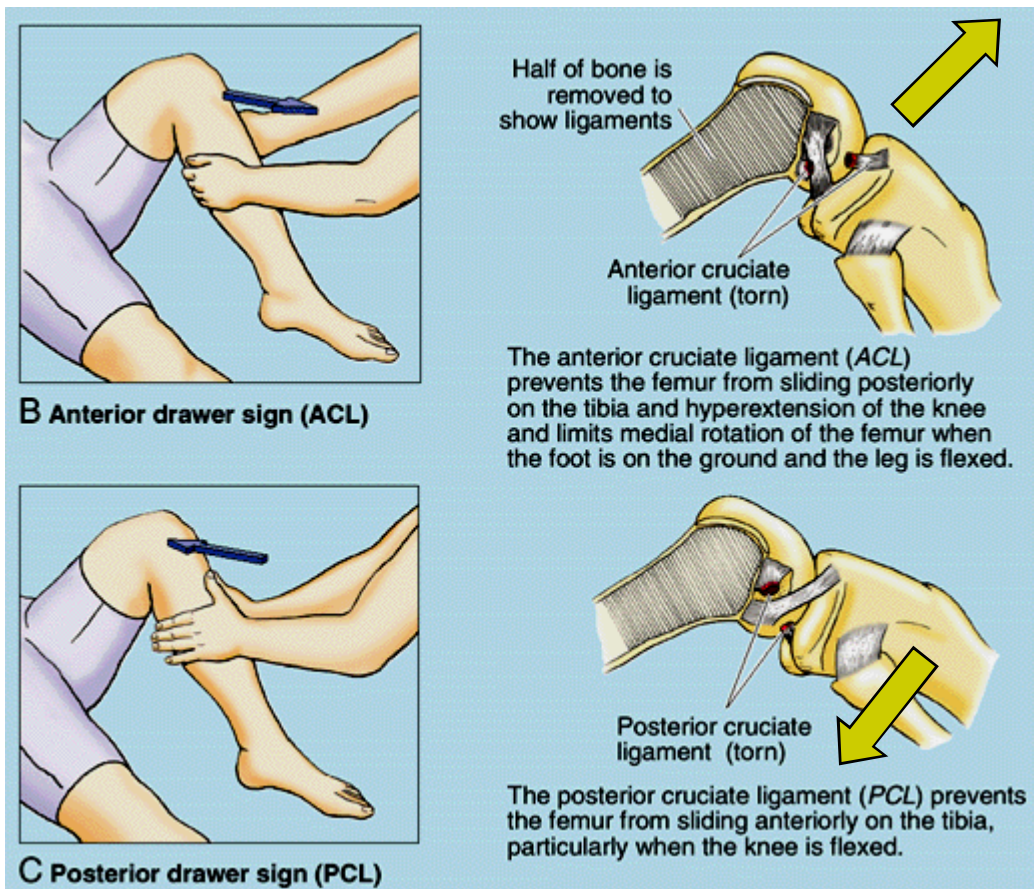
1. **Tibial collateral ligament** **medial**
2. **Medial meniscus**
3. **Anterior cruciate ligament** **MMA**

Fibular collateral ligament (lateral collateral ligament)



- Rounded cord between **lateral epicondyle of femur** and **head of fibula**
- Does **NOT** blend with joint capsule and **does NOT attach to lateral meniscus**
- **Limits** extension and **adduction of leg** at knee

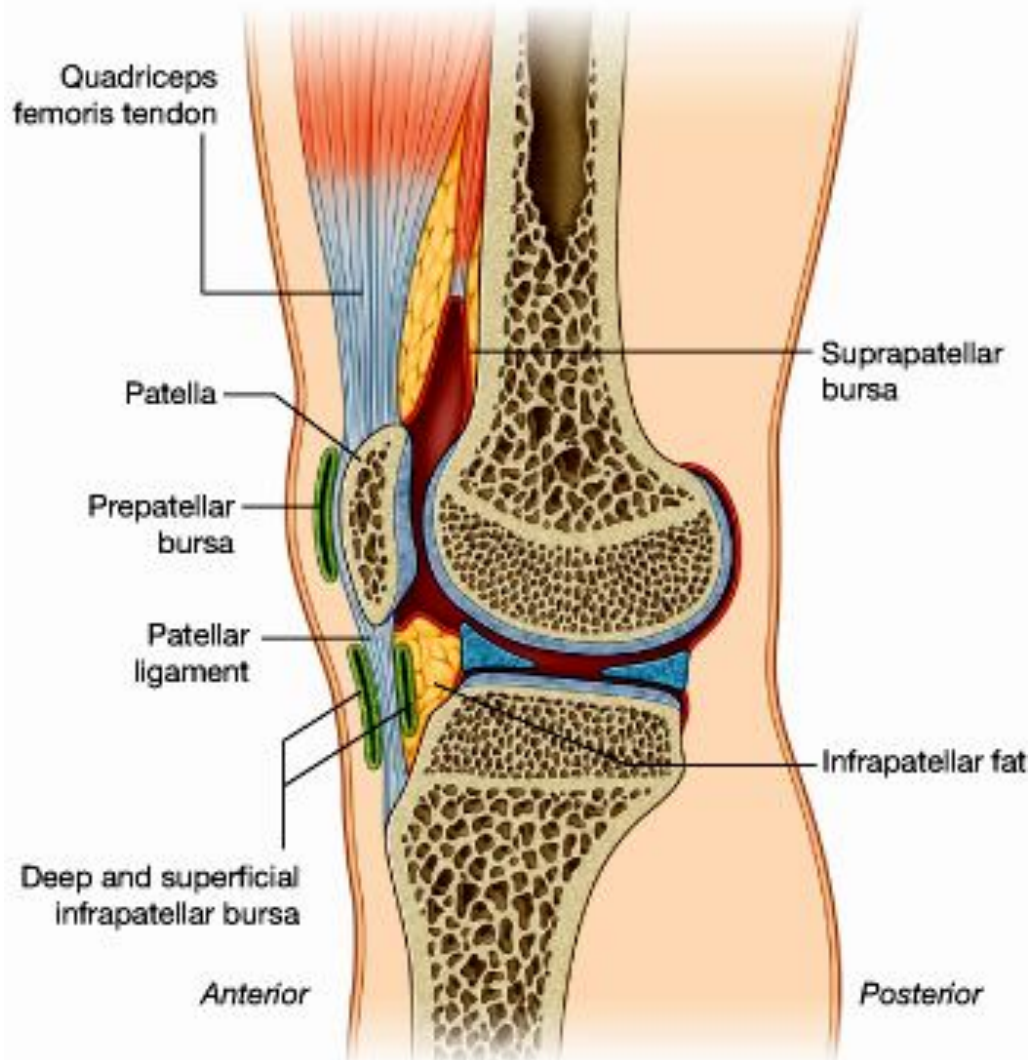
Rupture of the cruciate ligaments



- With **rupture of the anterior cruciate ligament**, the tibia can be pulled forward excessively on the femur, exhibiting **anterior drawer sign**.
- In the less common rupture of the **posterior cruciate ligament**, the tibia can be pulled backward excessively on the femur, exhibiting **posterior drawer sign**.

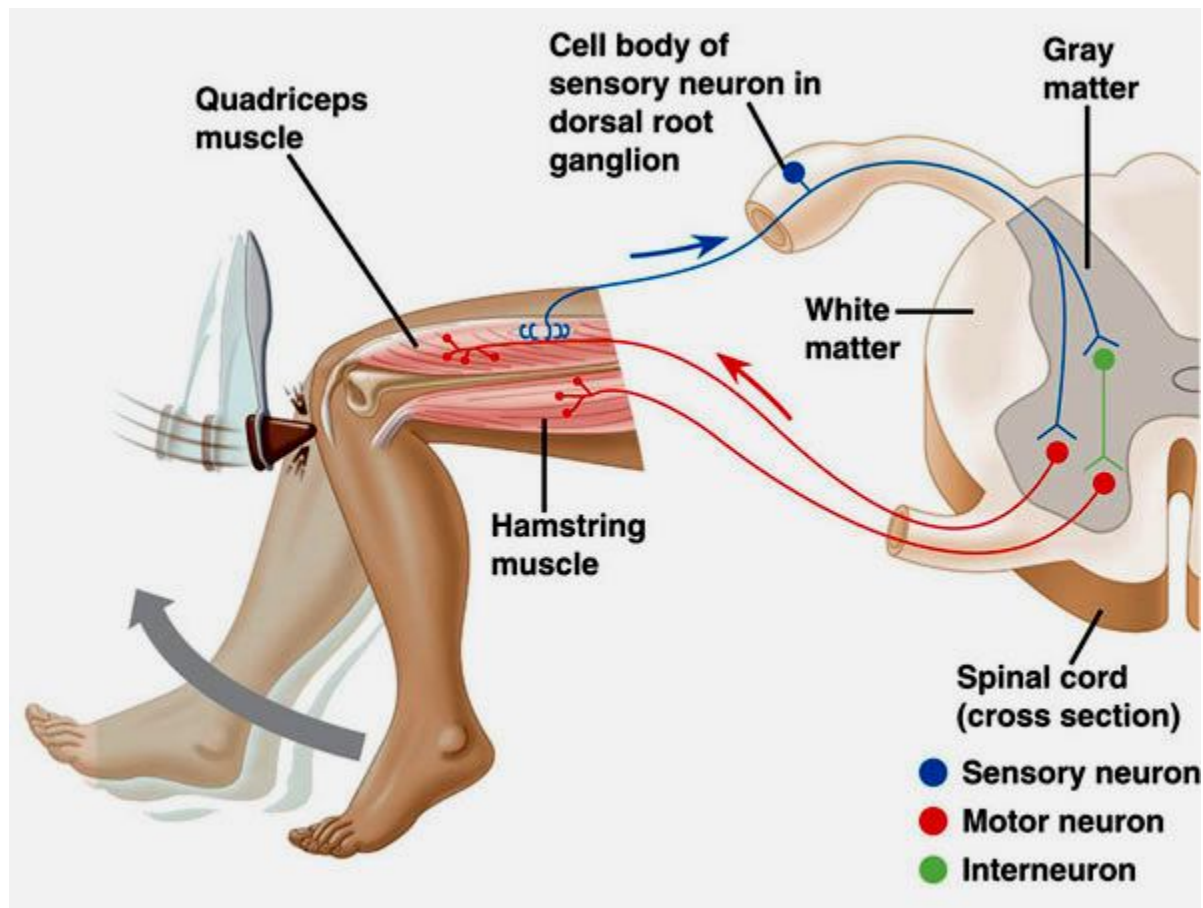
Prepatellar bursa

Suprapatellar bursa



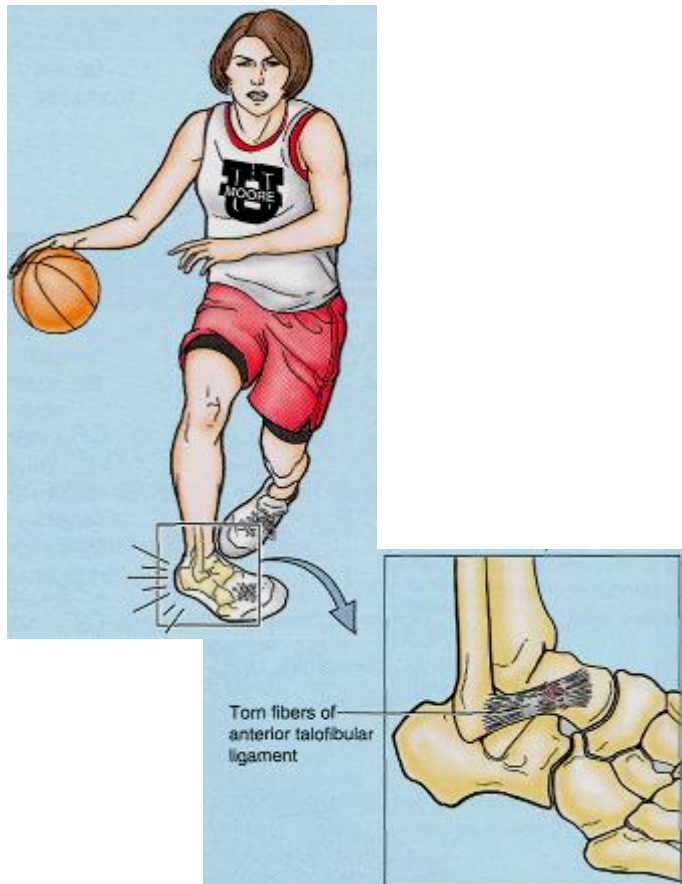
- **Prepatellar bursa:** between superficial surface of patella and skin. May become inflamed and swollen (**prepatellar bursitis**)
- **Suprapatellar bursa:** superior extension of synovial cavity between distal end of **femur** and **quadriceps** muscle and tendon. **Usual** place for **intra-articular injections**


Knee jerk reflex



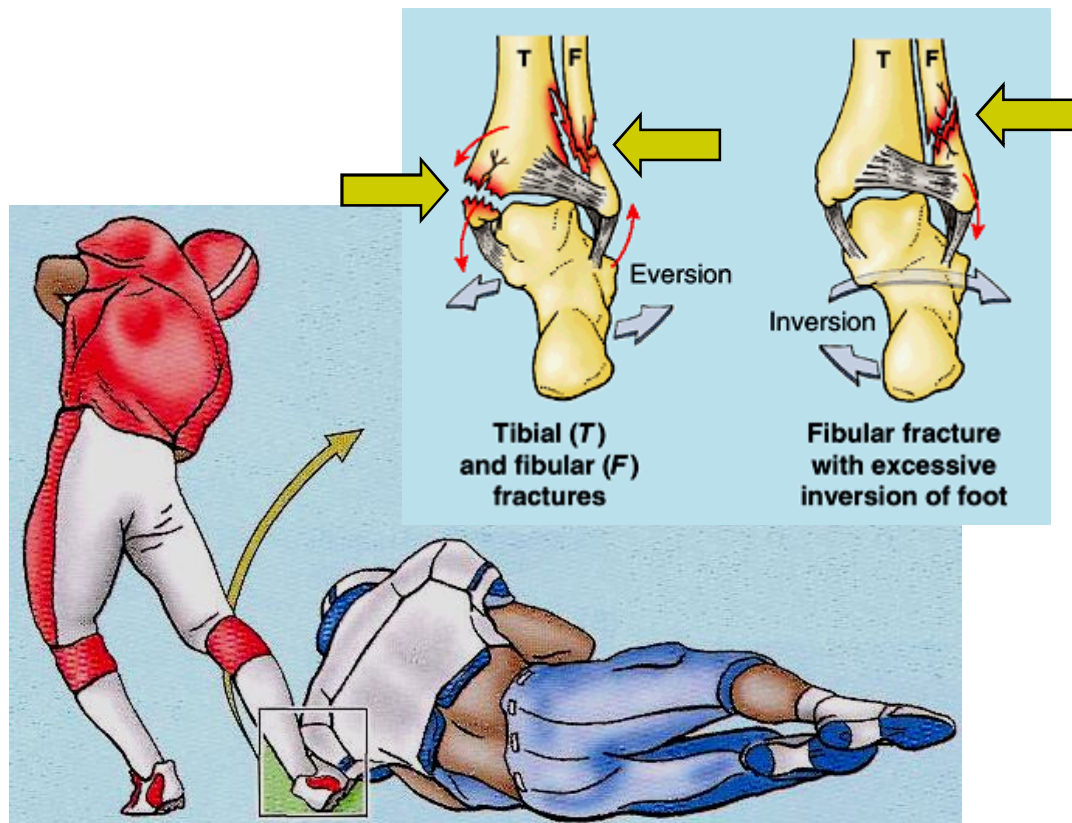
- The **patellar reflex** is tested by tapping the patellar ligament with a reflex hammer to elicit extension at the knee joint. Both afferent and efferent limbs of the reflex arch **are** in the **femoral nerve (L2-L4)**.
- **Knee jerk reflex:** tests spinal nerves **L2-L4**.

15. Ankle joint injury: Ankle sprains



- **Sprains** are the **most common** ankle injuries
- A sprained ankle is nearly always an **inversion injury**, involving twisting of the weight-bearing **plantarflexed** foot. 
- The **lateral ligament** (**anterior talofibular ligament**) is injured because it is much weaker than the medial ligament.
- In severe sprains, the **lateral malleolus** of the fibula may be **fractured**.

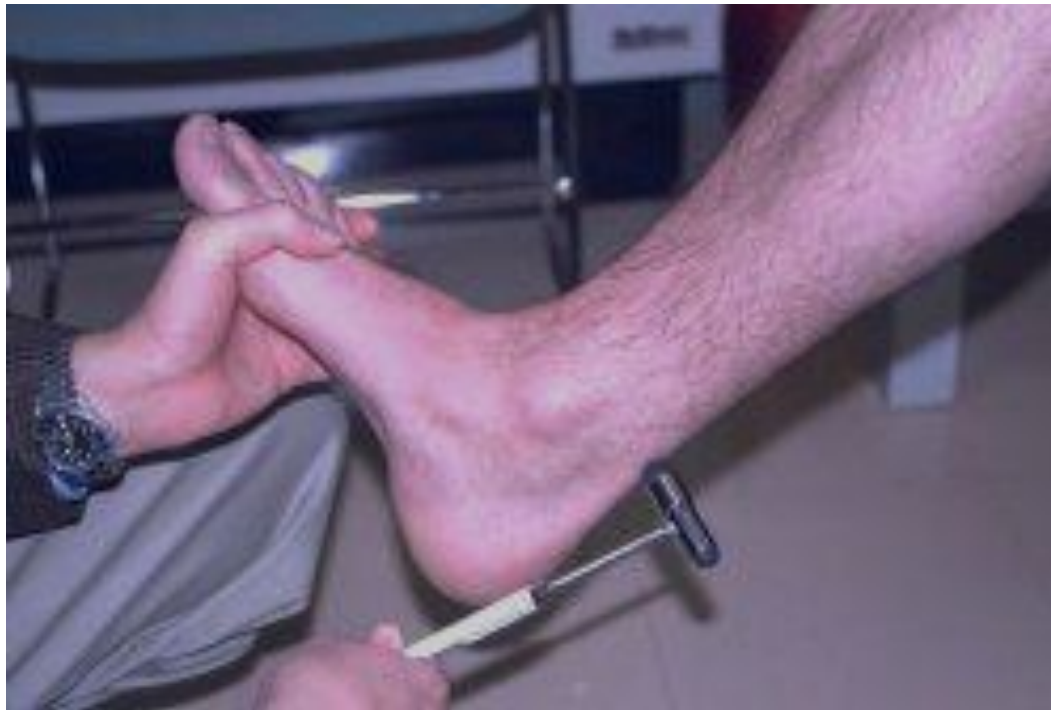Pott's fracture



Pott's fracture

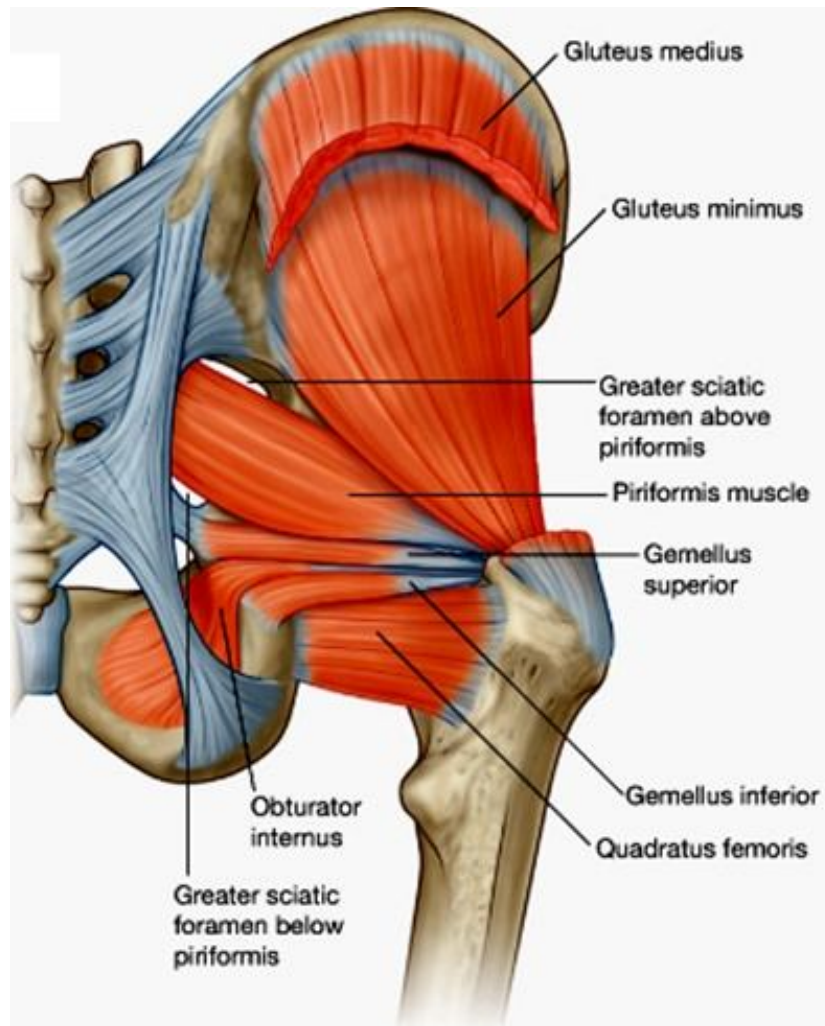
- Fracture-dislocations of the ankle (**Pott's fracture**):
 - Forced **eversion** (**abduction**) of the foot
 - The medial ligament avulses the **medial malleolus** or the **medial ligament tears**, and **fibula fractures** at a higher level
- Forced **inversion** (**adduction**) avulses the **lateral malleolus** of fibula or tears the **lateral ligament**

Ankle jerk reflex

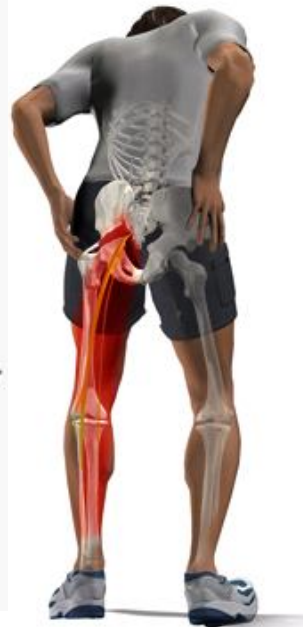

- **Achilles tendon reflex** is tested by **tapping** the **calcaneal tendon** to elicit plantar flexion at the ankle joint.
- Both afferent and efferent limbs of the reflex arc are carried in the **tibial nerve** (S1, S2).
- **Ankle jerk reflex:** tests spinal nerves **S1-S2**.

16. Injury of the gluteal region: Piriformis syndrome

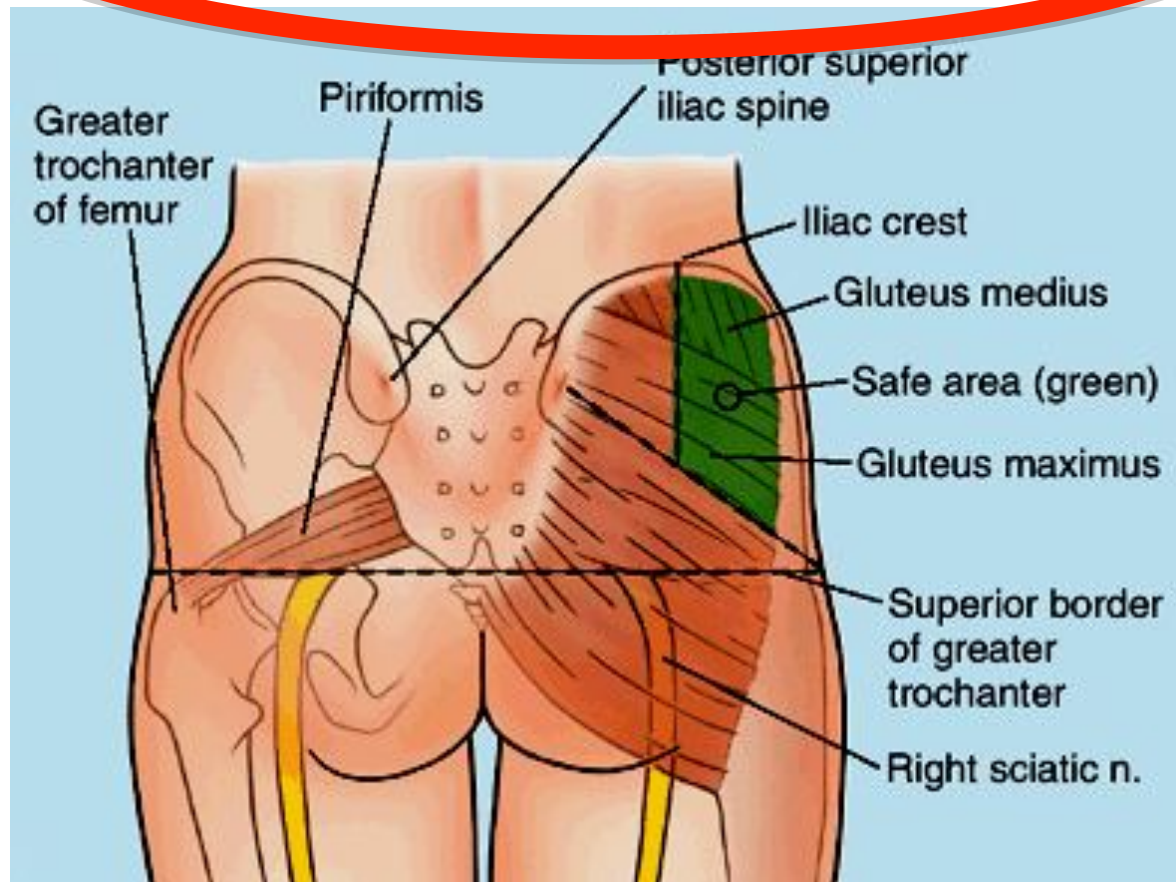


- **Inflammation or spasm of the piriformis muscle** may produce pain similar to that caused by **sciatica** ("piriformis syndrome").



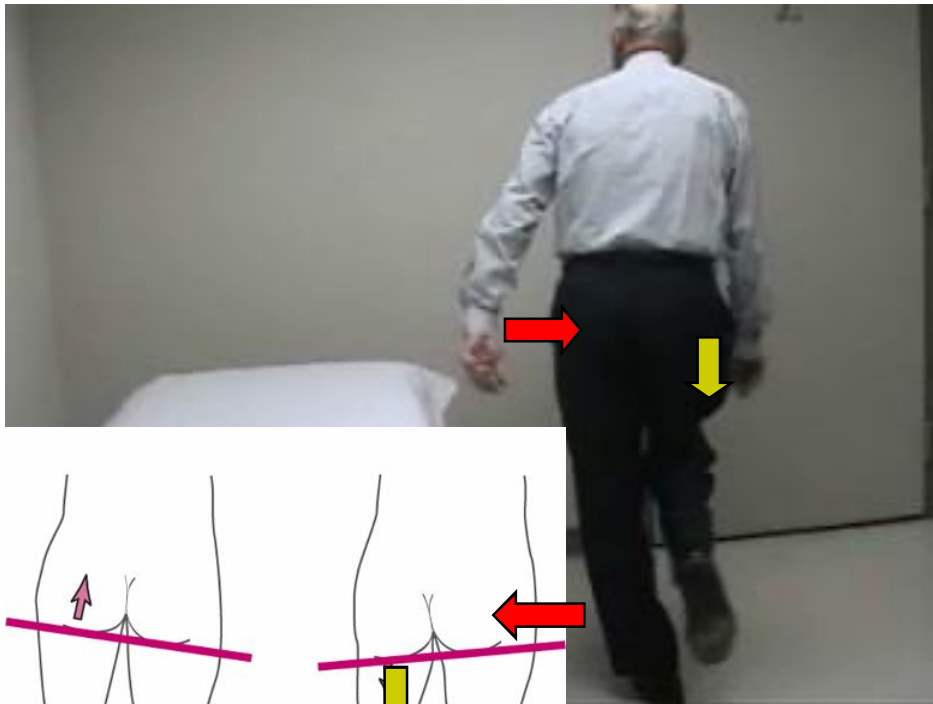
- Piriformis “Landmark”** of the **gluteal region**: provides key to understanding relationships in the gluteal region; determines names of blood vessels and nerves
- action: **supination** of hip joint

Injury to sciatic nerve



- **Weakened hip extension and knee flexion**
- **Footdrop** (lack of dorsiflexion)
- **Flail foot** (lack of both dorsiflexion and plantar flexion)
- **Cause of injury:** caused by **improperly placed gluteal injections** but may result from posterior hip dislocation

Superior gluteal nerve injury



Superior gluteal nerve injury

- The superior gluteal nerve may be injured during surgery, **posterior dislocation** of the hip or poliomyelitis.
- **Paralysis** of the **gluteus medius** and **gluteus minimus** muscles occurs so that the **ability to pull the pelvis up and abduction of the thigh** are lost.
- If the **superior gluteal** nerve on the **left** side is injured, the **right pelvis falls downward** when the patient raises the right foot off the ground.
- Note that it is the side **contralateral** to the nerve injury that is affected.

Injury to inferior gluteal nerve



- Weakened **hip extension** (gluteus maximus), most noticeable when **climbing stairs** or **standing from a seated position**
- **Cause of injury:** posterior hip dislocation, surgery in this region



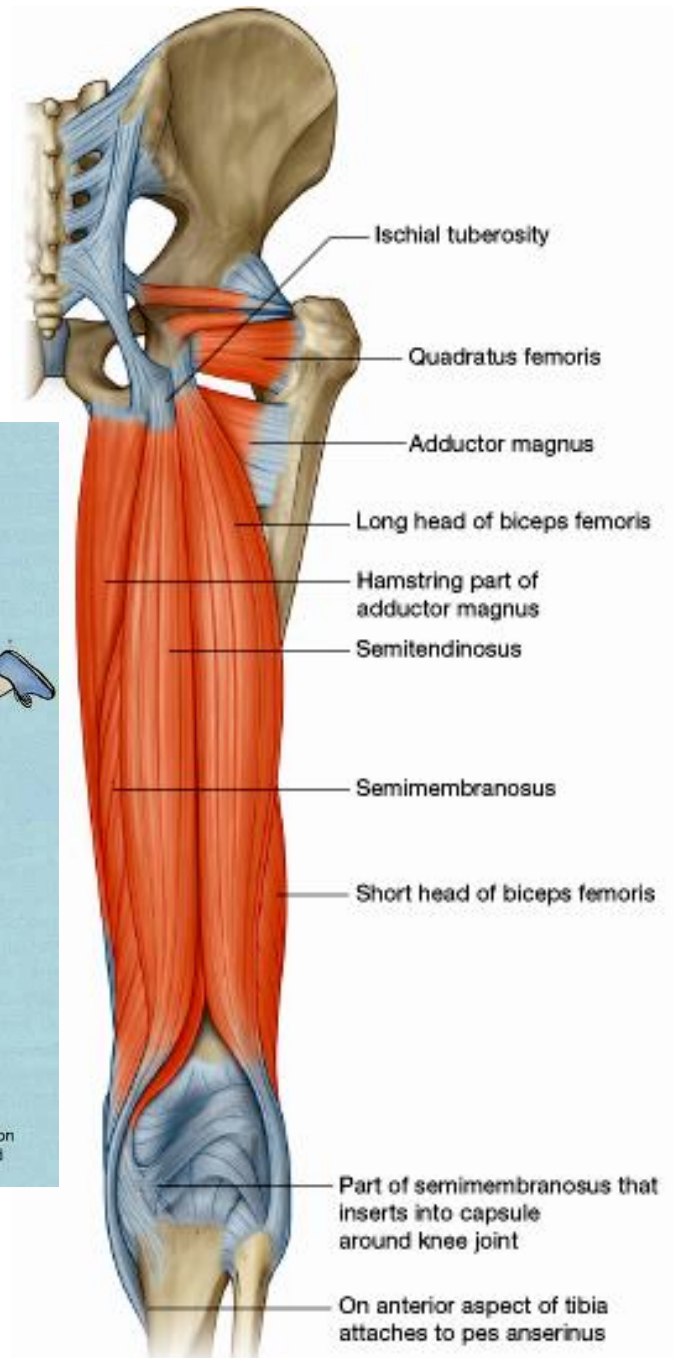
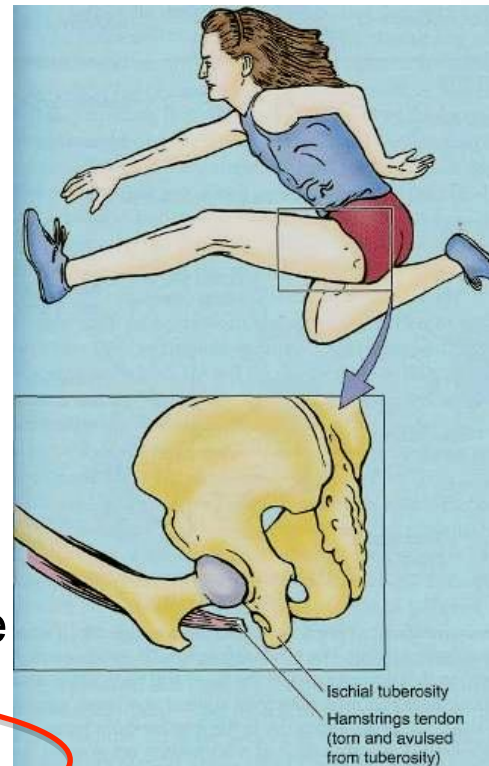
17. Avulsion fractures of the hip bone and hamstrings muscles

- Avulsion fractures occur **where muscles are attached - ischial tuberosities**

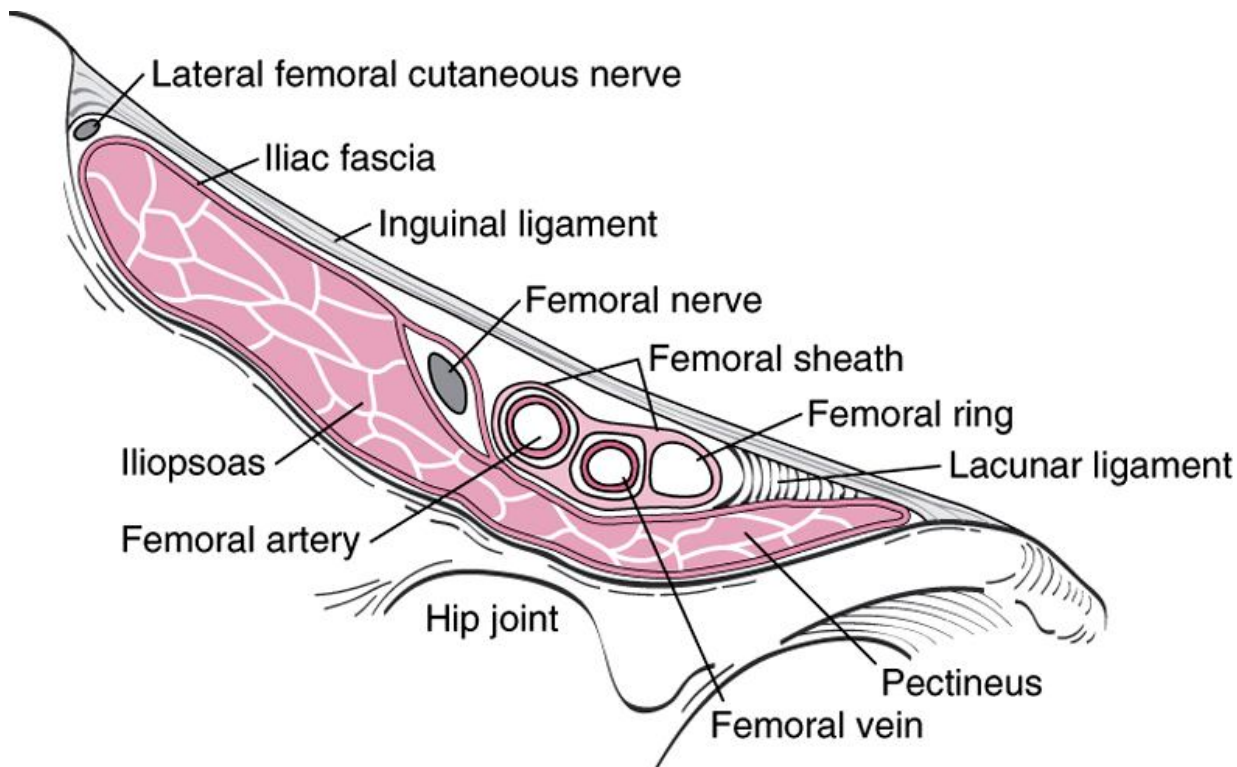
Hamstrings muscles:

1. **Biceps femoris**
2. **Semitendinosus**
3. **Semimembranosus**

- Action: **extension** of hip joint and **flexion** of knee joint
- Nerve supply – **Tibial nerve** (short head of biceps femoris is supplied by the **common fibular nerve**)



18. Femoral sheath & femoral hernia

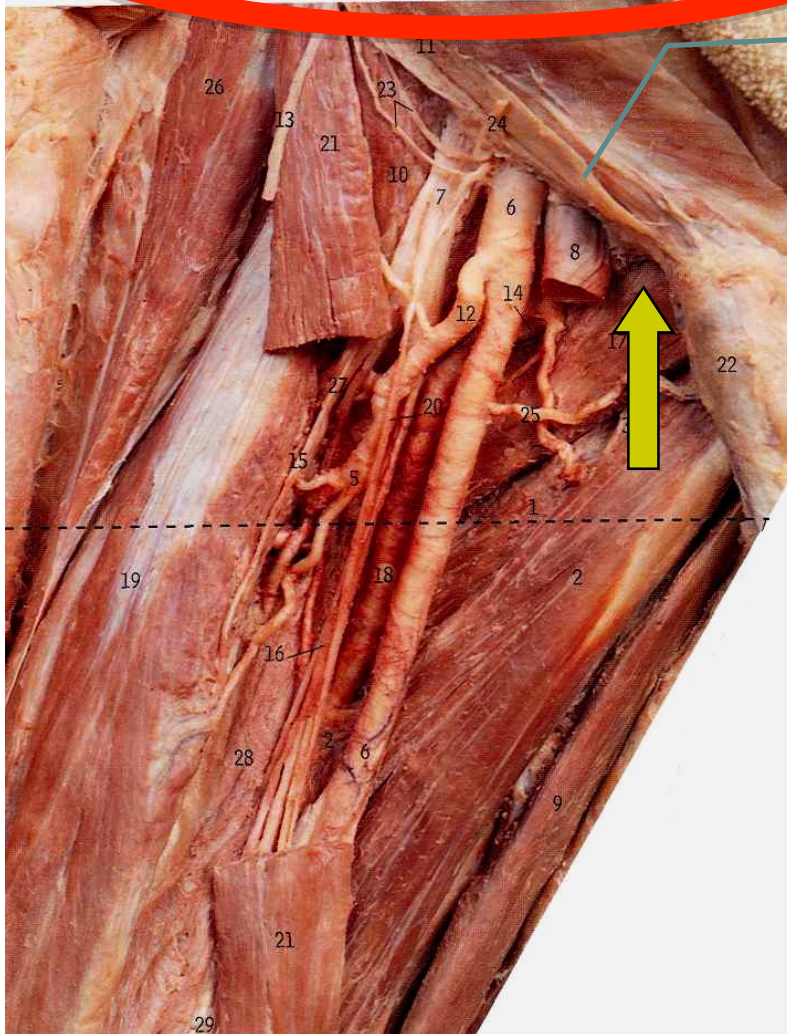


- Extension of **transversalis fascia** and **iliacus fascia** that enters thigh deep to inguinal ligament
- Divided into three compartments from lateral to medial enclosing:
 - **Femoral artery**
 - **Femoral vein**
 - **Femoral canal**

Femoral hernia

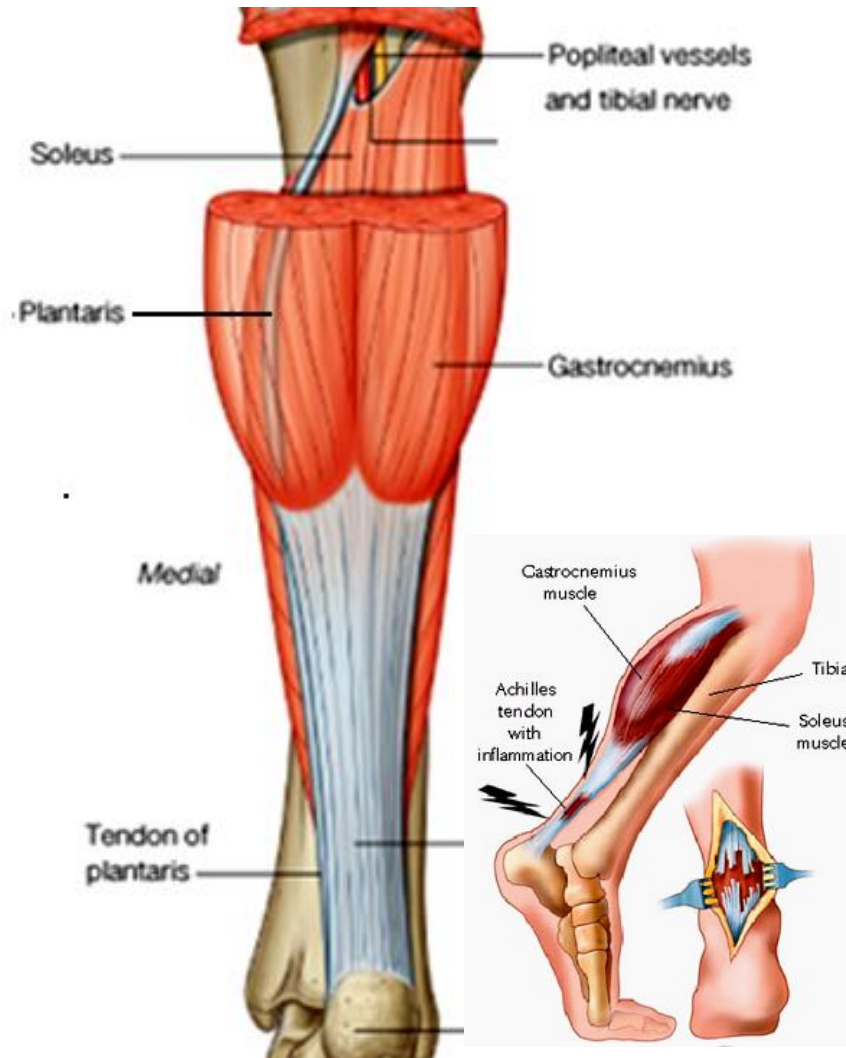


Inguinal lig.



- A **femoral hernia** passes through the **femoral ring** into the femoral canal to form a swelling in the upper thigh inferior and lateral to the pubic tubercle
- The hernial sac may protrude through the **saphenous hiatus** into the superficial fascia
- A femoral hernia occurs more frequently **in females** and is dangerous because the hernial sac may become **strangulated**
- An **aberrant obturator artery** is vulnerable during surgical repair

19. Rupture of the Achilles tendon and Triceps surae muscle

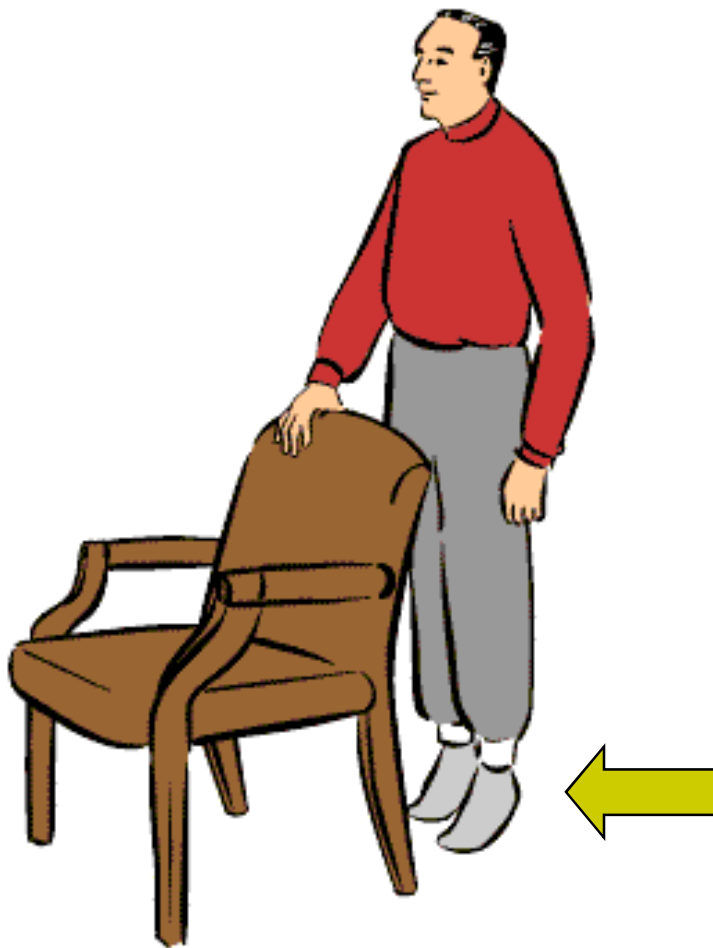


- **Avulsion or rupture of the calcaneal (Achilles) tendon** disables the triceps surae muscle (gastrocnemius & soleus) so that the patient cannot **plantar flex** the foot.

Triceps surae muscle:

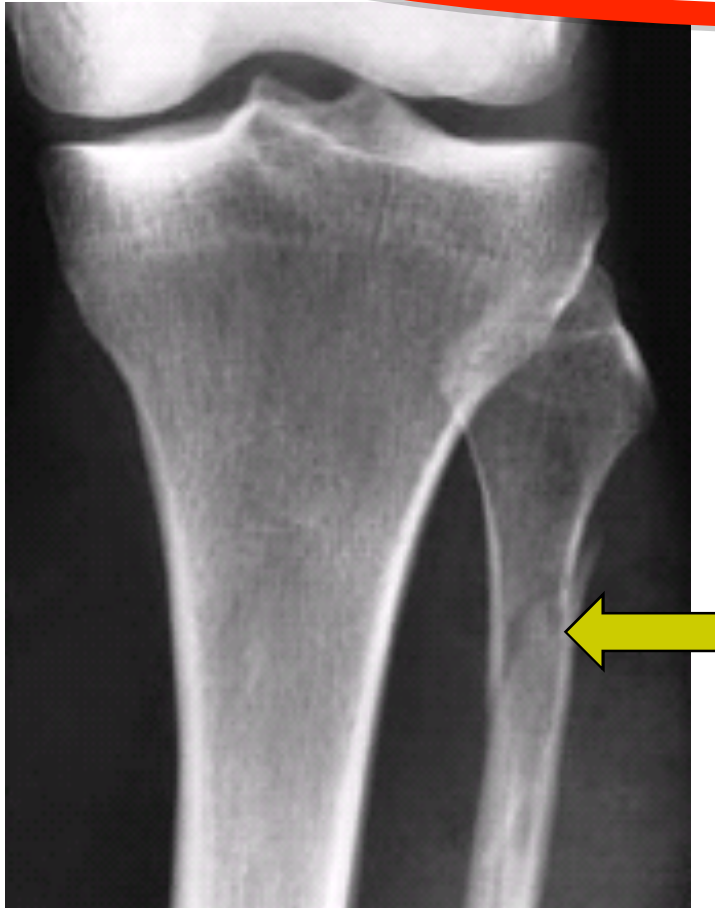- 2 Heads of **Gastrocnemius** m.
- 1 Head - **Soleus** muscle
- **Plantaris**
 - small fusiform belly with long thin tendon; **may be absent**
 - sometimes may become **hypertrophy**

Injury to tibial nerve

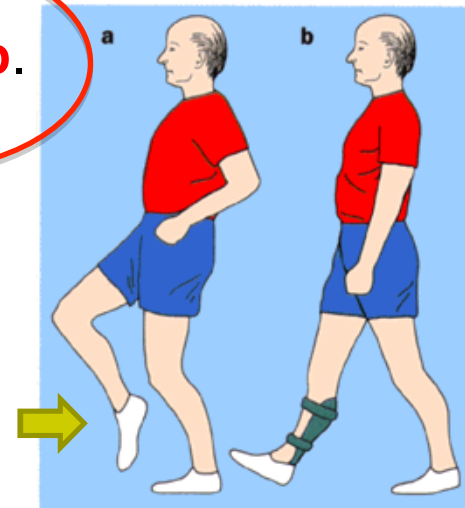


- In popliteal fossa: **loss of plantar flexion** of foot (mainly **gastrocnemius** and soleus muscles) and **weakened inversion** (tibialis posterior muscle), causing **calcaneovalgus**.
- **Inability to stand on toes**

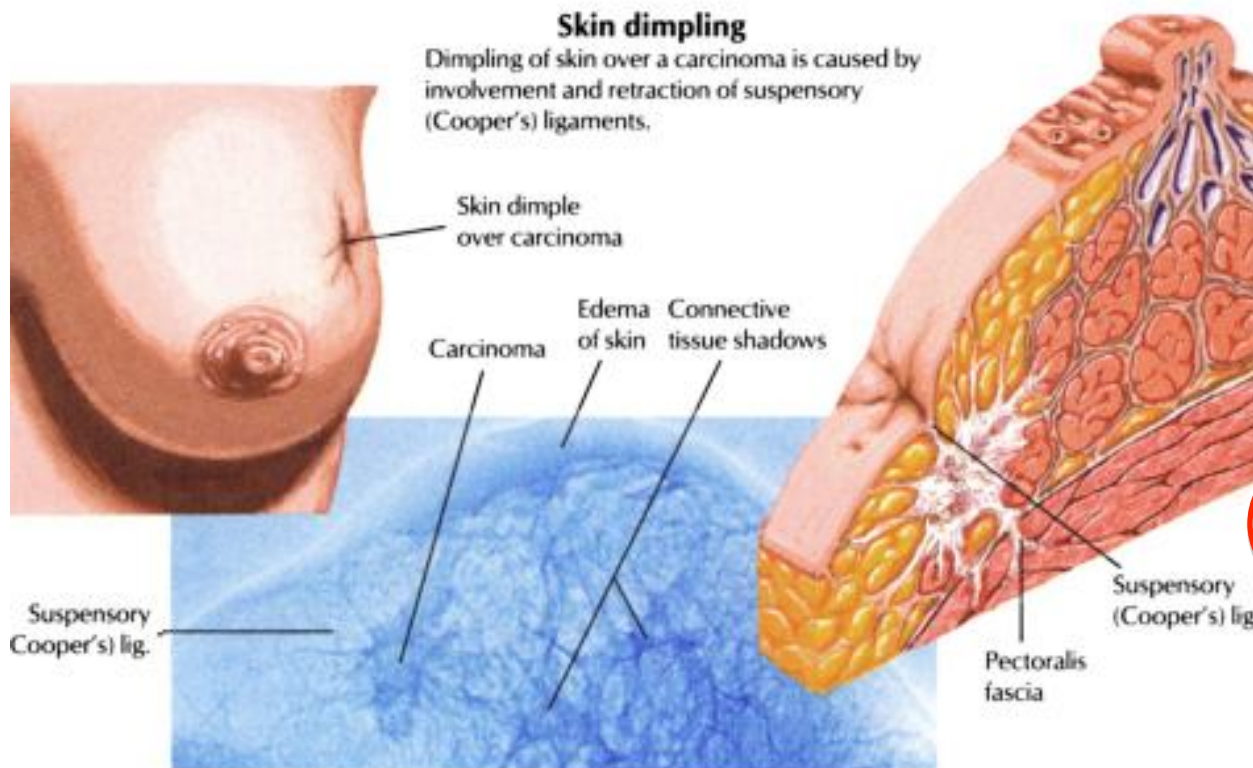
20 Fracture of the fibular neck



- May cause an injury to the **common peroneal nerve**, which winds laterally around the neck of the fibula.
- This injury results in **paralysis** of all muscles in the **anterior** and **lateral compartments** of the leg (dorsiflexors and evertors of the foot)
- Causing **foot drop**.

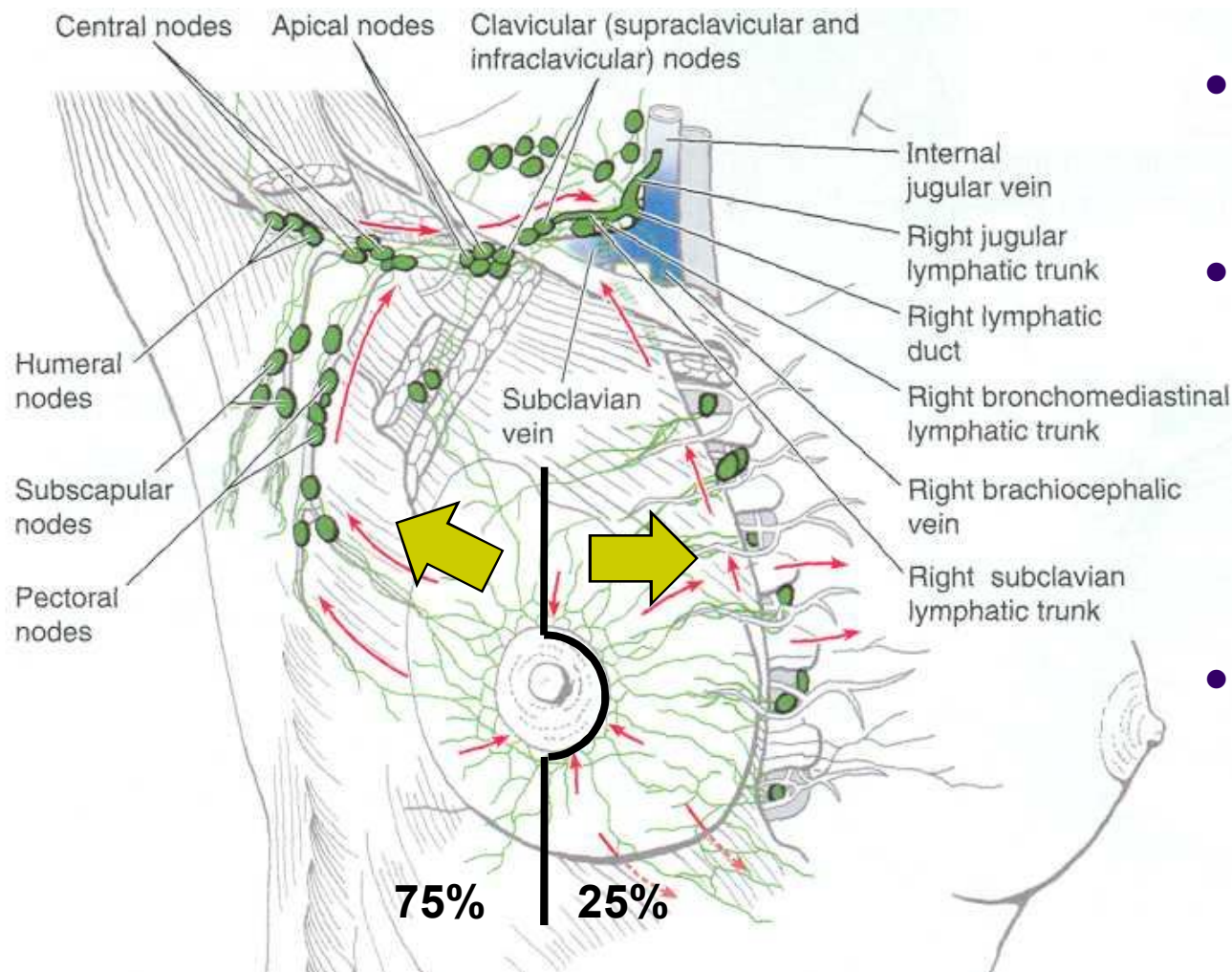


21. Breast: Carcinoma of the Breast



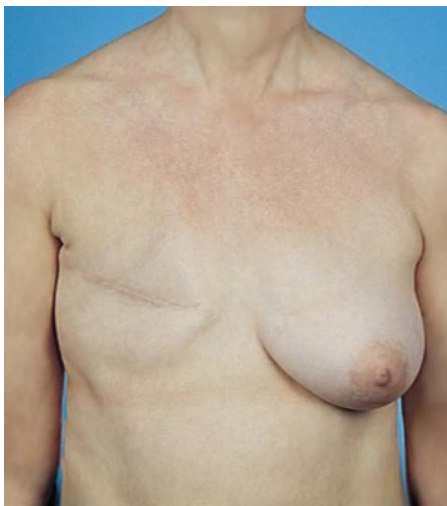- Carcinomas of the breast are **malignant tumors**, usually adenocarcinomas arising from the epithelial cells of the lactiferous ducts in the mammary gland lobules
- 1. It enlarges, attaches to **suspensory (Cooper's) ligaments**, and produces shortening of the ligaments, causing depression or **dimpling** of the overlying **skin**.

Lymphatic drainage of the breast



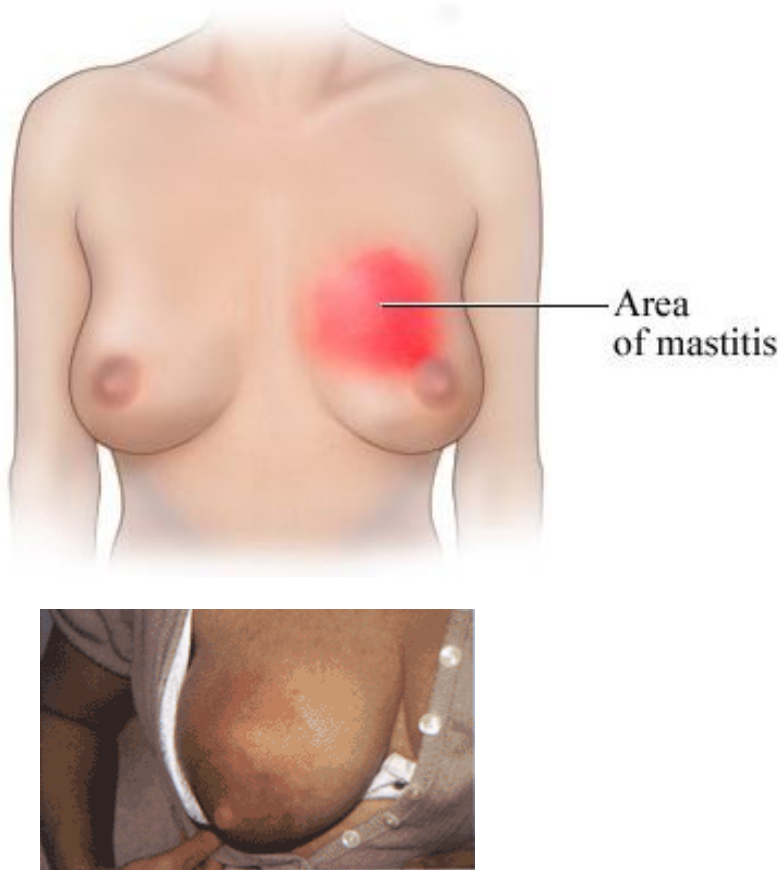
- It is important because of its role in the **metastasis of cancer cells**.
- Most lymph (> 75%), especially from the **lateral breast quadrants**, drains to the **axillary lymph** nodes, initially to the **anterior (pectoral) nodes** for the most part.
- Most of the remaining lymph, particularly from the **medial breast** quadrants, drains to the **parasternal lymph** nodes or to the **opposite breast**.

Mastectomy



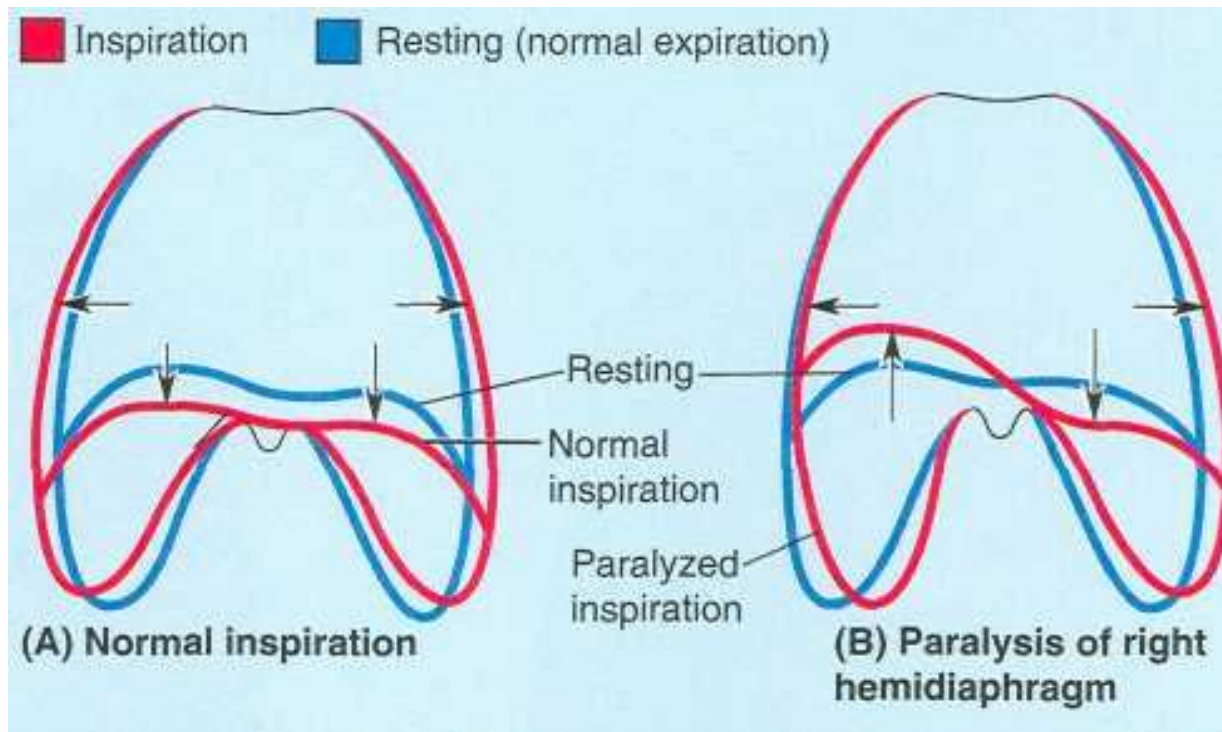
- **Radical mastectomy**, a more extensive surgical procedure, involves removal of the breast, pectoral muscles, fat, fascia, and as many lymph nodes as possible in the axilla and pectoral region.
- During a radical mastectomy, **the long thoracic nerve** may be lesioned during ligation of the lateral thoracic artery. A few weeks after surgery, the female may present with a **winged scapula** and weakness in **abduction** of the arm **above 90°** because **serratus anterior m.** paralysis.
- **The intercostobrachial nerve** may also be damaged during mastectomy, resulting in numbness of the **skin of the medial arm**.

Breast infection



- **Mastitis** is an **infection of the tissue** of the breast that occurs most frequently during the time of **breastfeeding** (1 to 3 months after the delivery of a baby).
- This infection causes **pain, swelling, redness**, and **increased temperature** of the breast.
- It can occur when bacteria, often from the baby's mouth, enter a milk duct through a crack in the nipple.
- It can occur in women who have not recently delivered as well as in women after menopause.

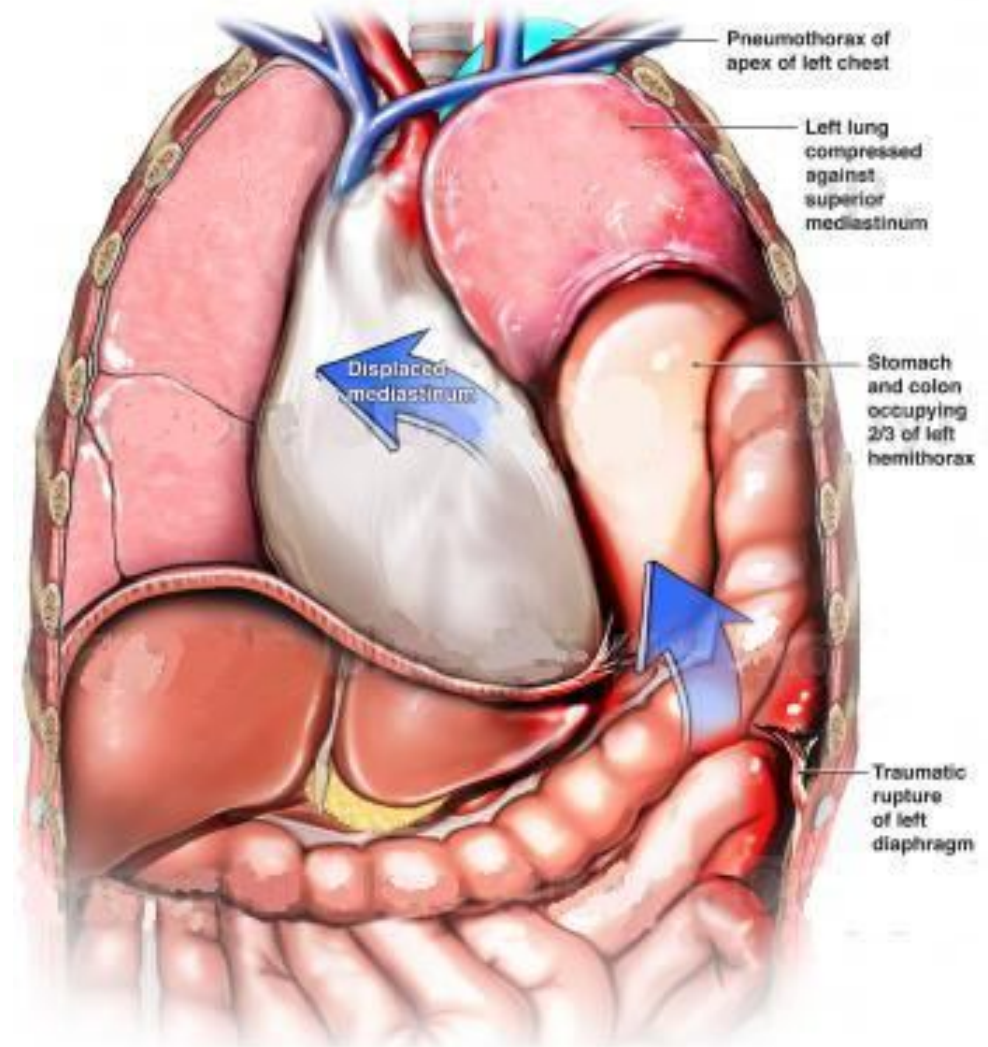
22. Diaphragm: Paralysis of Half and ruptures



- **Paralysis of the half of the Diaphragm** may result from injury or operative division of the **phrenic nerve** of same side
- It can be detected **radiologically**.
- **Paradoxical movement:** dome of diaphragm of injured side pushed superiorly by abdominal viscera during inspiration instead of descending

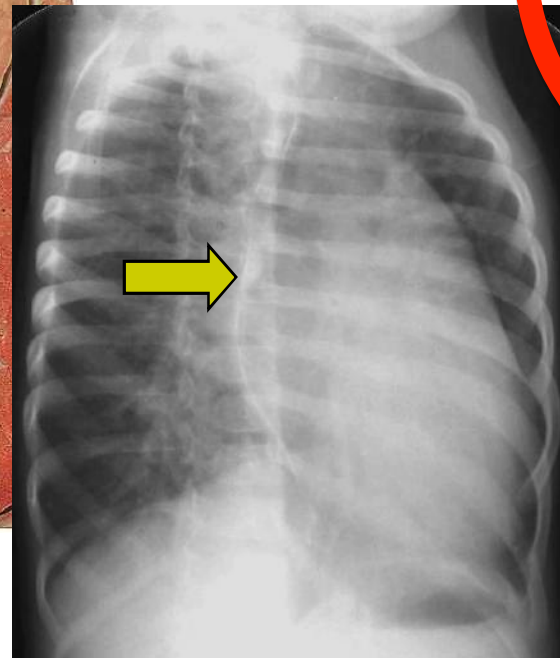
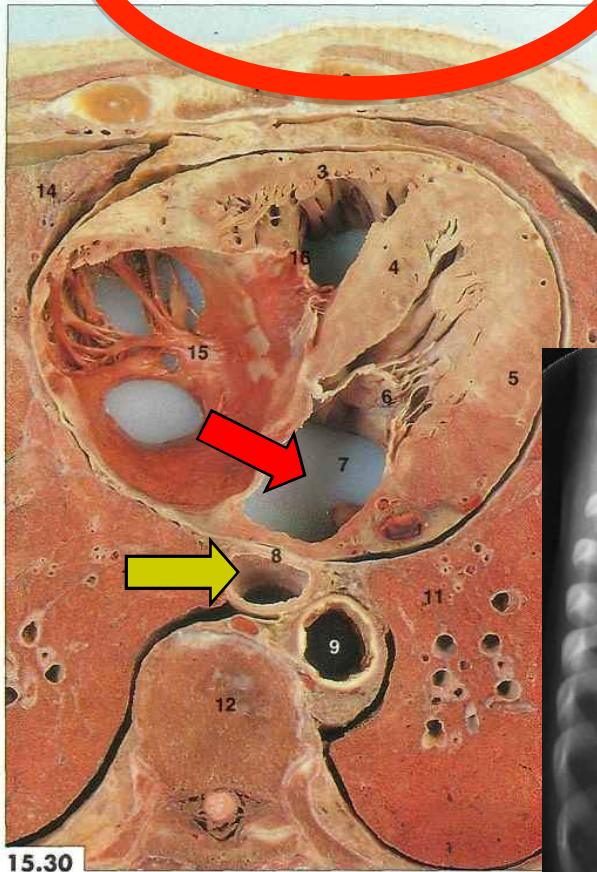
Diaphragmatic ruptures

- Diaphragmatic injuries are relatively rare and result from either **blunt** trauma or **penetrating trauma**.
- Presently, 80-90% of blunt diaphragmatic ruptures **result** from **motor vehicle** crashes.
- The majority (80-90%) of blunt diaphragmatic ruptures have occurred on the **left side**.
- Blunt trauma typically produces large radial tears measuring 5-15 cm, most often at the **posterolateral aspect** of the diaphragm.



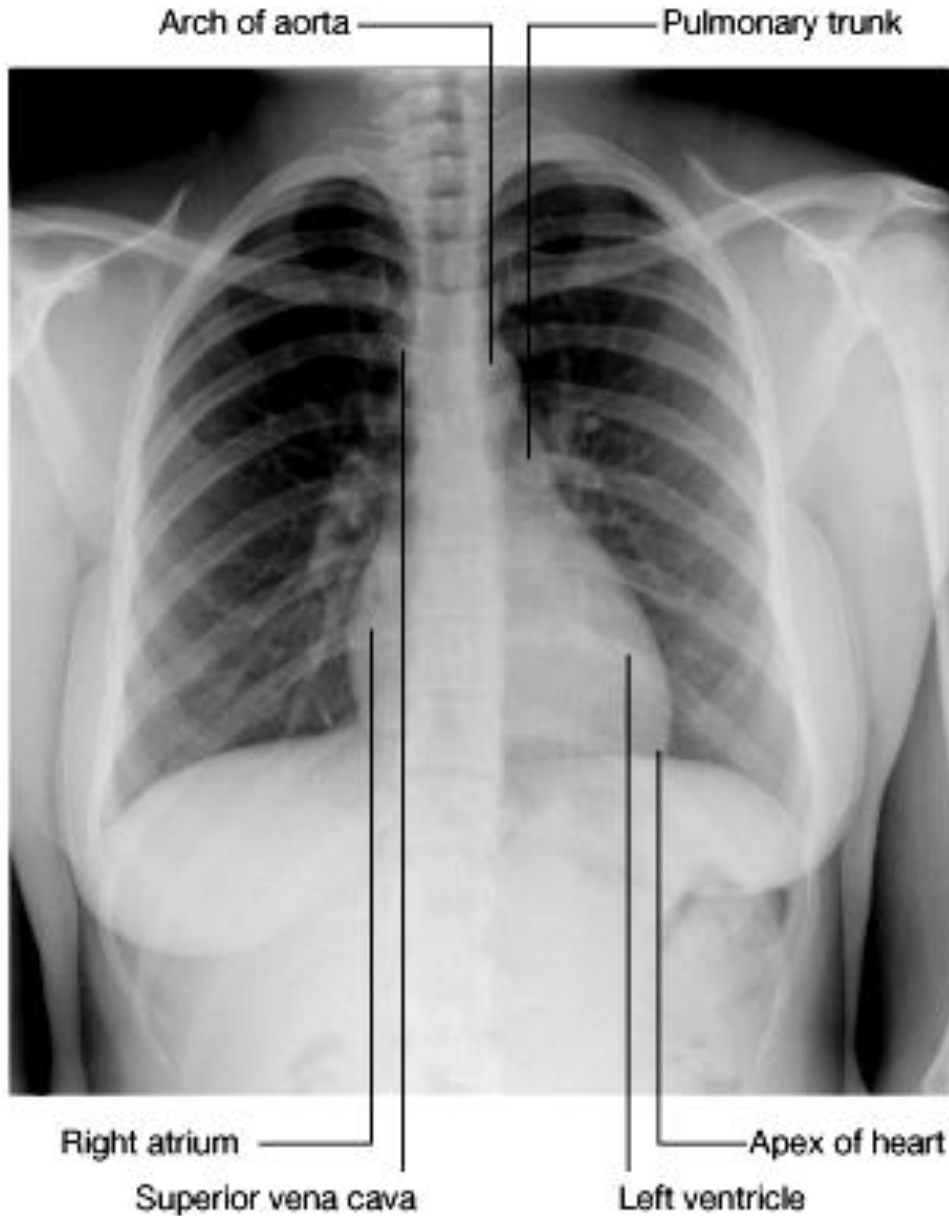


23. Cardiac Hypertrophy



- **Left atrial enlargement** (hypertrophy) secondary to **mitral valve** failure may **compress** on the **esophagus** and manifest as dysphagia (difficulty in swallowing).
- It may be observed as a filling defect in the esophagus by **barium swallow on the lateral thoracic X-Ray**

P-A projection



Cardiac Shadow

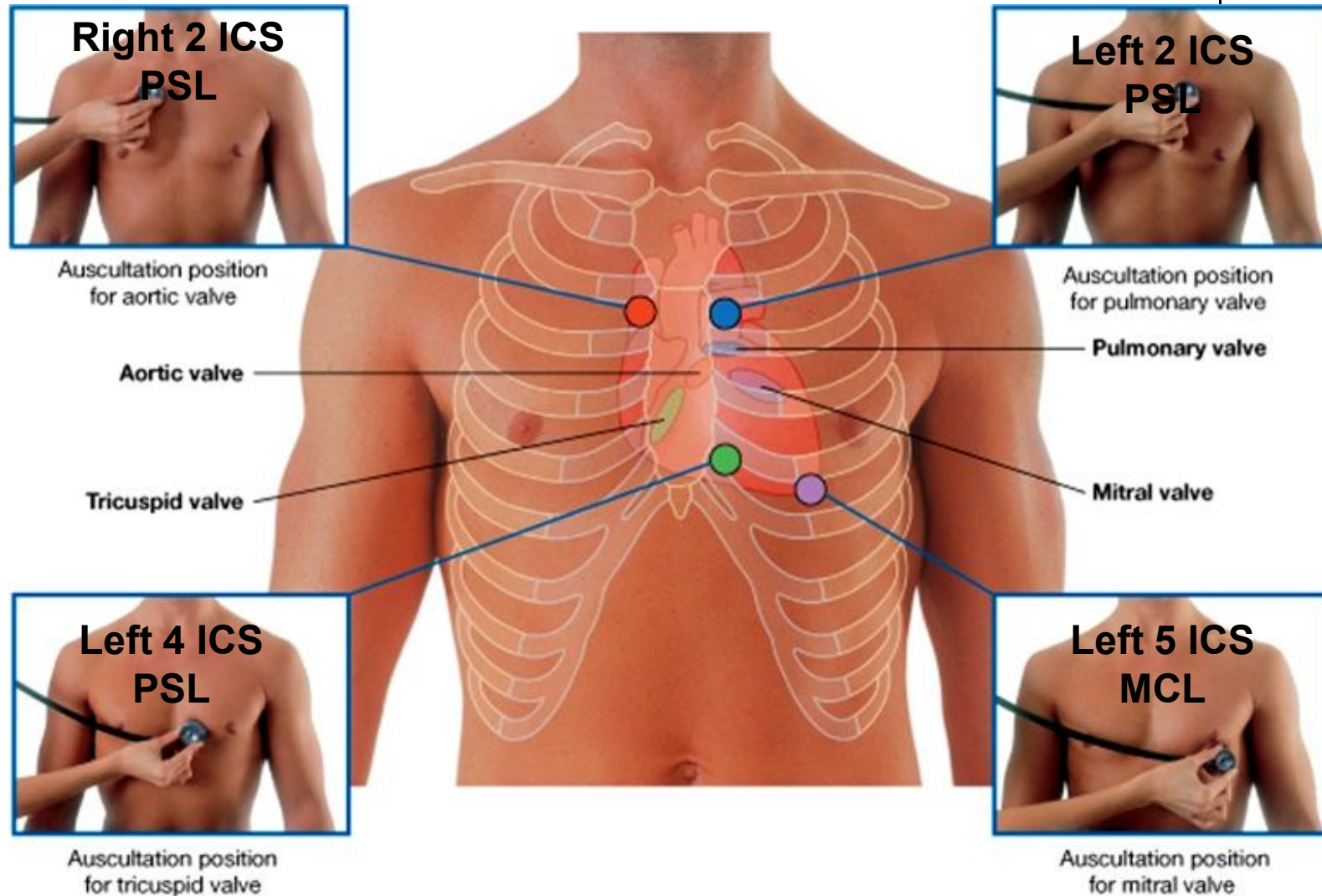
Right border is formed by:

1. SVC,
2. Right atrium

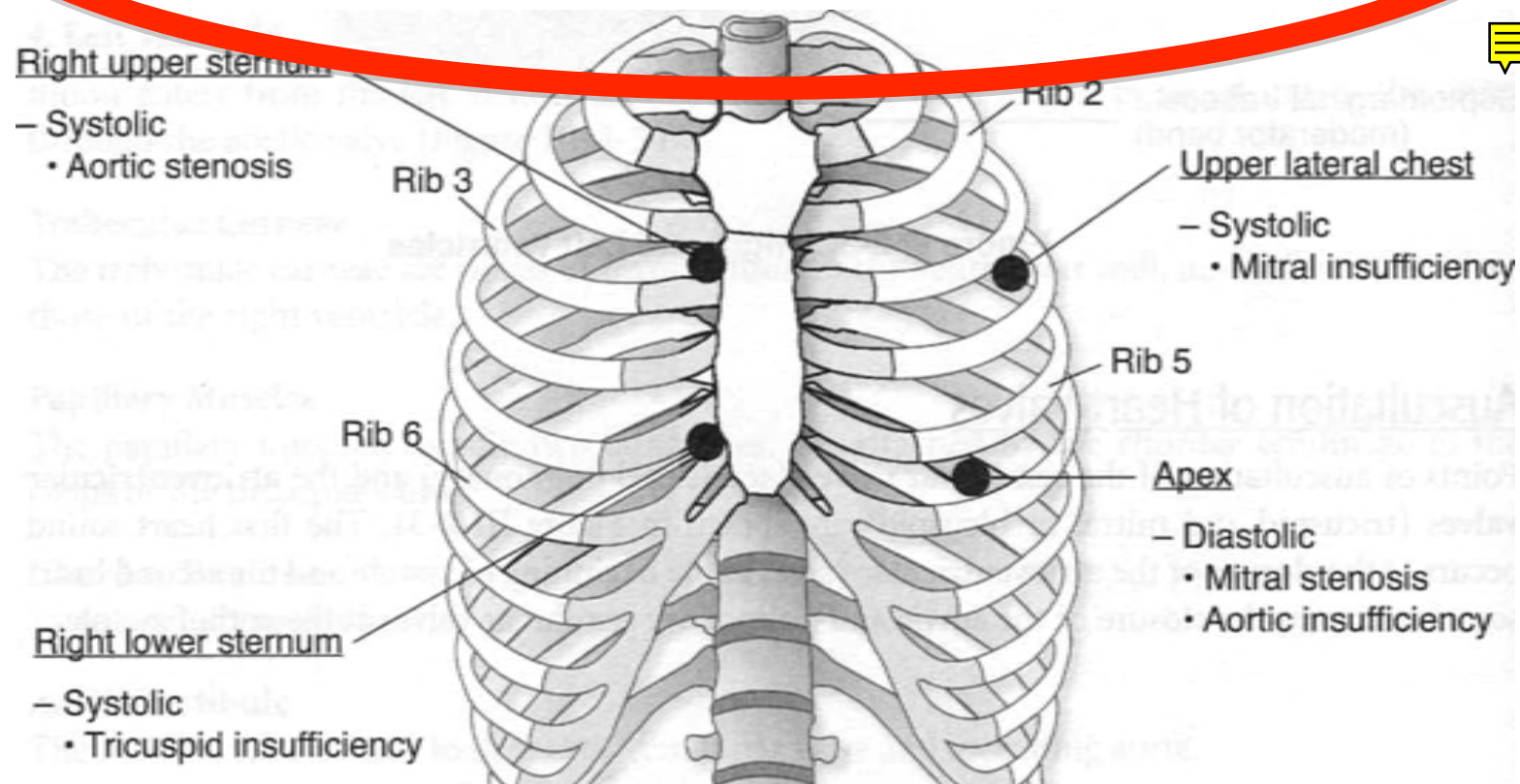
Left border is formed by:

1. Aortic arch
2. Pulmonary trunk
3. Left auricle
4. Left ventricle



24. Auscultation of Heart Valves



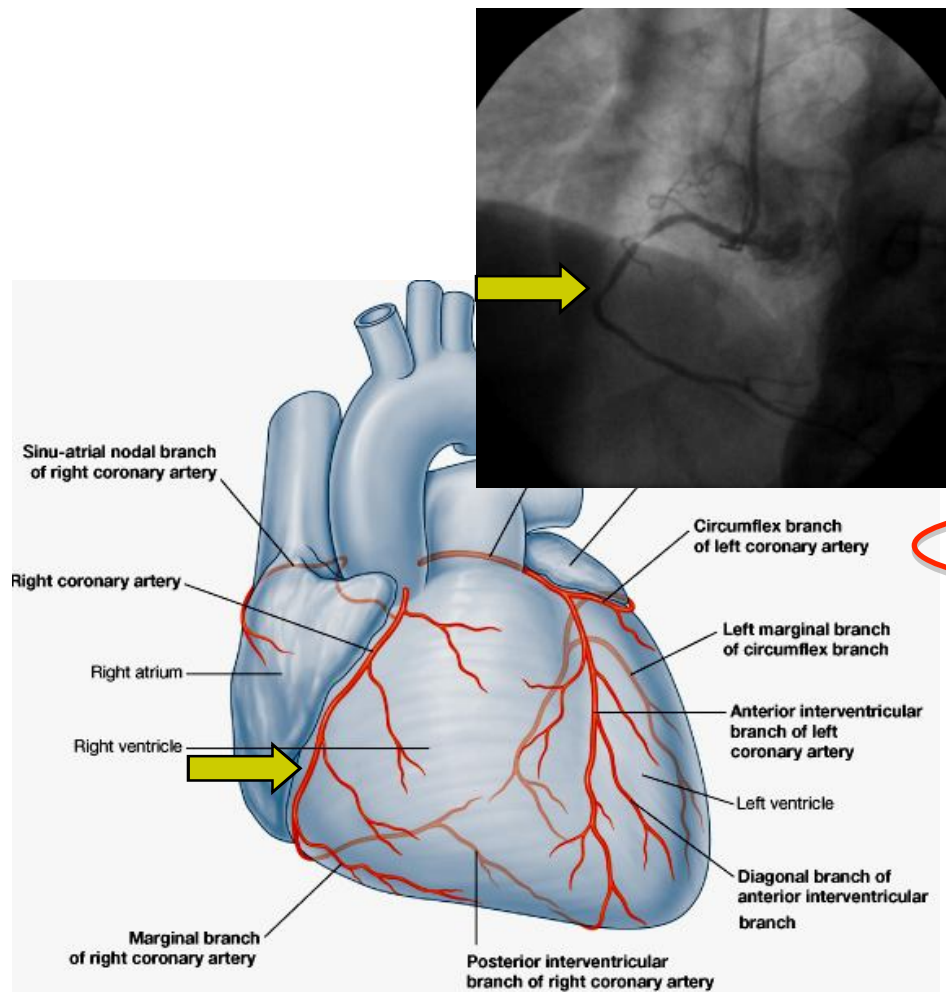
Auscultation sites for mitral and aortic murmurs



A heart murmur is heard **downstream from the valve**:

- **stenosis** is **orthograde** direction from valve 
- **insufficiency** is **retrograde** direction from valve 

25. Blood supply of the Heart: Right coronary artery (RCA)

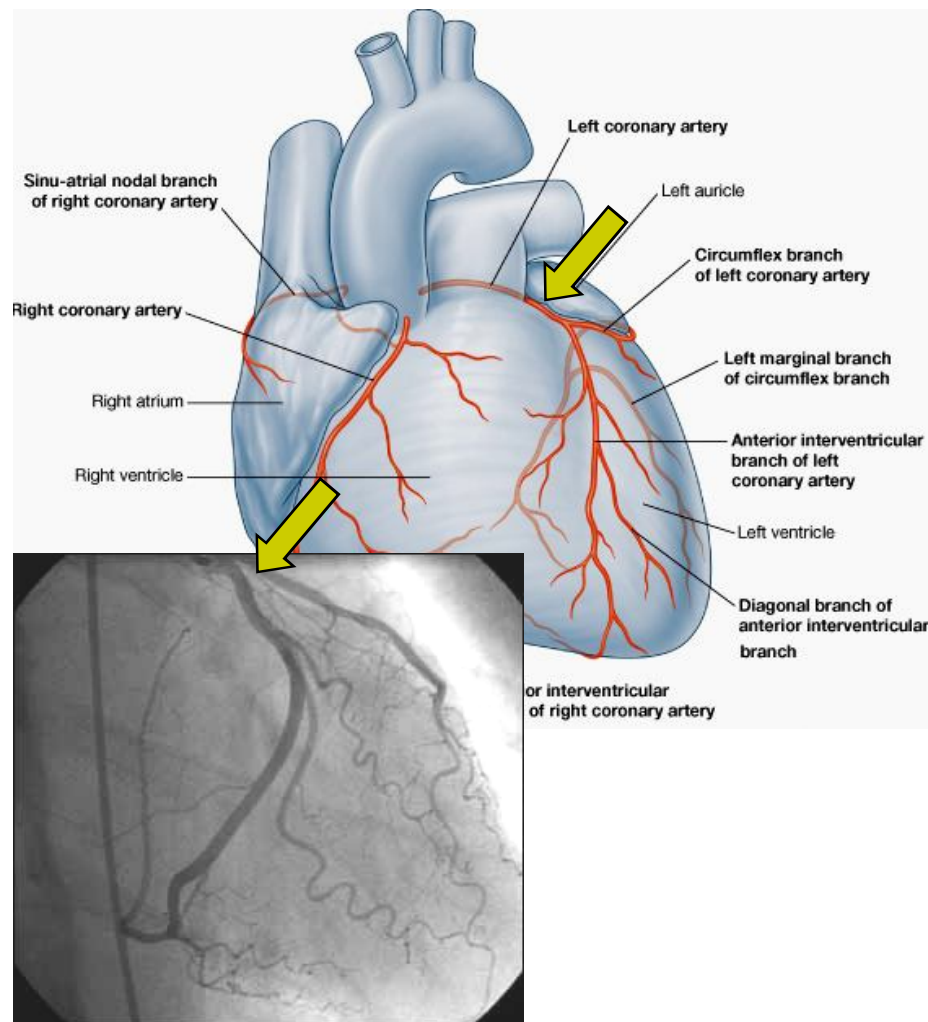


- It supplies major parts of the **right atrium** and the **right ventricle**.
- It anastomoses with the marginal branch of the left coronary artery posteriorly

Branches:

1. **Anterior cardiac branches** – supplies the **right atrium**
2. **Nodal branch** – supplies the (1) **SA** node, (2) **AV** node
3. **Marginal artery** – supplies the right ventricle
4. **Posterior interventricular artery** – supplies (1) **diafragmatic (inferior) surface of both ventricles** and (2) **posterior 1/3 of the IV septum**

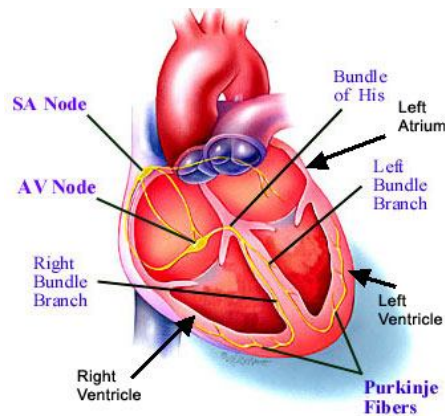
Left coronary artery (LCA)



Branches:

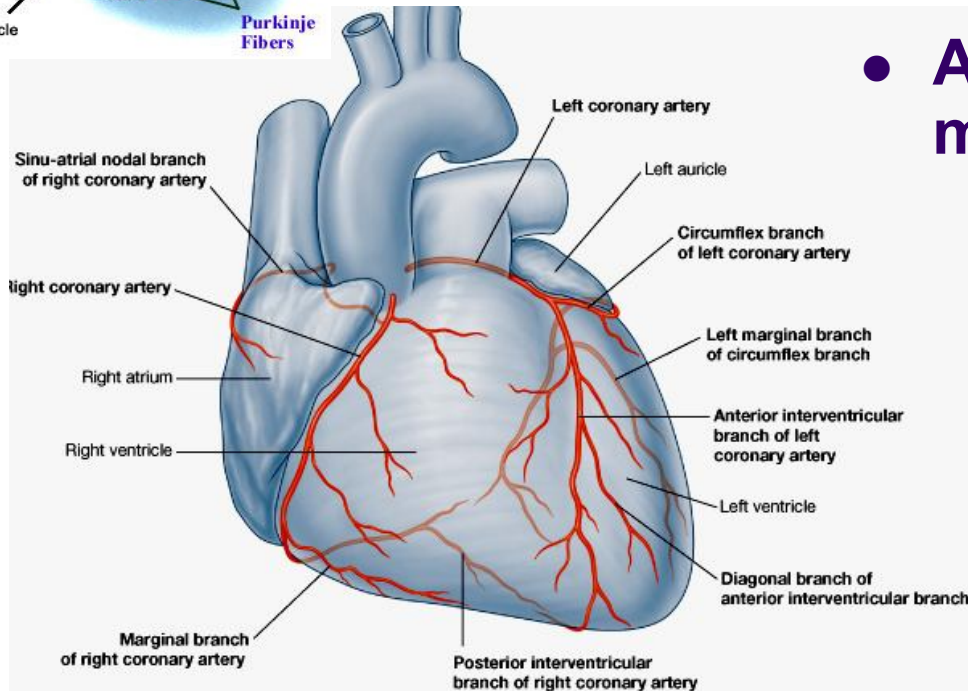
1. **Anterior interventricular artery** descends in the anterior interventricular sulcus and provides branches to the (1) **anterior heart wall**, (2) **anterior 2/3 of IV septum**, (3) **bundle of His**, and (4) **apex** of the heart.
2. **Circumflex artery** – winds around the left margin of the heart in the atrioventricular groove to anastomose with the right coronary artery posteriorly; supplies the **left atrium** and **left ventricle**

Blood supply of the conducting system

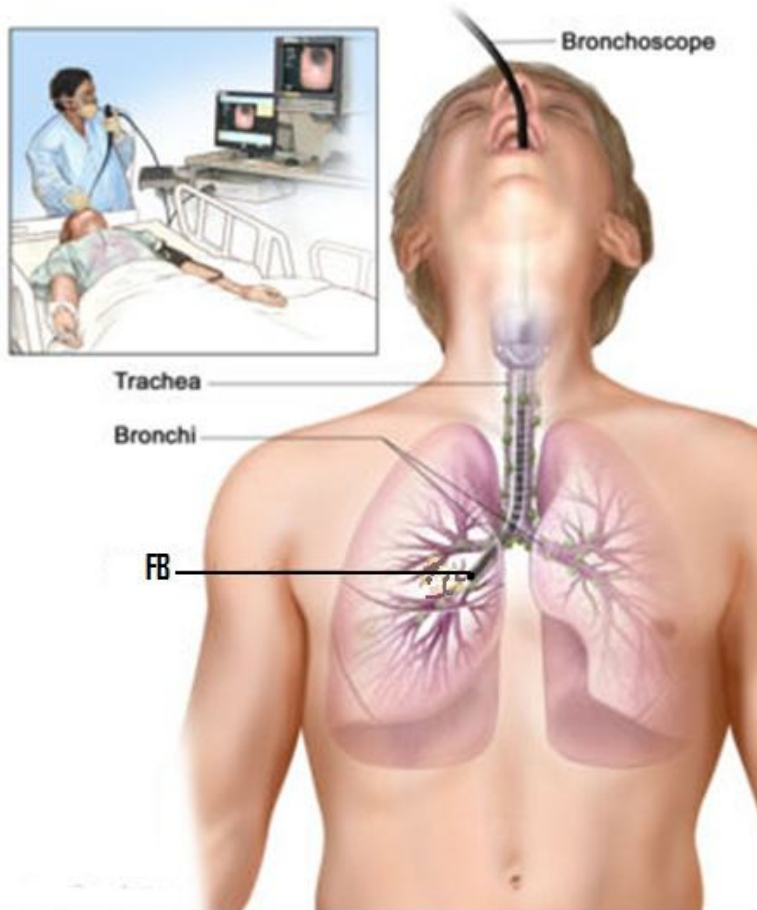


- SA node – RCA
- AV node – RCA

- AV bundle (and moderator band)- LCA
AV Bundle of His



26. Aspiration of Foreign Bodies & Bronchopulmonary segments



Aspiration of Foreign Bodies:

- Inhalation of FB's (e.g. pins, parts of teeth, screws, nuts, bolts, toys) into the lower respiratory tract is common, especially **in children**
- More likely to enter the **right primary bronchus** and pass into the **middle** or **lower lobe bronchi**
- If the vertical position of the body, the foreign body usually falls into the **posterior basal segment** of the **right inferior lobe**.

Right lung:

10 bronchopulmonary segments



Superior lobe:

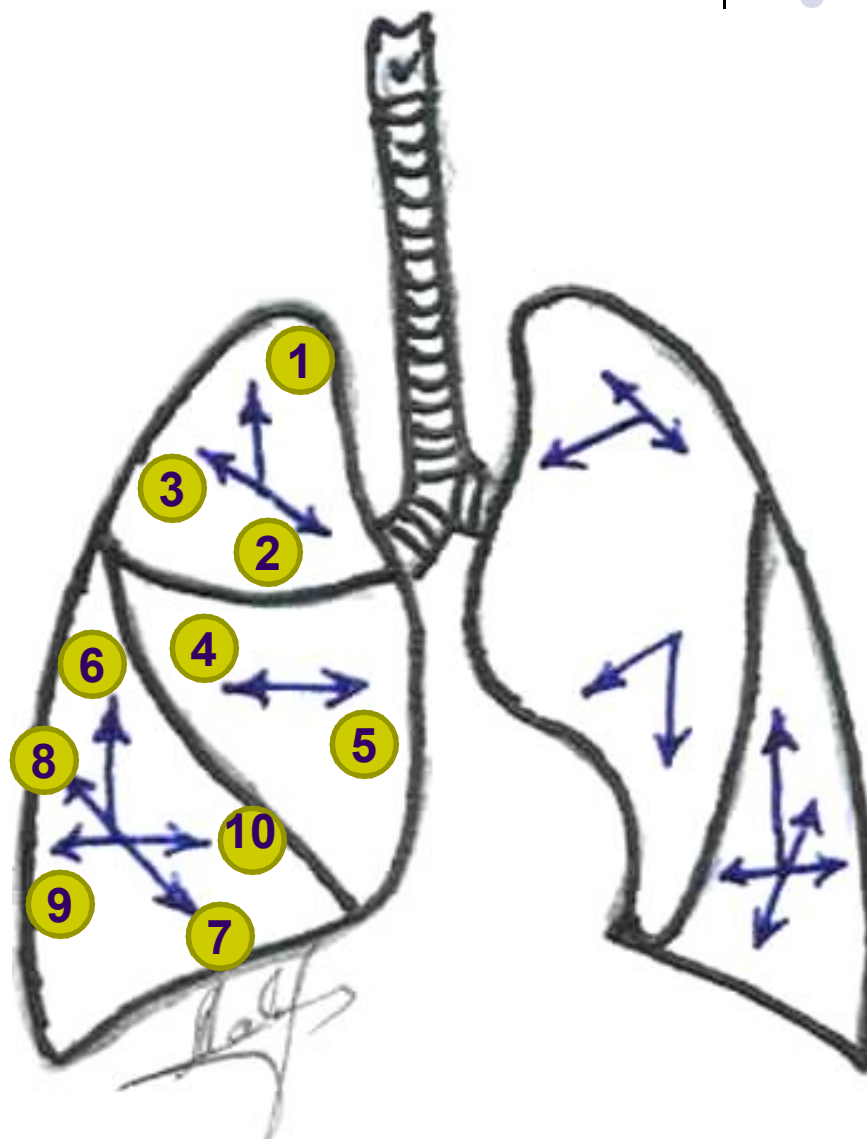
1. Apical
2. Anterior
3. Posterior

Middle lobe:

4. Lateral
5. Medial

Inferior lobe:

6. Superior
7. Anterior basal
8. Posterior basal
9. Lateral basal
10. Medial basal



Left lung:

9 bronchopulmonary segments

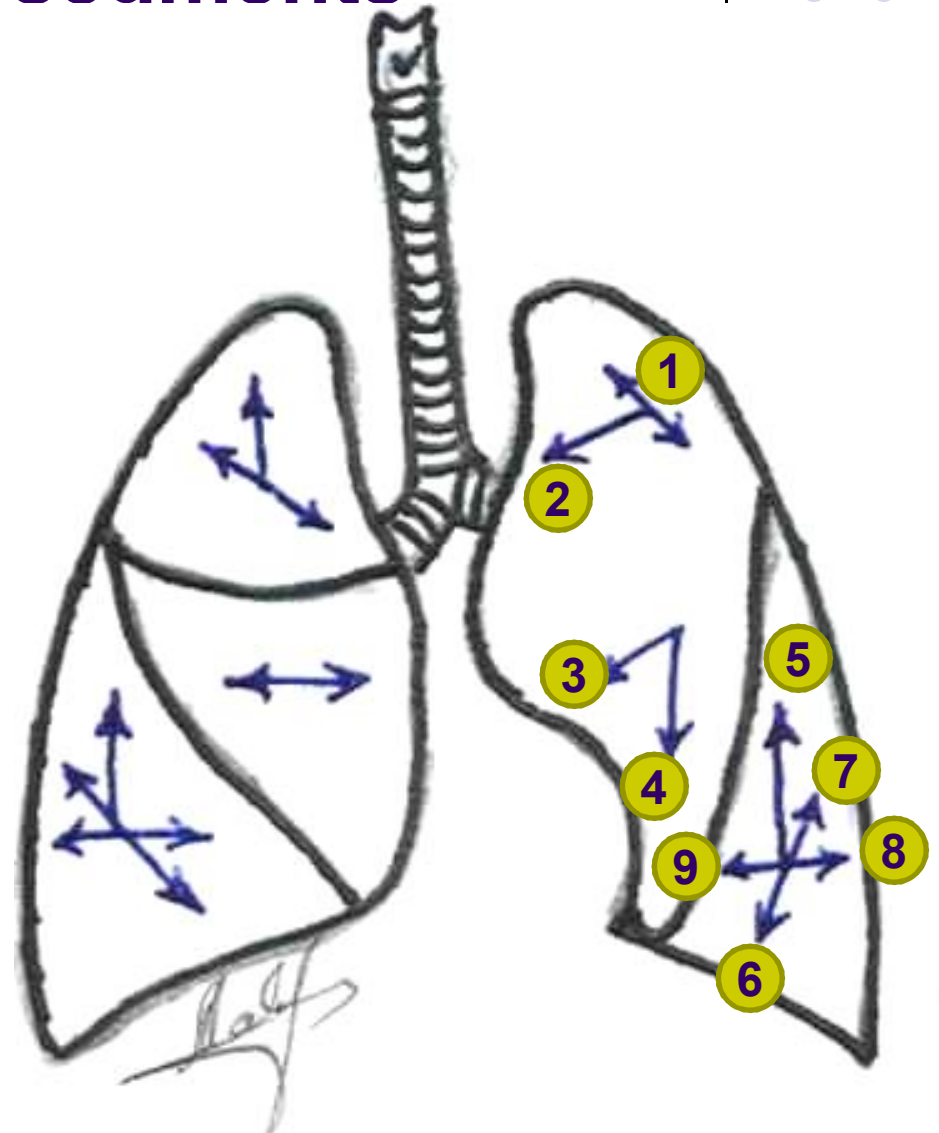


Superior lobe:

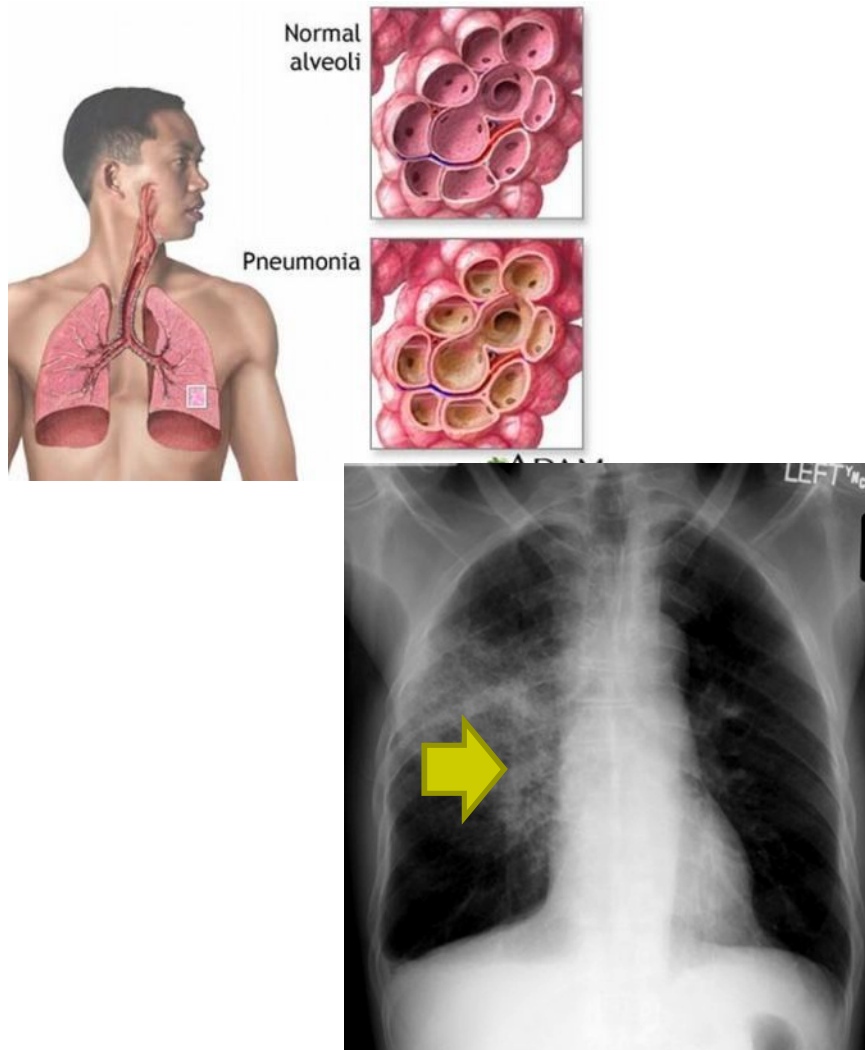
1. Apicoposterior
2. Anterior
3. Superior lingular
4. Inferior lingular

Inferior lobe:

5. Superior
6. Anterior basal
7. Posterior basal
8. Lateral basal
9. Medial basal



27. Lung diseases: Pneumonia



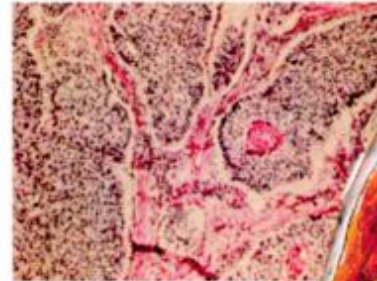
- Pneumonia is an **inflammation** of the lung, caused by an infection or chemical injury to the lungs.
- Three common causes are **bacteria, viruses** and fungi.
- Symptoms: **cough, chest pain**, fever, and difficulty in breathing.
- **Chest x-rays:** areas of **opacity** (seen as white) of the lung parenchyma and **enlargement** of bronchomediastinal **lymph nodes** (mediastinal widening).

Bronchogenic Carcinoma

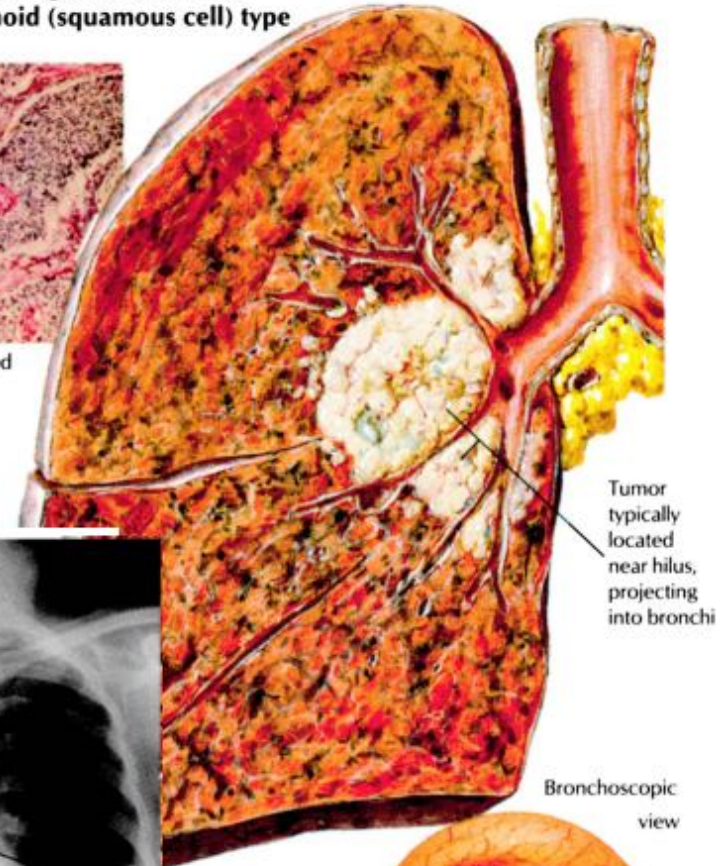


- Arises in the mucosa of the large **bronchi**
- Produces as persistent, productive **cough** or **hemoptysis**
- Early metastasis to **thoracic** (bronchomediastinal) lymph nodes
- Hematogenous spread to the brain, bones, lungs, suprarenal glands
- A tumor at the apex of the lung (**Pancoast tumor**) may result in thoracic outlet syndrome

Bronchogenic carcinoma:
epidermoid (squamous cell) type

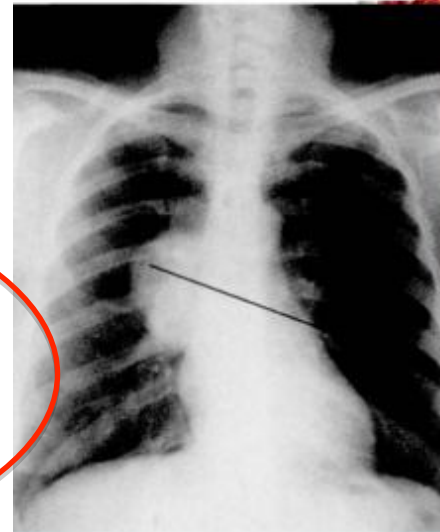


Nests of tumor cells separated
by fibrous bands

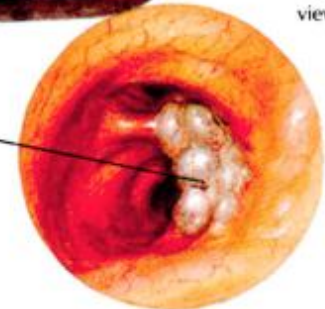


Tumor
typically
located
near hilum,
projecting
into bronchi

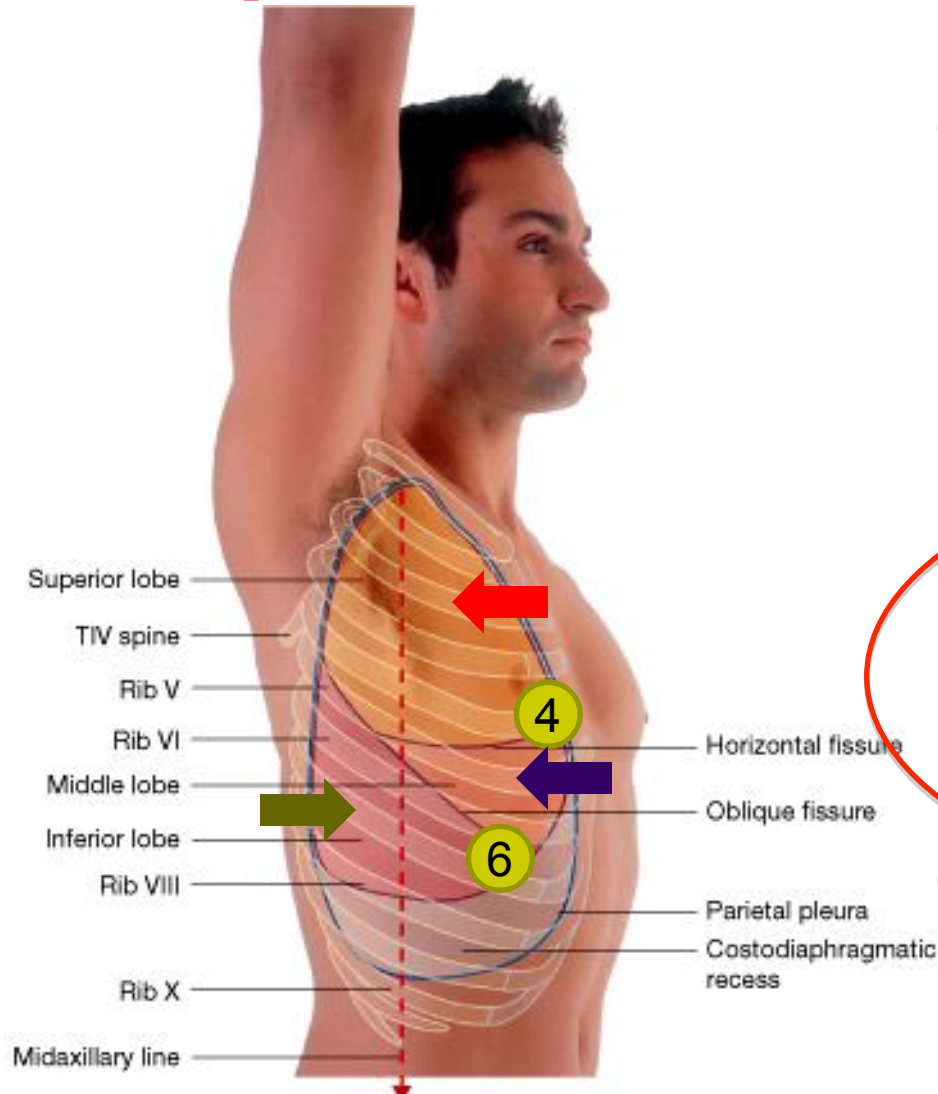
Bronchoscopic
view



Tumor



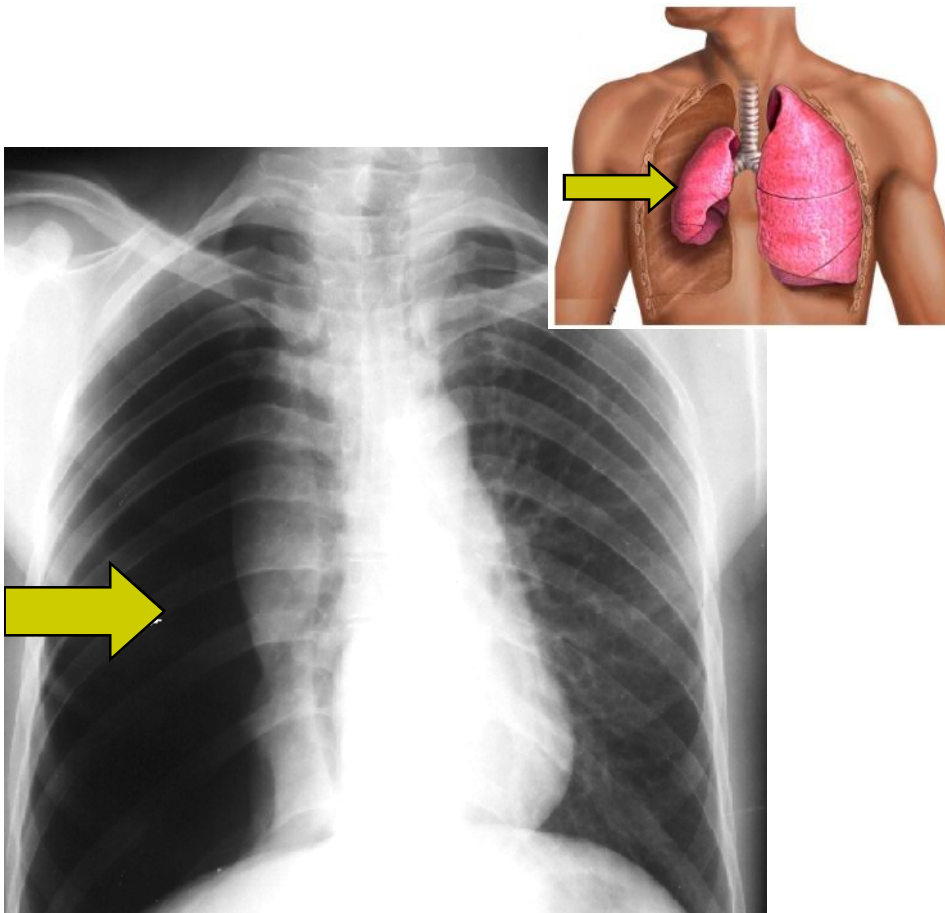
Qs about Auscultation and **penetrated wounds**



- To listen to **breath sounds** of the **superior lobes** of the right and left lungs, the stethoscope is placed on the superior area of the anterior chest wall (**above the 4th rib for the right lung & above 6th for the left one**).
- For **breath sounds** from the **middle lobe of the right lung**, the stethoscope is placed on the anterior chest wall **between the 4th and 6th ribs**
- For the **inferior lobes** of **both lungs**, **breath sounds** are primarily heard on the **posterior** chest wall.

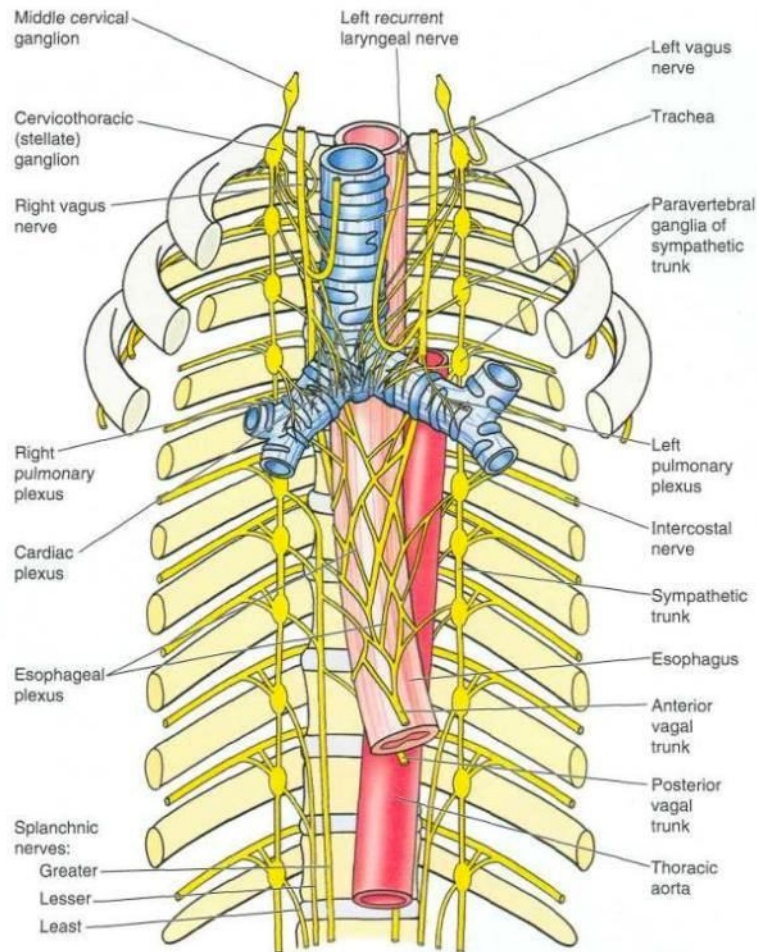


28. Open pneumothorax



- It is entry of **air** into a pleural **cavity** causing **lung collapse**.
- **Open pneumothorax** – due to stab wounds of the thoracic wall which pierce the parietal pleura so that the **pleural cavity is open to the outside** air via the lung or through the chest wall.
- **Air moves freely** through the wound during inspiration and expiration. During **inspiration**, air enters the chest wall and the mediastinum will shift toward other side and compress the opposite lung. During **expiration**, air exits the wound and the mediastinum moves back toward the affected side.

Nerve supply of the pleura

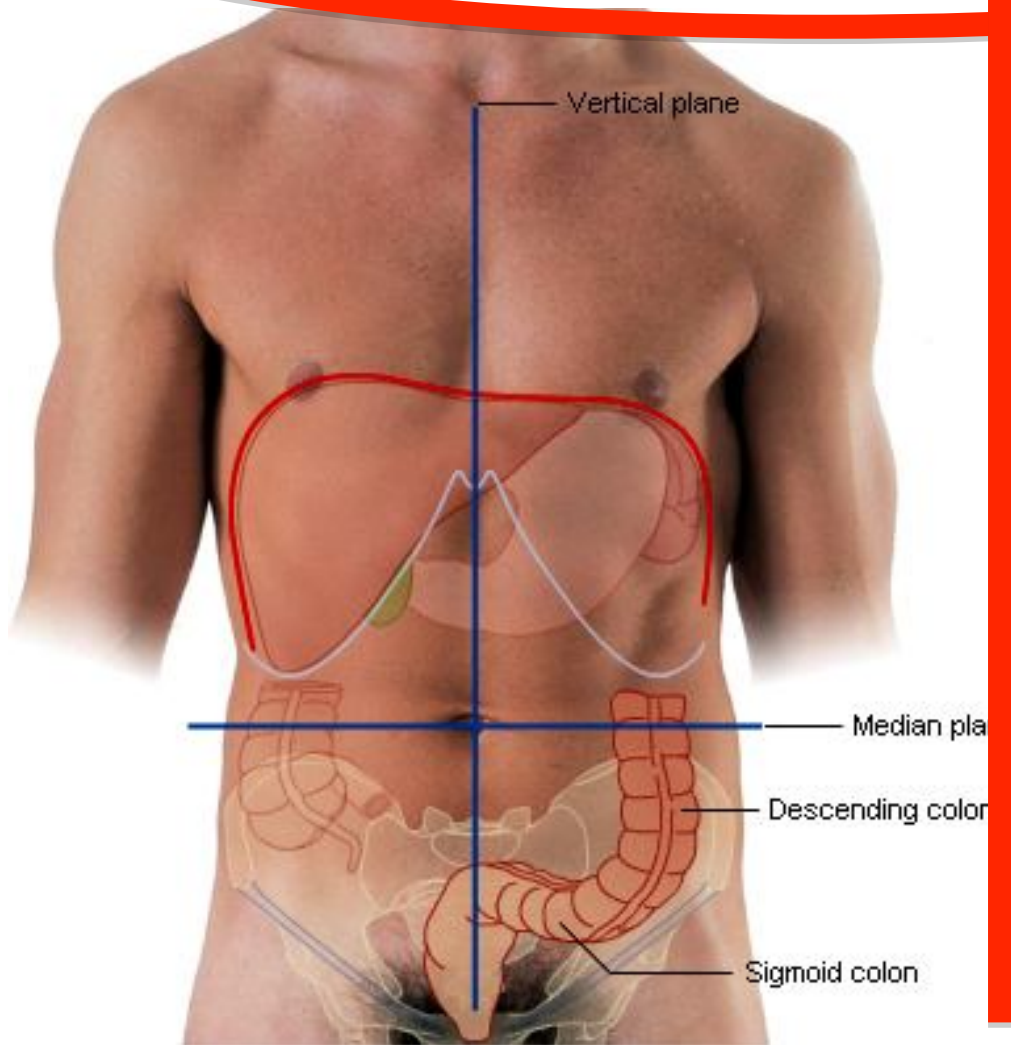


Parietal Pleura – sensitive to general sensibilities (pain, temperature, touch, and pressure) - **somatic sensory innervation**:

- **costal pleura** – **intercostal nerves**
- **mediastinal pleura** – **phrenic nerve**
- **diaphragmatic pleura** – phrenic nerve over the domes and lower 6 intercostal nerves around the periphery

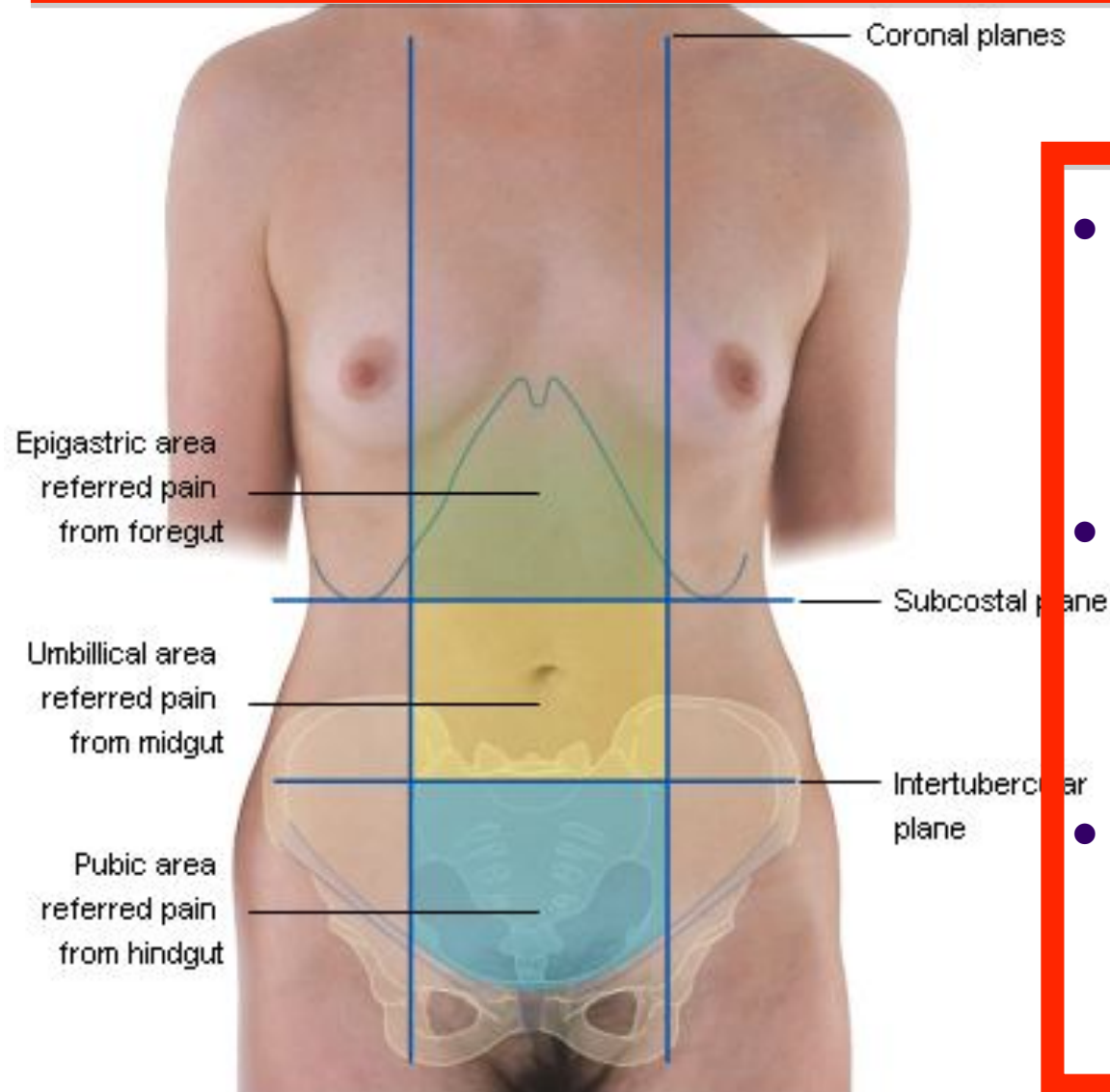
Visceral Pleura – sensitive to stretch but insensitive to general sensibilities; **autonomic** nerve supply from the pulmonary plexus

29. Anterior abdominal wall



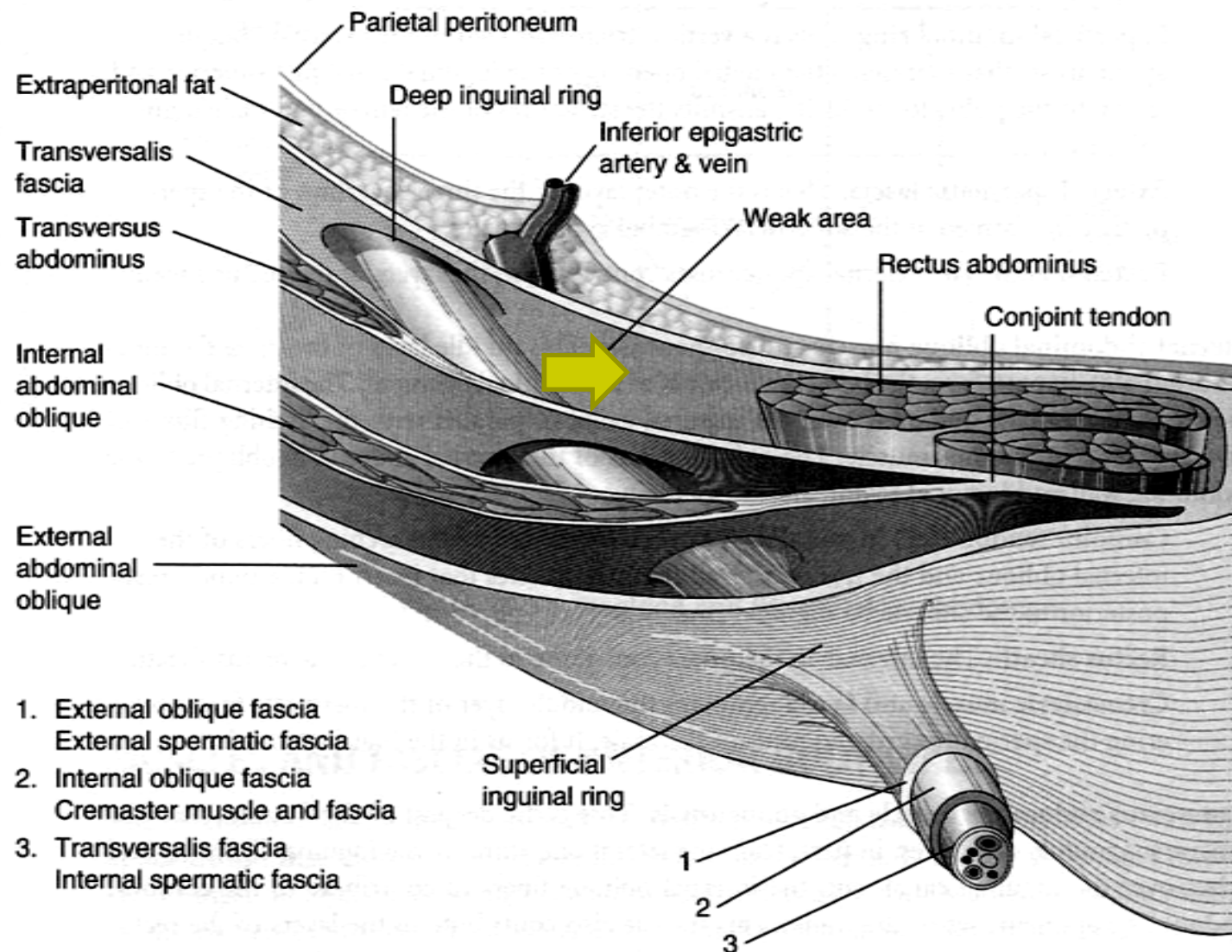
- The **liver** and **gallbladder** are in the **right upper quadrant**;
- The **stomach** and **spleen** are in the **left upper quadrant**;
- The **cecum** and **appendix** are in the **right lower quadrant**;
- The end of the descending colon and **sigmoid colon** are in the **left lower quadrant**.

Referred abdominal pain



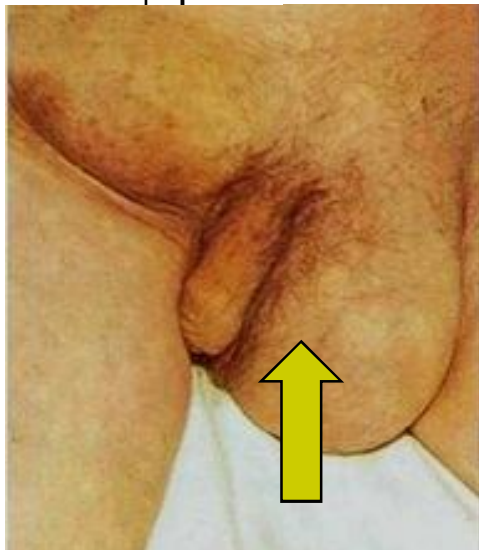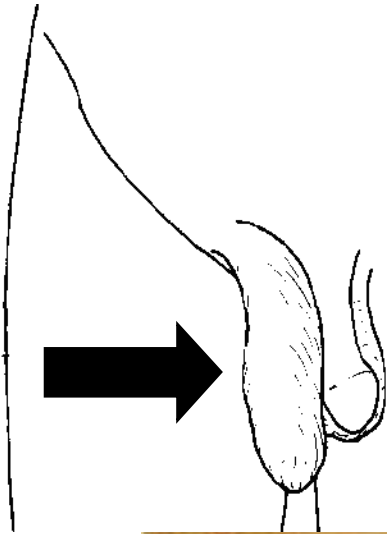
- Pain arising out of the **foregut** derived structures is referred to the **epigastric region**.
- Pain arising out of the **midgut** derived structures is referred to the **umbilical region**.
- Pain arising out of the **hindgut** derived structures is referred to the **hypogastric region**.

Transversalis fascia is the **FIRST STRUCTURE** which is crossed by **any abdominal hernia**





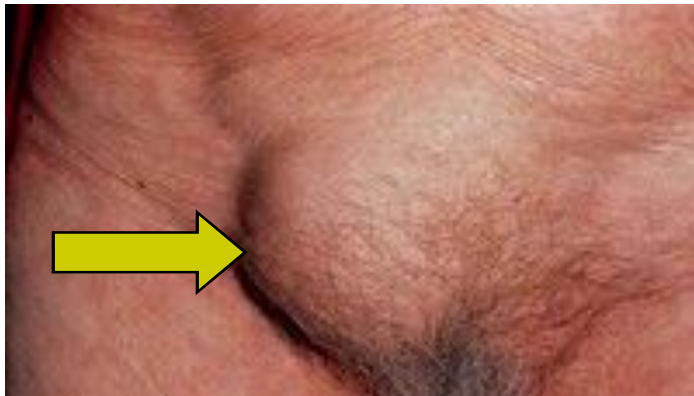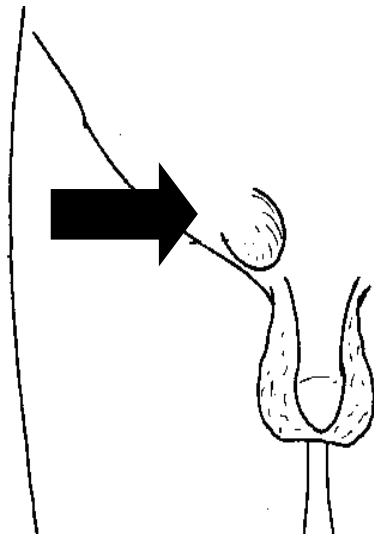
Indirect Inguinal Hernia



- Indirect inguinal hernia is the **most common form** of hernia and is believed to be **congenital in origin** (boys 0-3 years).
- It passes through the **deep inguinal ring lateral to the inferior epigastric vessels**, inguinal canal, **superficial inguinal ring** and **descend into the scrotum**.
- An indirect inguinal hernia is about **20 times more** common in males than in females, and nearly 1/3 are bilateral.
- It is more common on the **right** (normally, the right processus vaginalis becomes obliterated after the left; the right testis descends later than the left).

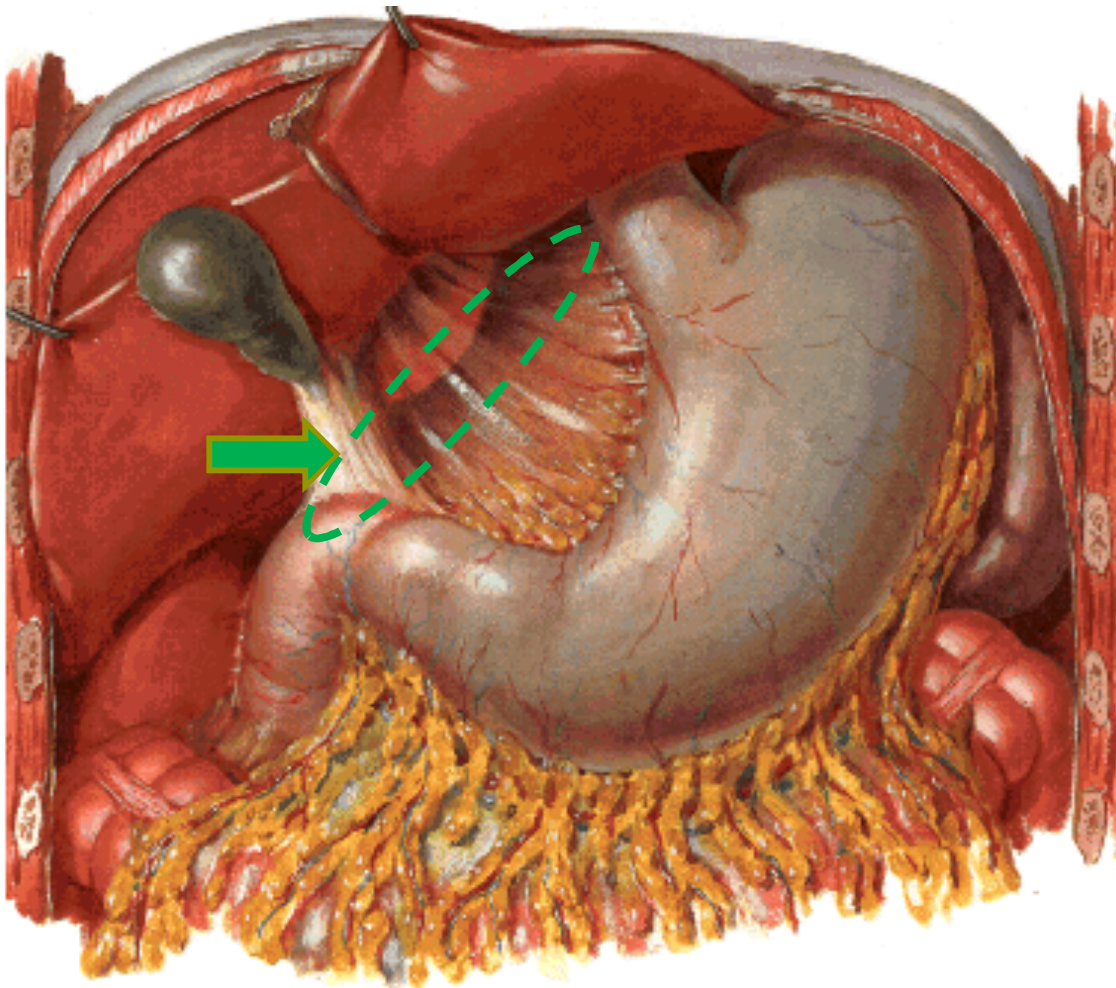


Direct Inguinal Hernia



- Direct inguinal hernia composes about **15%** of all inguinal hernias.
- During a **direct inguinal hernia**, the abdominal contents will protrude through the weak area of the posterior wall of the inguinal canal **medial** to the **inferior epigastric vessels** in the **inguinal [Hesselbach's] triangle** and after that through **superficial inguinal** ring. It **never descends** into the scrotum.
- It is a **disease of old men** with weak abdominal muscles. Direct inguinal hernias are rare in women, and most are bilateral.

30. Peritoneal structure: Lesser omentum



Consist of **2 ligaments**:

- hepatogastric
- hepatoduodenal

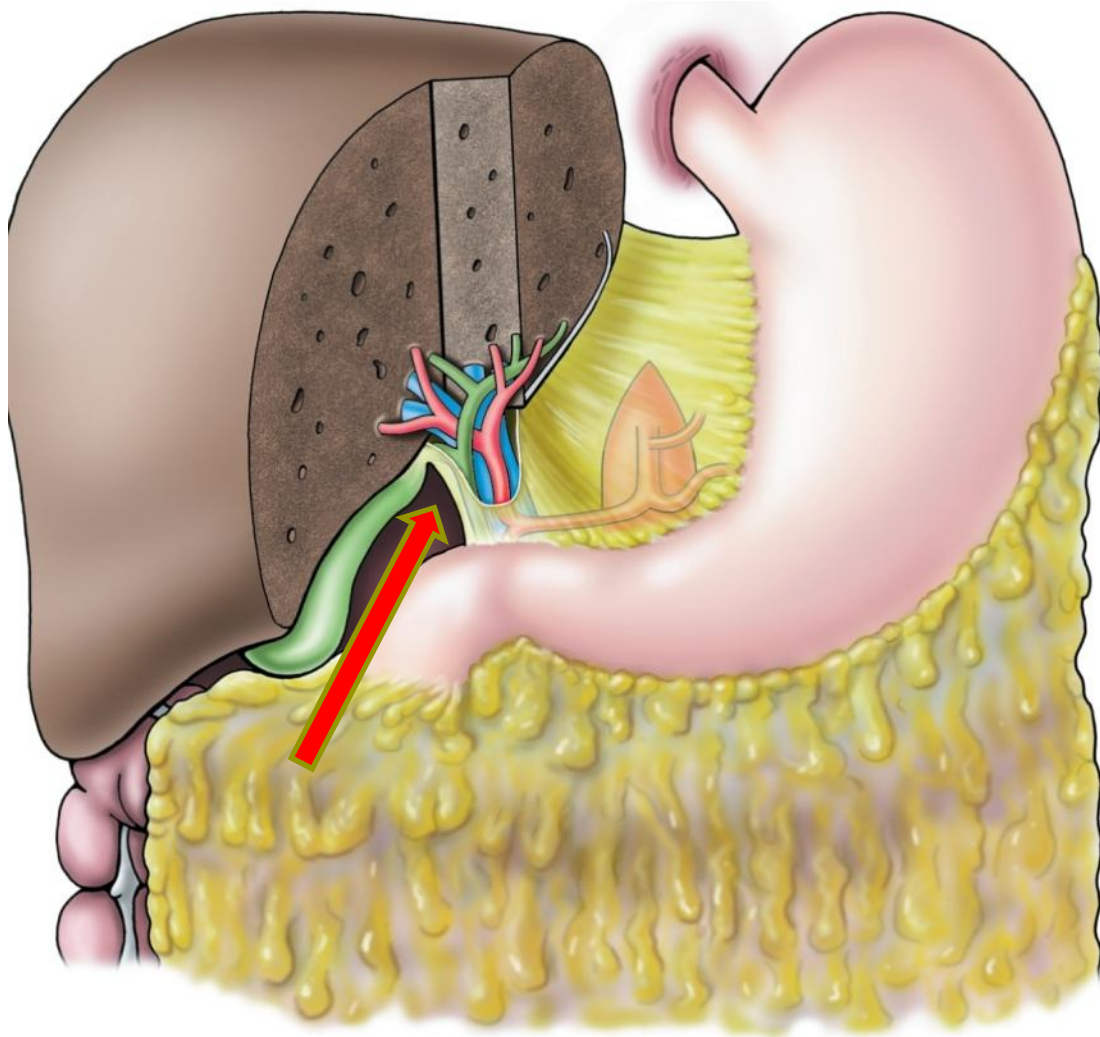
Contents :

- Right & Left gastric vessels
- Connective and fatty tissue

and **Portal triad**:

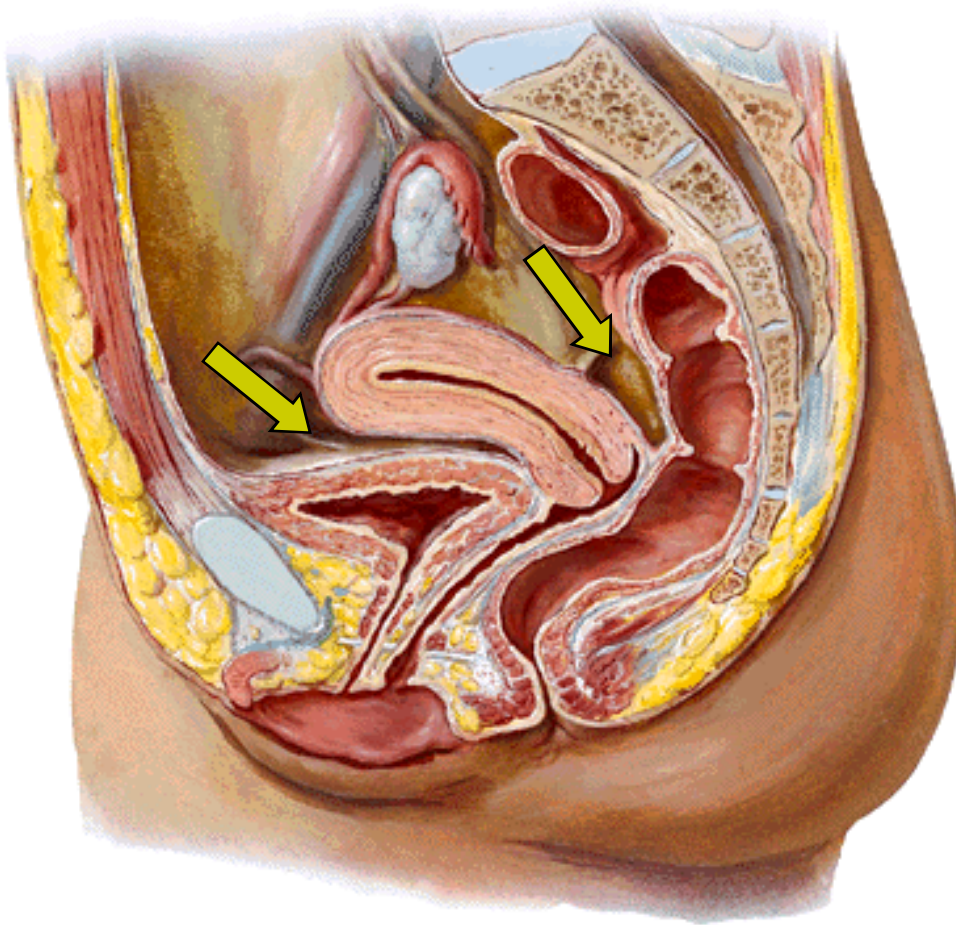
- **Bile duct**
- **Portal vein**
- **Proper hepatic artery**

Epiploic (Winslow's) foramen



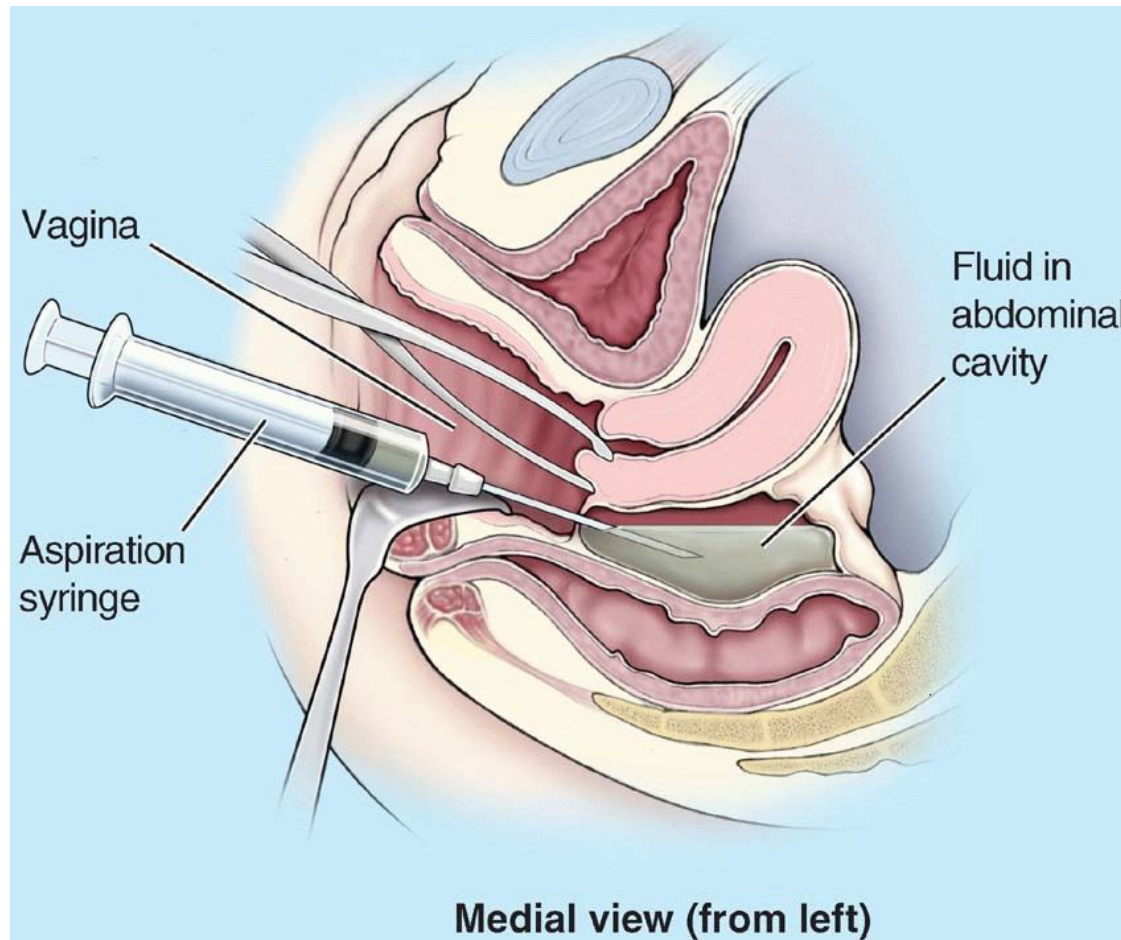
- **Anteriorly:** The free border of the **hepatoduodenal ligament**, containing **portal triad (DVA)**.
- **Posteriorly:** **IVC**
- **Superiorly:** Caudate lobe of the **liver**.
- **Inferiorly:** The **1st** part of the **duodenum**.

Douglas (rectouterine) pouch



- **Rectouterine pouch (pouch of Douglas):** deeper point of peritoneal space in **vertical** position of the female body between the **rectum** and the **uterus**. It is space of the **pelvic abscess location**.
- **Vesicouterine pouch:** it is deepness between the **uterus** and the urinary **bladder**.

Culdocentesis




- Culdocentesis is **aspiration of fluid** from the cul-de-sac of Douglas (rectouterine pouch) by a needle puncture of the **posterior vaginal fornix** near the midline between the uterosacral ligaments
- Because the **rectouterine pouch** is the **lowest portion** of the female peritoneal cavity, it can collect inflammatory fluid (pelvic abscess).

31. Everything about Foregut, Midgut & Hindgut

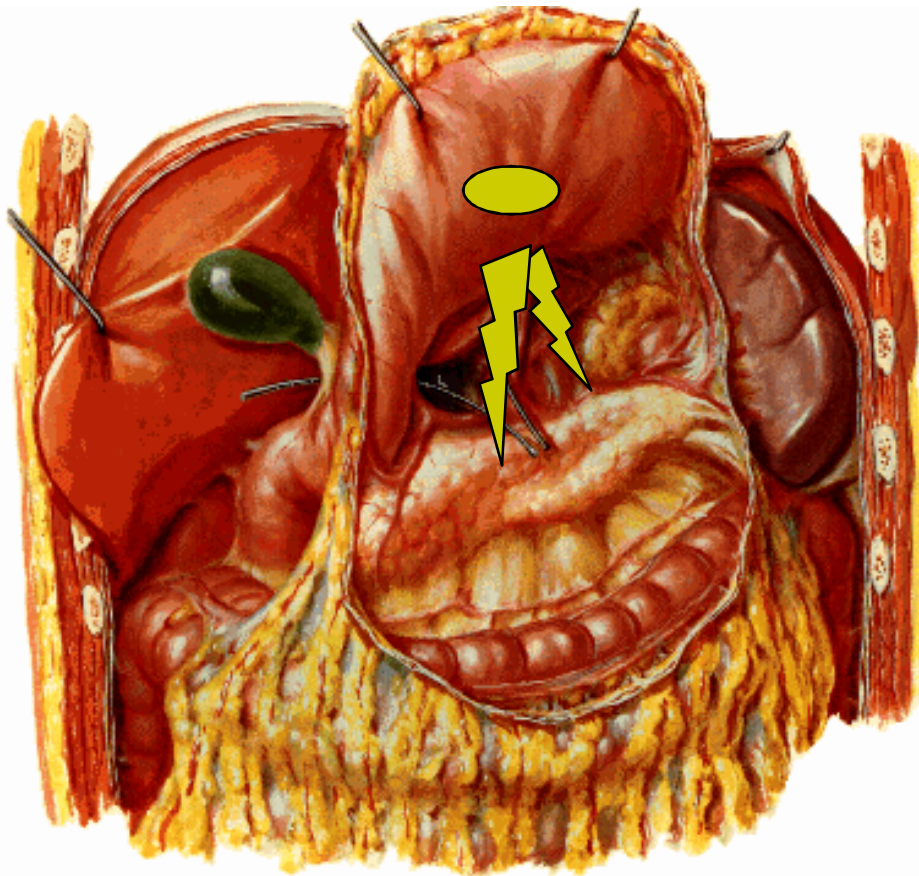


FOREGUT	MIDGUT	HINDGUT
Esophagus Stomach Duodenum (1 st and 2 nd parts) Liver Pancreas Biliary apparatus Gallbladder spleen	Duodenum (2 nd , 3 rd , 4 th parts) Jejunum Ileum Cecum (with Appendix) Ascending colon Transverse colon (proximal 2/3)	Transverse colon (distal 1/3) Descending colon Sigmoid colon Rectum (anal canal above pectinate line)



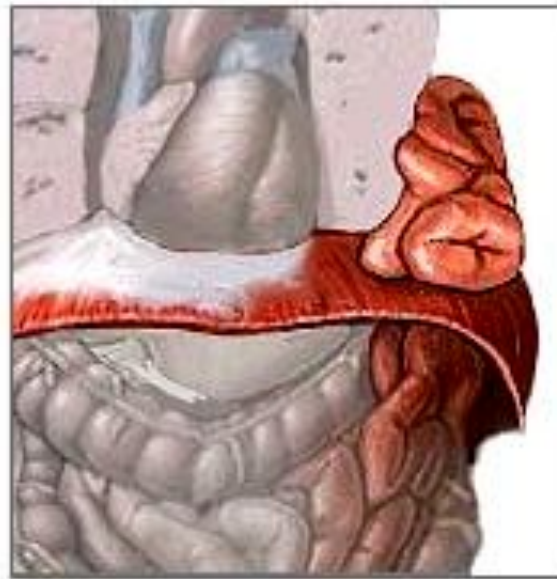
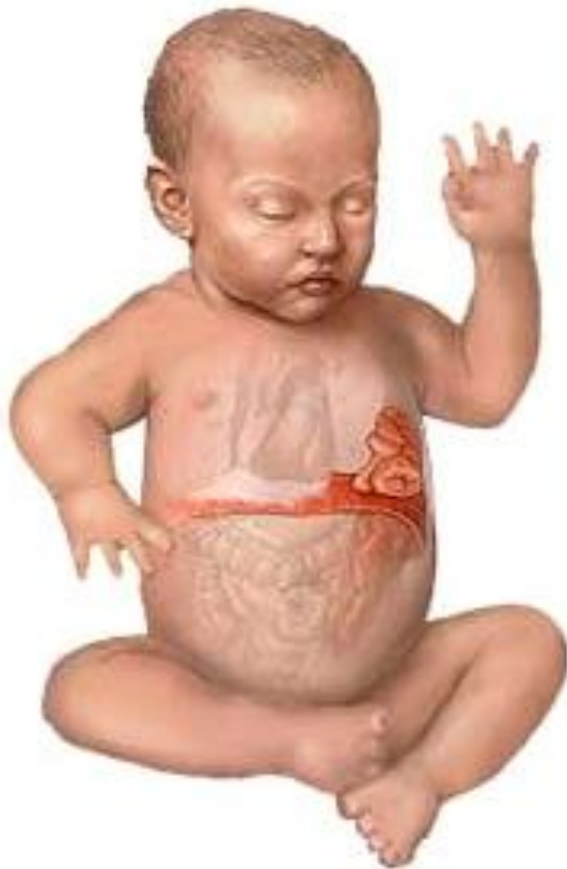FOREGUT	MIDGUT	HINDGUT
Artery: CA	Artery: SMA	Artery: IMA
Parasympathetic innervation: vagus nerves, CNX	Parasympathetic innervation: vagus nerves, CNX	Parasympathetic innervation: pelvic splanchnic nerves, S2-S4
Sympathetic innervation: <ul style="list-style-type: none">•Preganglionics: greater splanchnic nerves, T5-T9•Postganglionics: celiac ganglion	Sympathetic innervation: <ul style="list-style-type: none">•Preganglionics: lesser splanchnic nerves, T10-T11•Postganglionics: superior mesenteric ganglion	Sympathetic innervation: <ul style="list-style-type: none">•Preganglionics: lumbar splanchnic nerves, L1-L2•Postganglionics: inferior mesenteric ganglion
Sensory Innervation: DRG T5-T9	Sensory Innervation: DRG T10-T11	Sensory Innervation: DRG L1-L2
Referred Pain: Epigastrium	Referred Pain: Umbilical	Referred Pain: Hypogastrium

32. Posterior gastric ulcer



1. **Posterior gastric ulcer** may erode through the posterior wall of the stomach into the **pancreas** resulting in referred pain to the back.
2. **Erosion of splenic artery** is very common in **posterior gastric ulcers** because of the proximity of the artery to this wall.

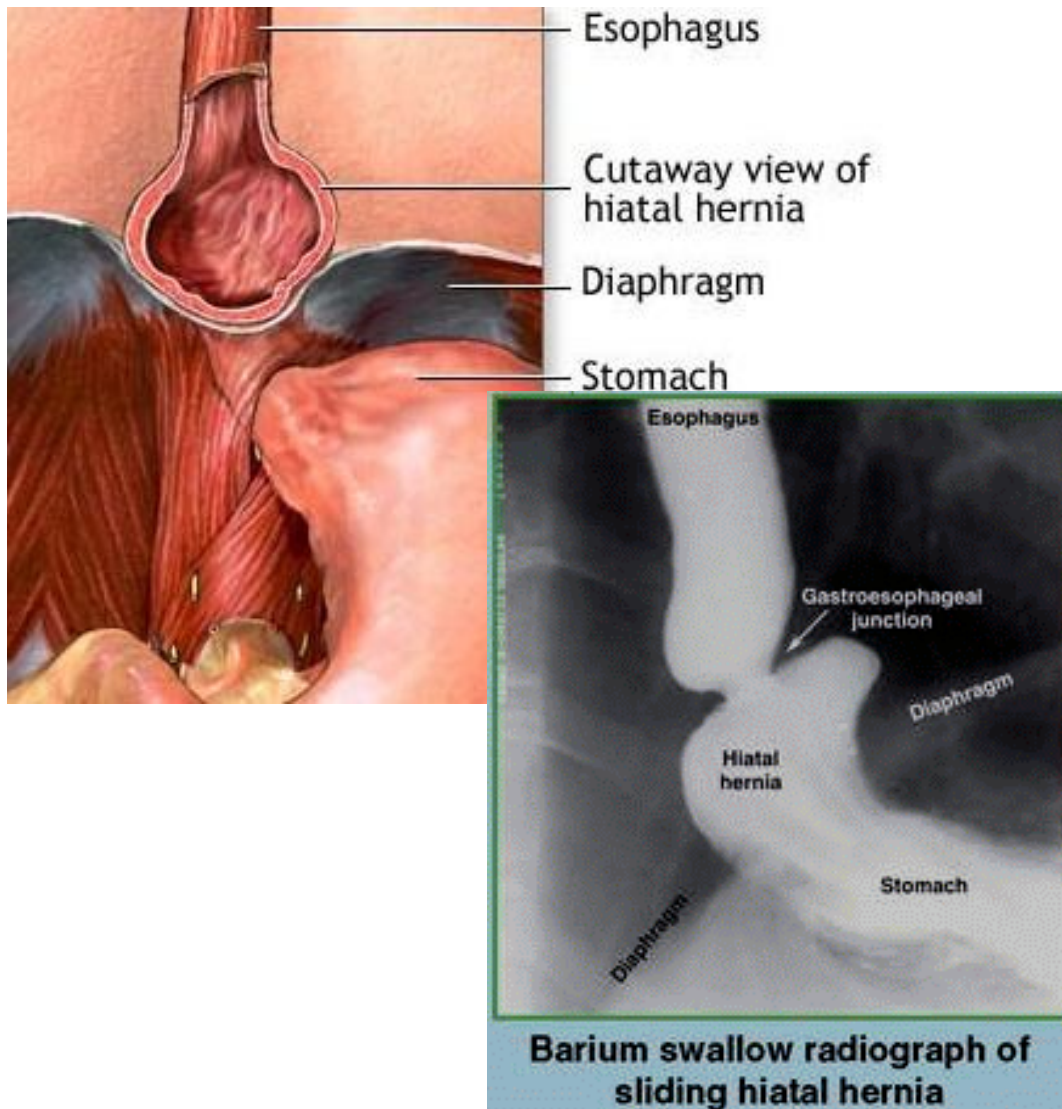
33. Congenital diaphragmatic hernia



Intestine protruding through hole in diaphragm

- Hernia of stomach or intestines through a **posterolateral defect in diaphragm** (foramen of Bochadalek).
- It is seen **in infants** and the mortality rate is high because of left **lung hypoplasia**.

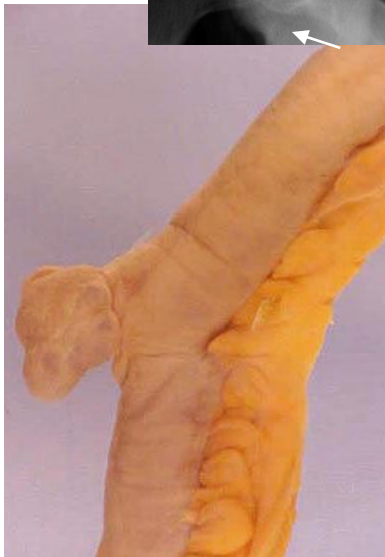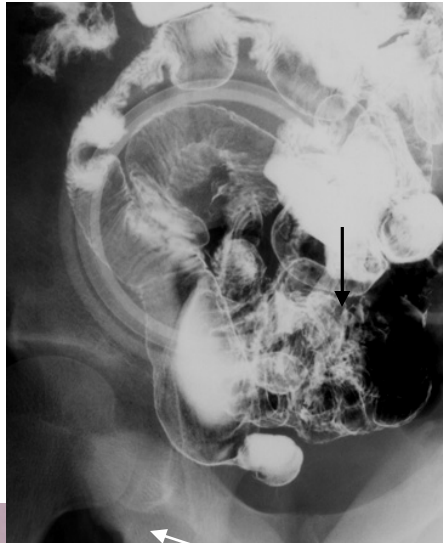
34. Sliding hiatal hernia



- A sliding hiatal hernia which occurs in individuals **past middle age** is caused by the **hernia of cardia of the stomach** into the thorax through the **esophageal hiatus** of the diaphragm.
- This can damage the **vagal trunks** as they pass through the hiatus and resulting in **hyposecretion of gastric juice.**

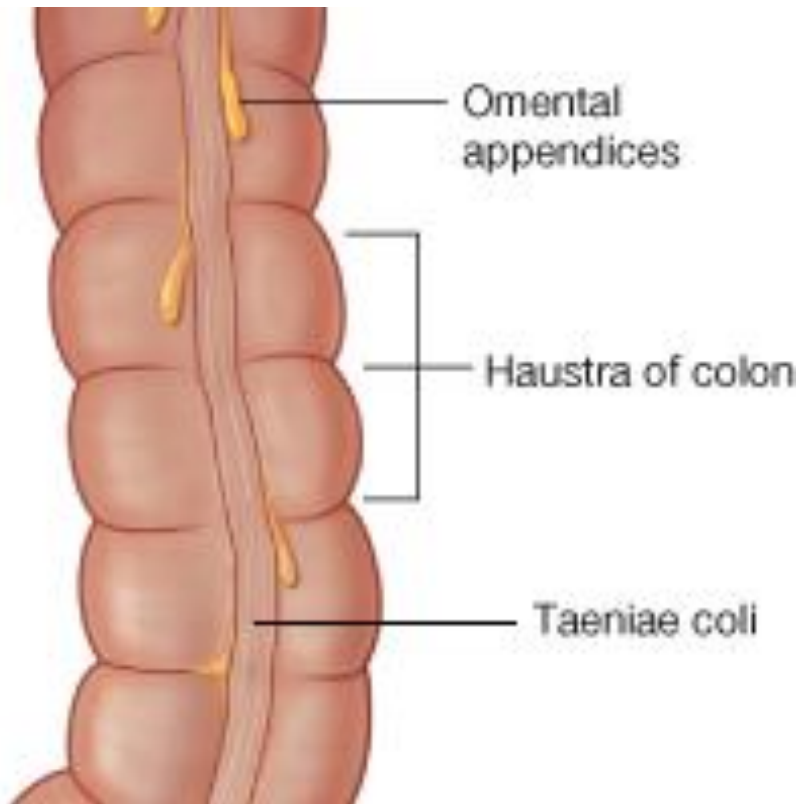


35. Meckel's diverticulum



- **Meckel's diverticulum** is a congenital anomaly representing a persistent portion of the **vitellointestinal duct**.
- This condition is often **asymptomatic** but occasionally becomes inflamed if it contains **ectopic** gastric, pancreatic, or **endometrial tissue**, which may produce ulceration.
- It occurs **in 2%** of patients, is located about **2 feet** (61 cm) **before the ileocecal junction**, and is about **2 inches** (5 cm) long.
- The diverticulum is clinically important because **diverticulitis**, liberation, bleeding, perforation, and obstruction are complications requiring surgical intervention and frequently **mimicking the symptoms of acute appendicitis**.

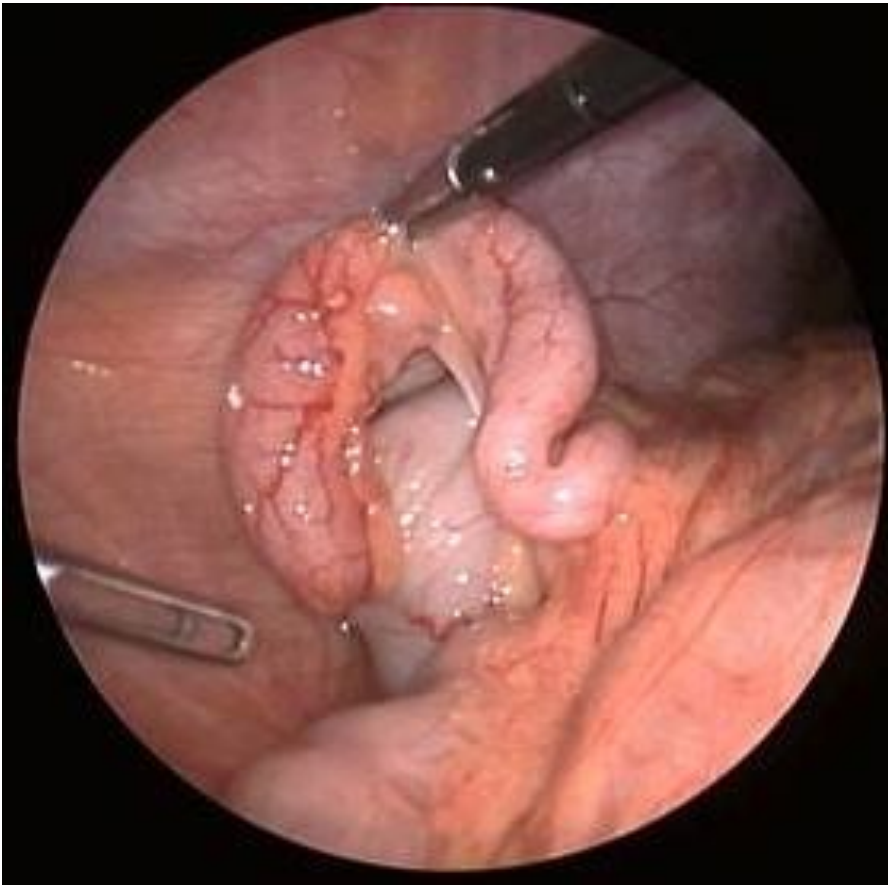36. Features of the large intestine



Features of the large intestine:

1. **Appendices epiploic**
2. **Sacculations (haustrations)**
3. **Taeniae coli**
 - The taeniae coli meet together at the base of the **appendix** where they form a complete longitudinal muscle coat for the appendix.

37. Pain of Appendicitis



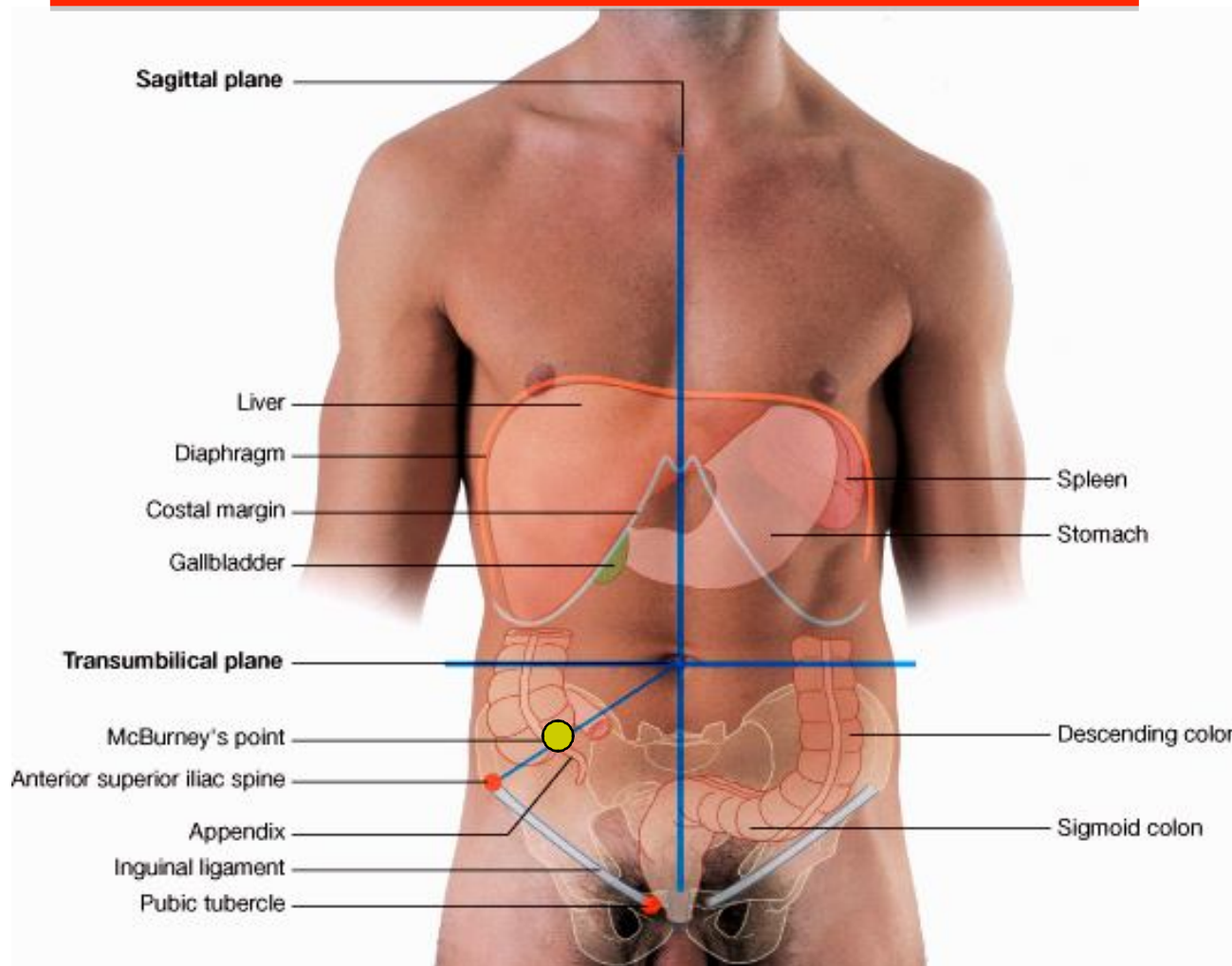
- In appendicitis, **first pain** is referred around the **umbilicus**. **Visceral pain** in the appendix is produced by distention of its lumen or spasm of its muscle.
- The afferent pain fibers enter the spinal cord at the level of **T10 segment**, and a vague referred pain is felt in the region of the umbilicus.
- Later if **parietal peritoneum** gets involved, and then the pain is shifted laterally to the **Mc Burney's point**. Here the pain is precise, severe, and localized (**second pain**)

Mc Burney's point

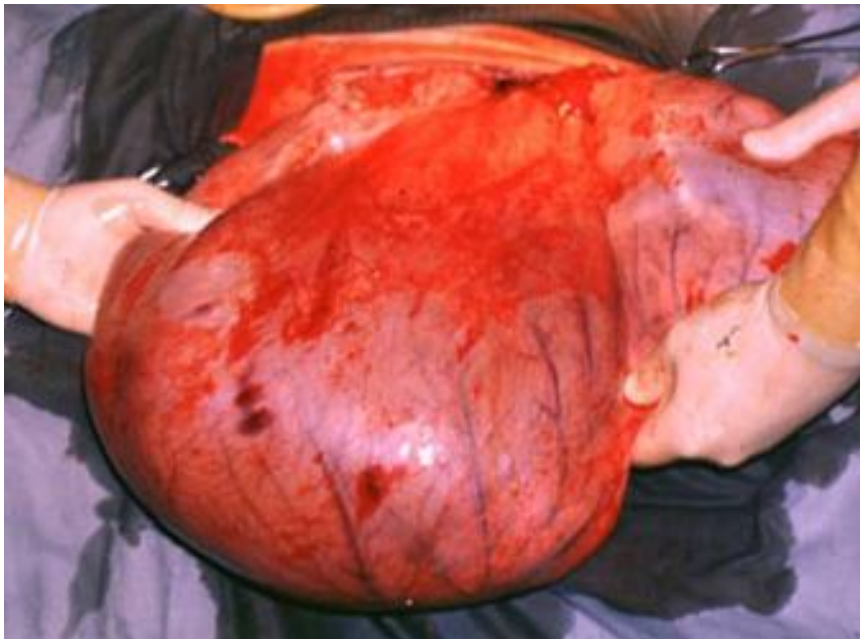

- This point indicates the surface marking of the **base of the appendix**.

It is a point at the junction between the **lateral 1/3** and **medial 2/3** of a line joining the right anterior superior **iliac spine** with the **umbilicus**.



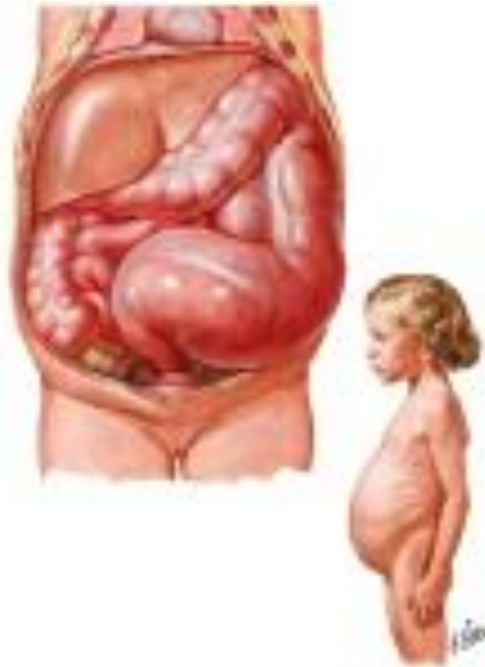38. Volvulus



- Because of its extreme mobility, the **small intestine** and **sigmoid colon** sometimes **rotates around its mesentery**.
- This may correct itself spontaneously, or the rotation may continue until the blood supply of the gut is cut off completely.

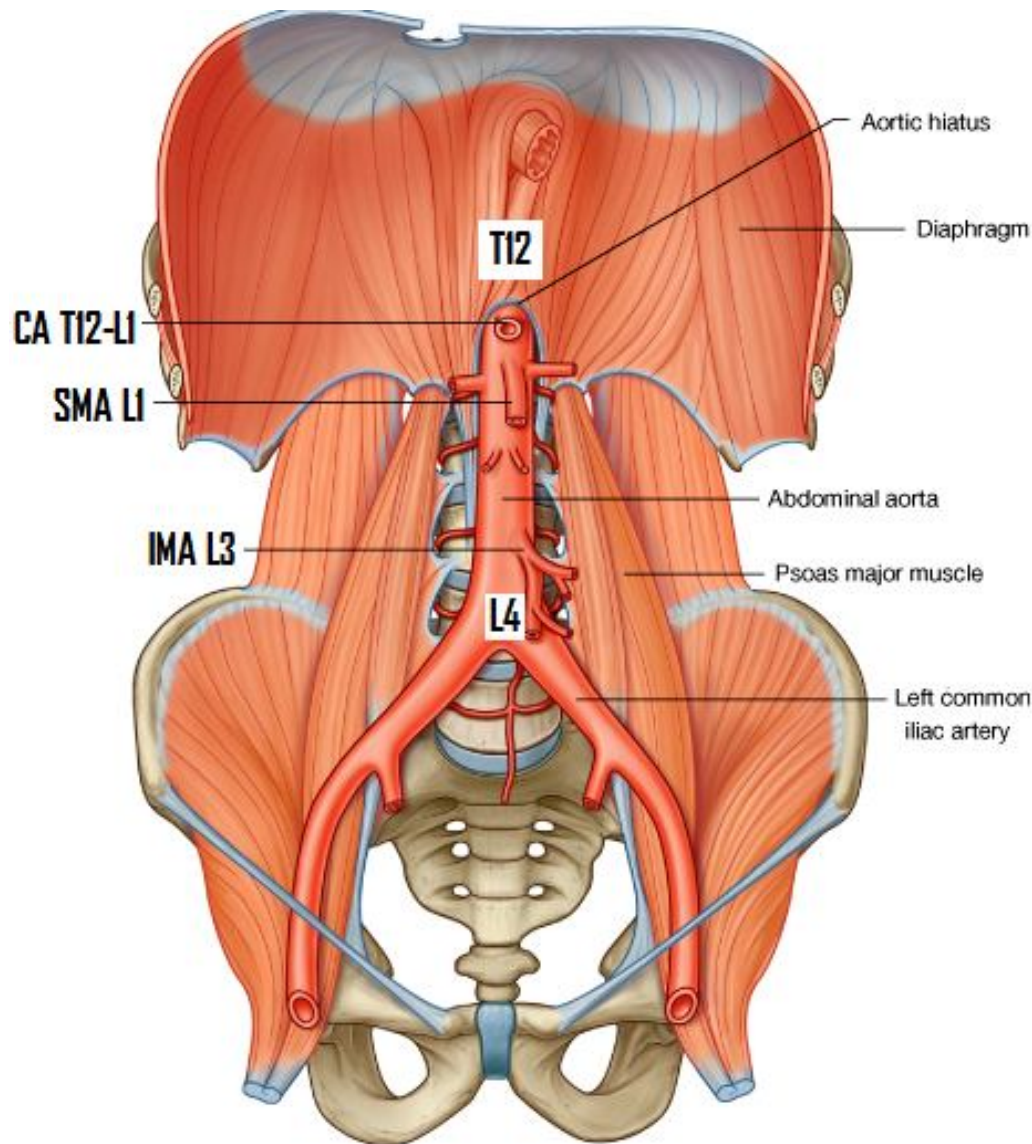


39. Hirschsprung's Disease



- It is a rare congenital abnormality that results in obstruction because the intestines **do not work normally**.
- It is commonly found in **Down Syndrome** children.
- The inadequate motility is a result of an **aganglionic section** (congenital **absents** of **postganglionic parasympathetic** neurons inside of the intestinal wall) of the intestines resulting in **megacolon**.
- In a newborn, the main signs and symptoms are **failure to pass a meconium stool** within **1-2 days** after birth, reluctance to eat, bile-stained (green) vomiting, and abdominal distension.
- Treatment is **removal** of the aganglionic portion of the colon.

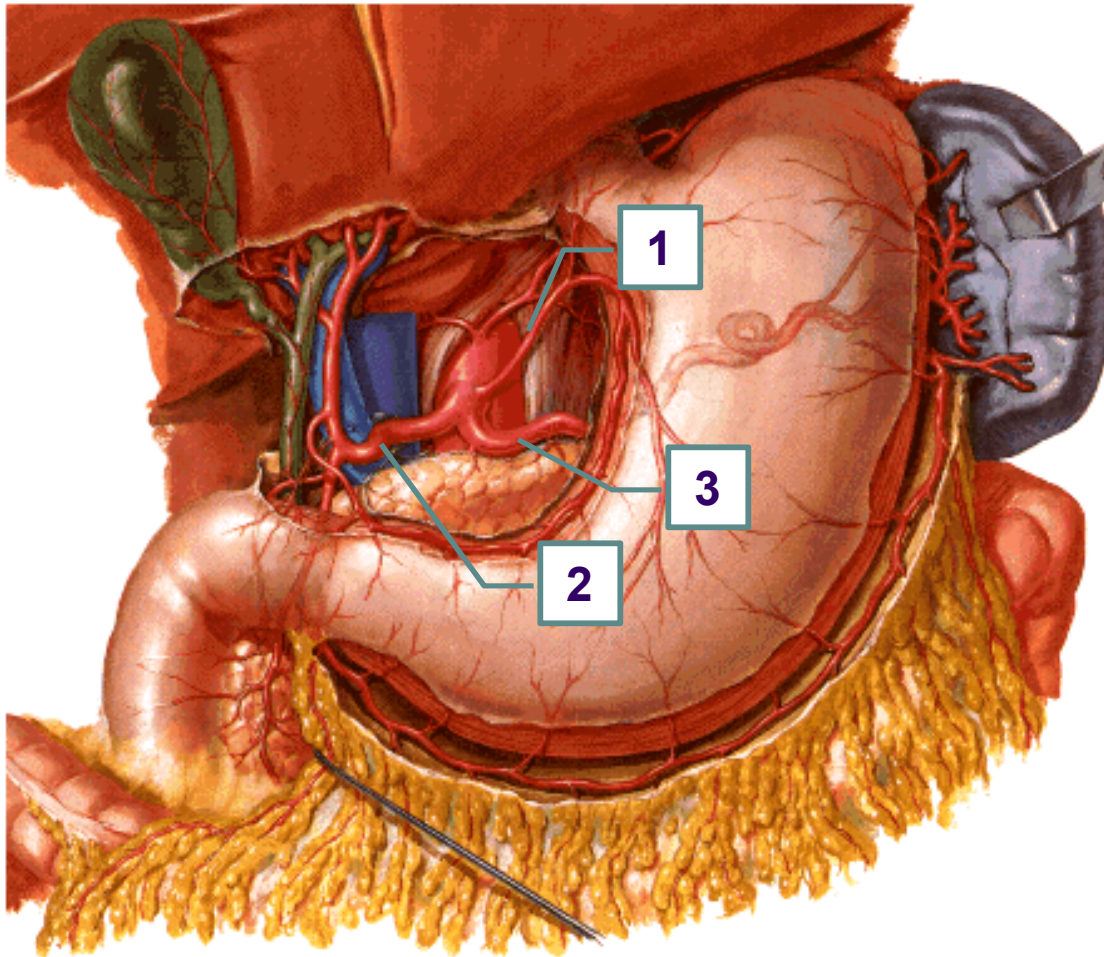
40. Branches of Abdominal aorta



- **Celiac trunk (CA)** originates from the aorta at the lower border of **T12** vertebra
- **Superior mesenteric artery** originates at the lower border of **L1** vertebra
- **Renal arteries** originate at approximately **L2** vertebra
- **Inferior mesenteric artery** originates at **L3** vertebra
- Two terminal branches are **common iliac arteries** at the level of **L4** vertebra

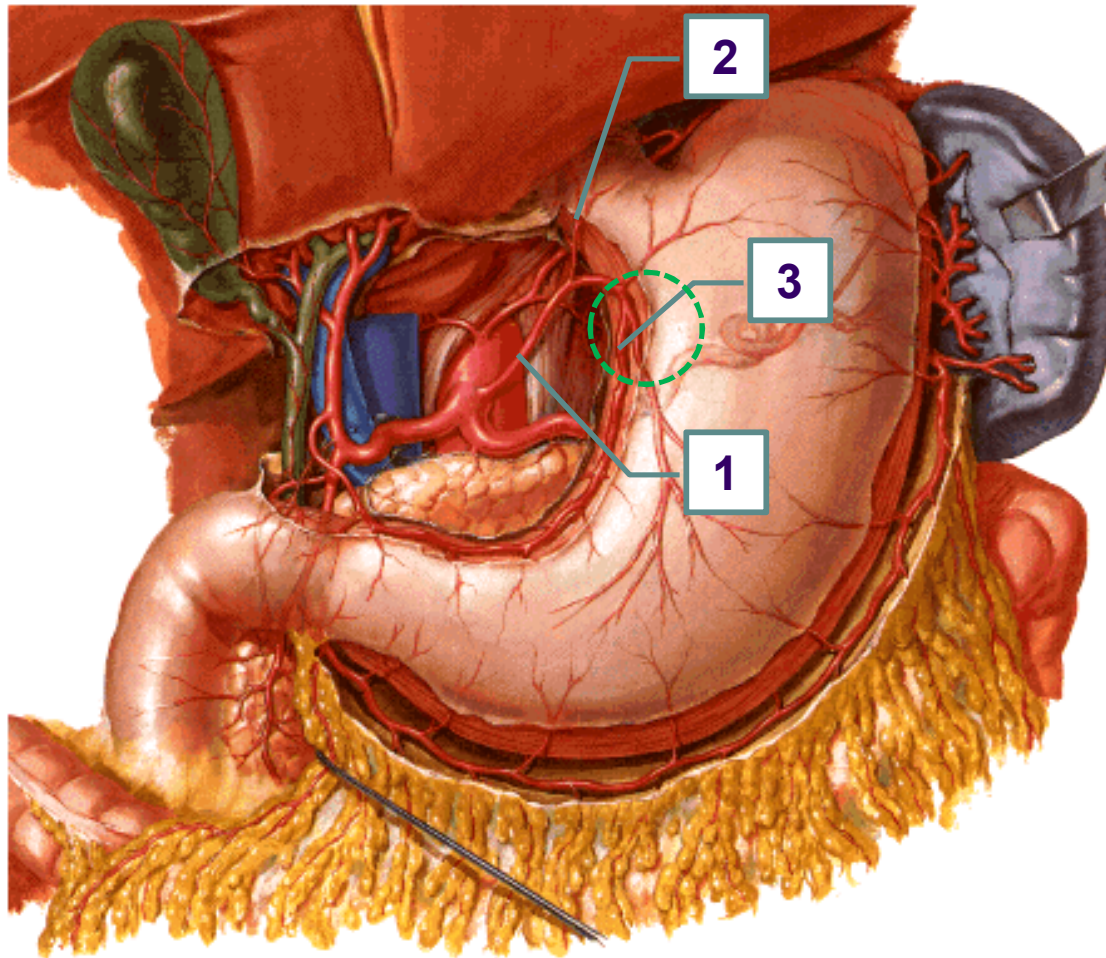


CELIAC ARTERY (TRUNK)



- **Origin:** T12-L1, just below the aortic opening of the diaphragm.
- The CA passes above the superior border of the pancreas and then divides into three retroperitoneal branches:
- **Left gastric artery (1)**
- **Common hepatic artery (2)**
- **Splenic artery (3)**

Left gastric artery



L gastric - cardia portion
R gastric - fundal portion

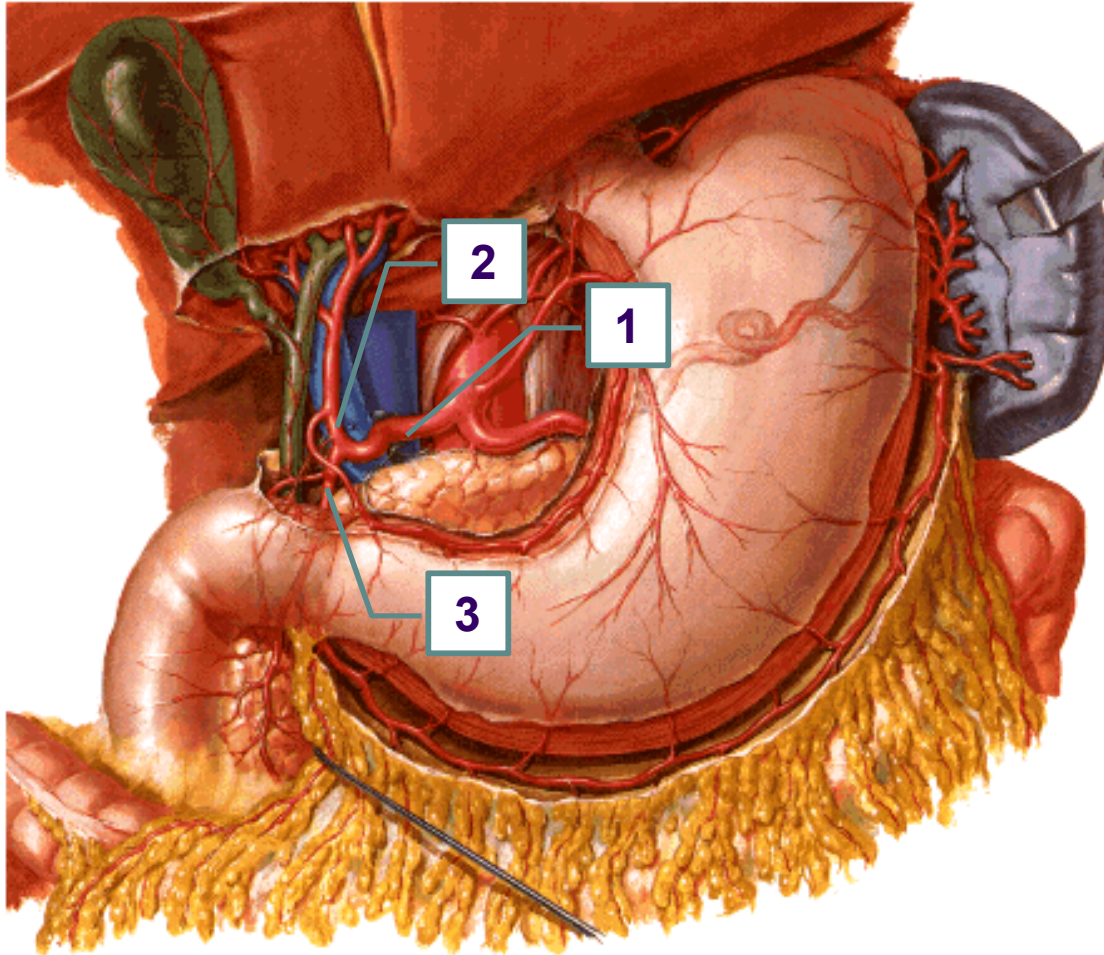


- The **left gastric artery (1)** courses upward to the left to reach the lesser curvature of the stomach and may be subject to erosion by a **penetrating ulcer** of the **lesser curvature** of the **stomach**.

Branches:

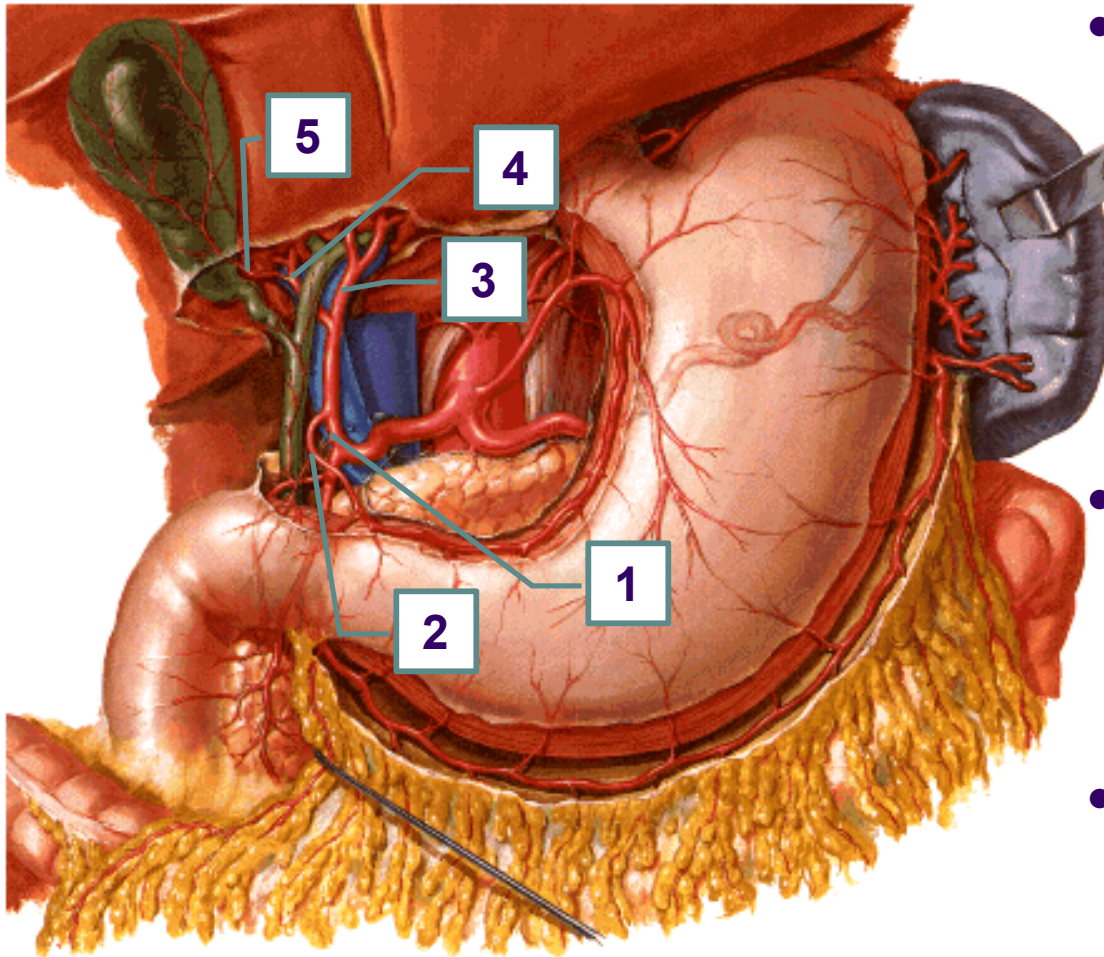
- **Esophageal branches (2)** - to the abdominal part of the **esophagus**
- **Gastric branches (3)** supply the left side of the **lesser curvature** of the stomach and make **anastomosis** with **right gastric artery**.

Common hepatic artery



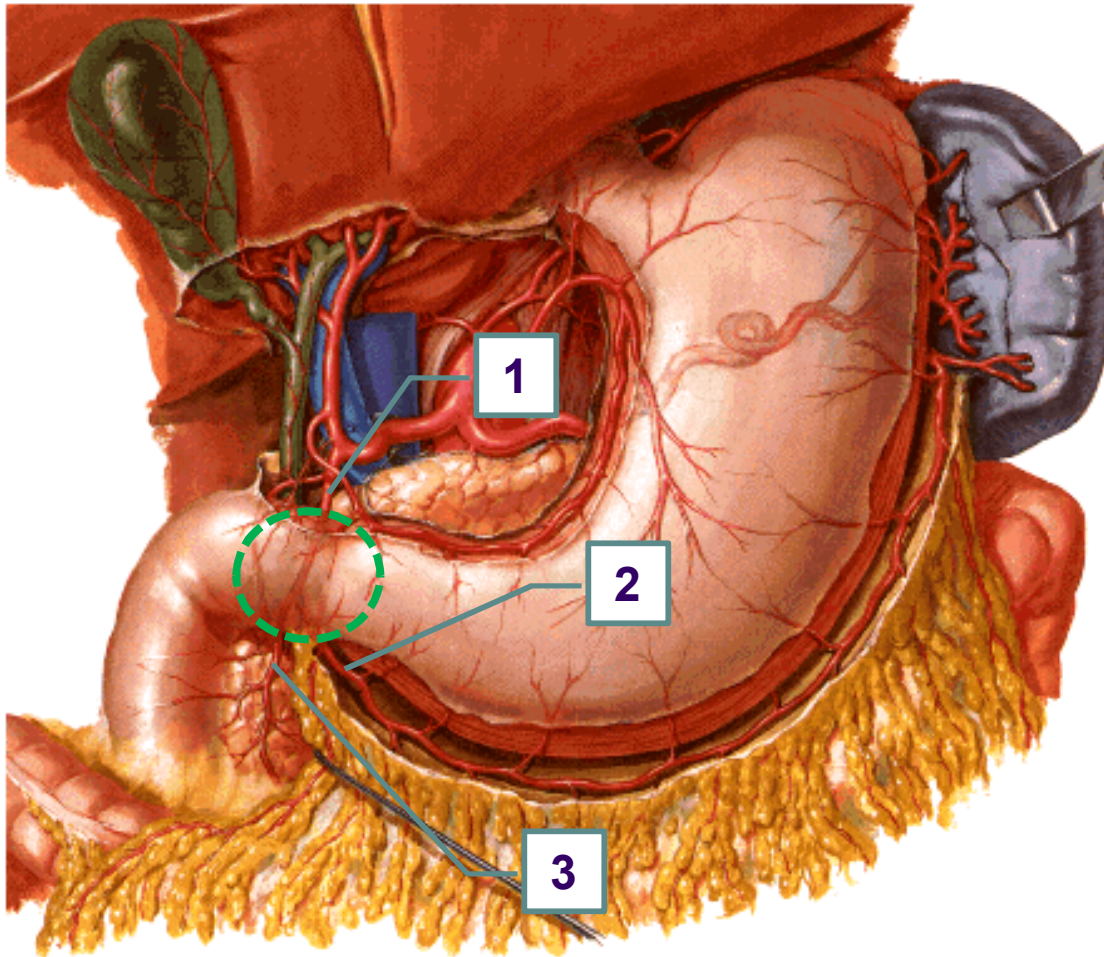
- The **common hepatic artery (1)** passes to the right to reach the superior surface of the first part of the duodenum, where it divides into its two terminal branches:
- **Proper hepatic artery (2)**
- **Gastroduodenal artery (3)**

Proper hepatic artery



- **Proper hepatic artery (1)** gives off **right gastric artery (2)** and then ascends within the **hepatoduodenal** ligament of the **lesser omentum** to reach the **porta hepatis**, where it divides into the **right (4)** and **left (3) hepatic arteries**.
- The right and left arteries enter the two **lobes of the liver**, with the right hepatic artery first giving rise to the **cystic artery (5)** to the **gallbladder**.
- **Right gastric artery (2)** supplies the right side of the **lesser curvature** of the stomach where it anastomoses the **left gastric artery**.

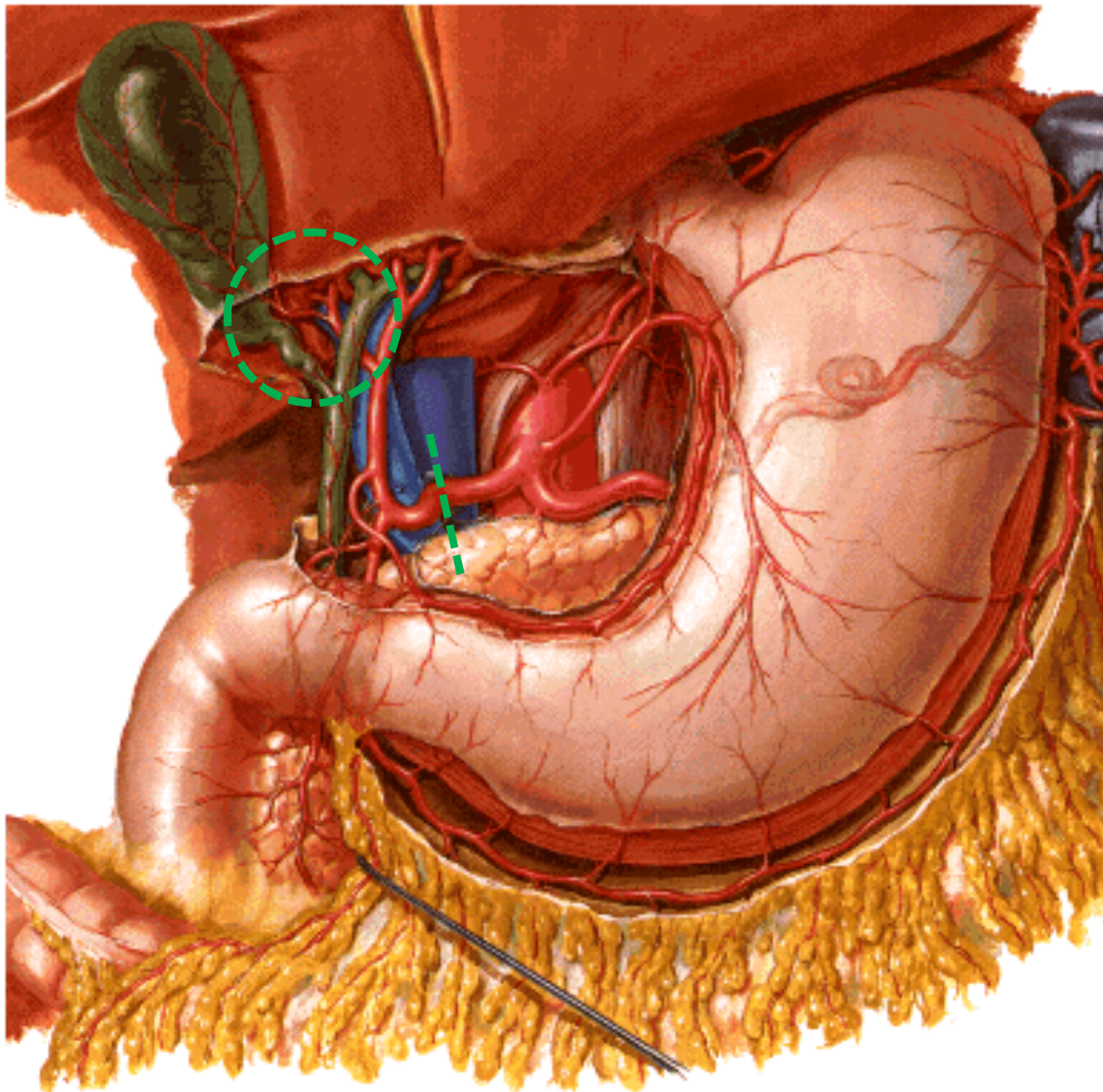
Gastroduodenal artery



- **Gastroduodenal artery (1)** descends **posterior** to the **first part** of the **duodenum** (may be subject to **erosion by a penetrating ulcer** in this place) and divides into two branches:
- **Right gastroepiploic artery (2)** (supplies the right side of the **greater curvature** of the stomach where it **anastomoses** the **left gastroepiploic**)
- **Superior pancreaticoduodenal arteries (3)** (supplies the **head** of the **pancreas**, where it **anastomoses** the **inferior pancreaticoduodenal branches** of the **SMA**).

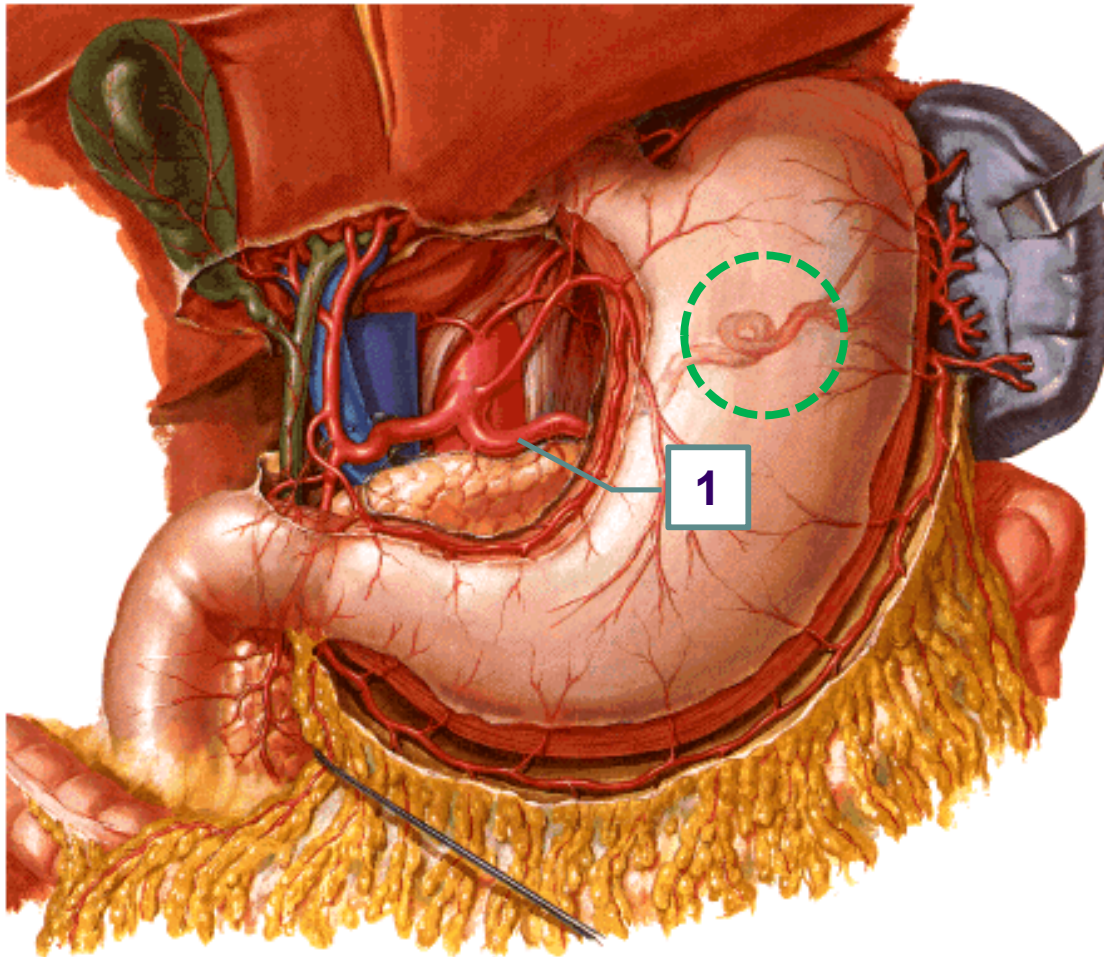


Ligature of the hepatic artery:



- The **hepatic artery** may be ligated proximal to the origin of its gastroduodenal branch, a **collateral circulation** to the liver is established through the **left and right gastric arteries**, **left and right gastroepiploic** and **gastroduodenal arteries**.
- The **right hepatic artery** may be **mistakenly ligated** during **cholecystectomy** in **Calot** triangle together with the **cystic artery**, **right lobe hepatic necrosis** commonly occurs.

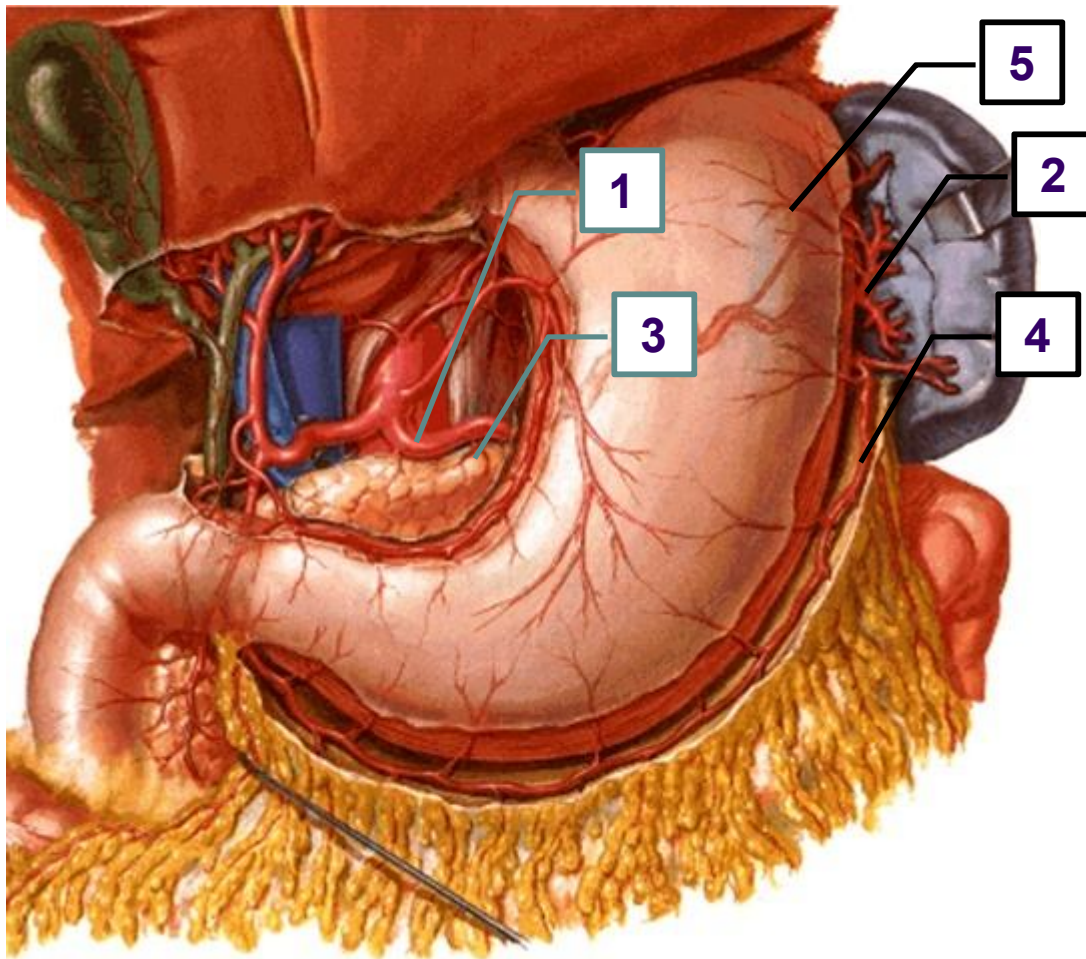
Splenic artery



- **Splenic artery (1)** runs a tortuous horizontal course to the left along the **upper border of the pancreas**, behind the **peritoneum** of the posterior wall of the **lesser sac**, forming a part of the **stomach bed**.
- The splenic artery may be subject to **erosion** by a **penetrating ulcer** of the posterior wall of the **stomach** into the lesser sac.
- **N.B.** The **splenic vein** runs a more **straight** course below the artery and **behind of the pancreas**.



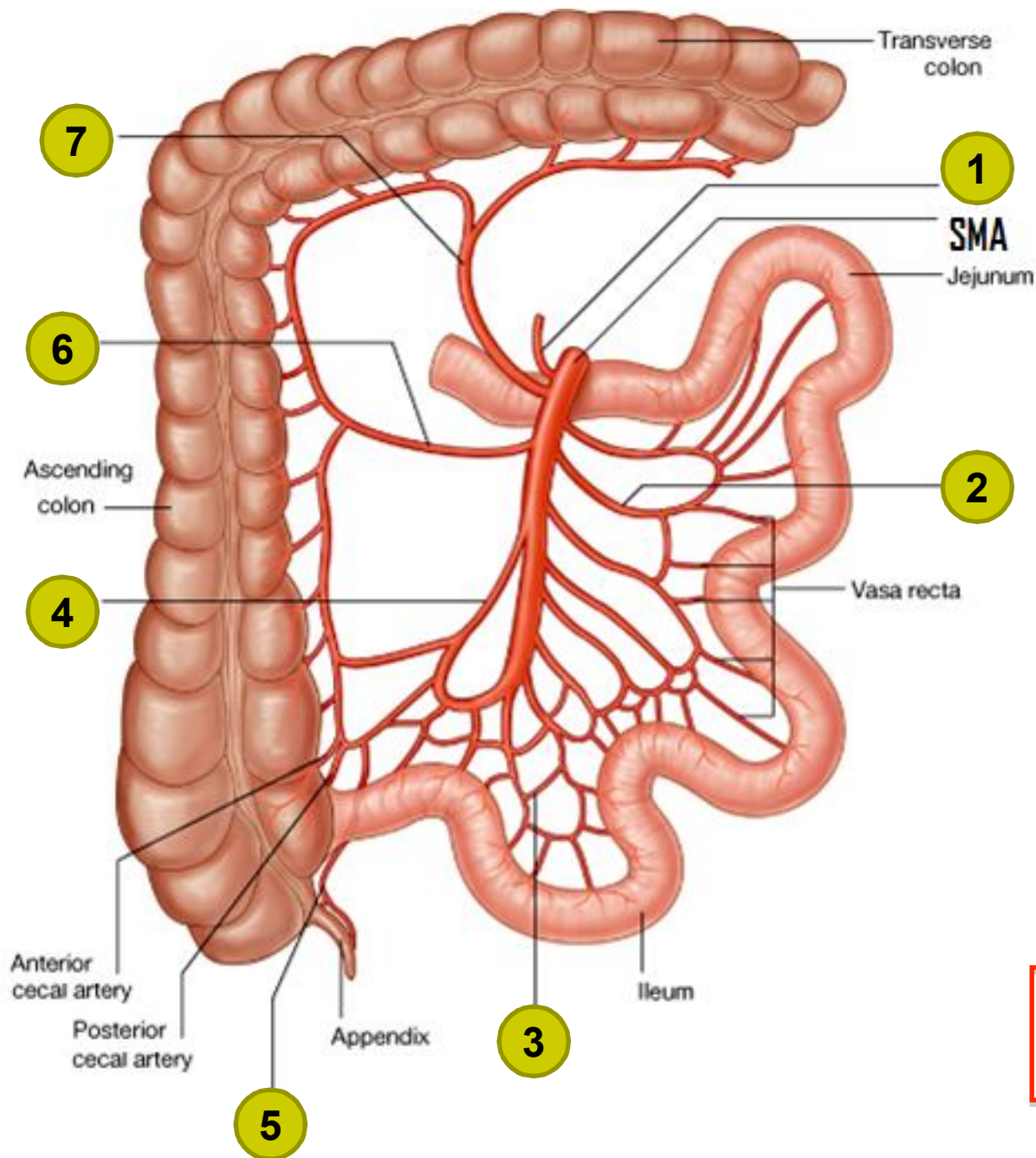
Splenic artery



- **Splenic (1) a.** is retroperitoneal until it reaches the **tail** of the **pancreas**, where it enters the **splenorenal ligament** to enter the hilum of the **spleen**.

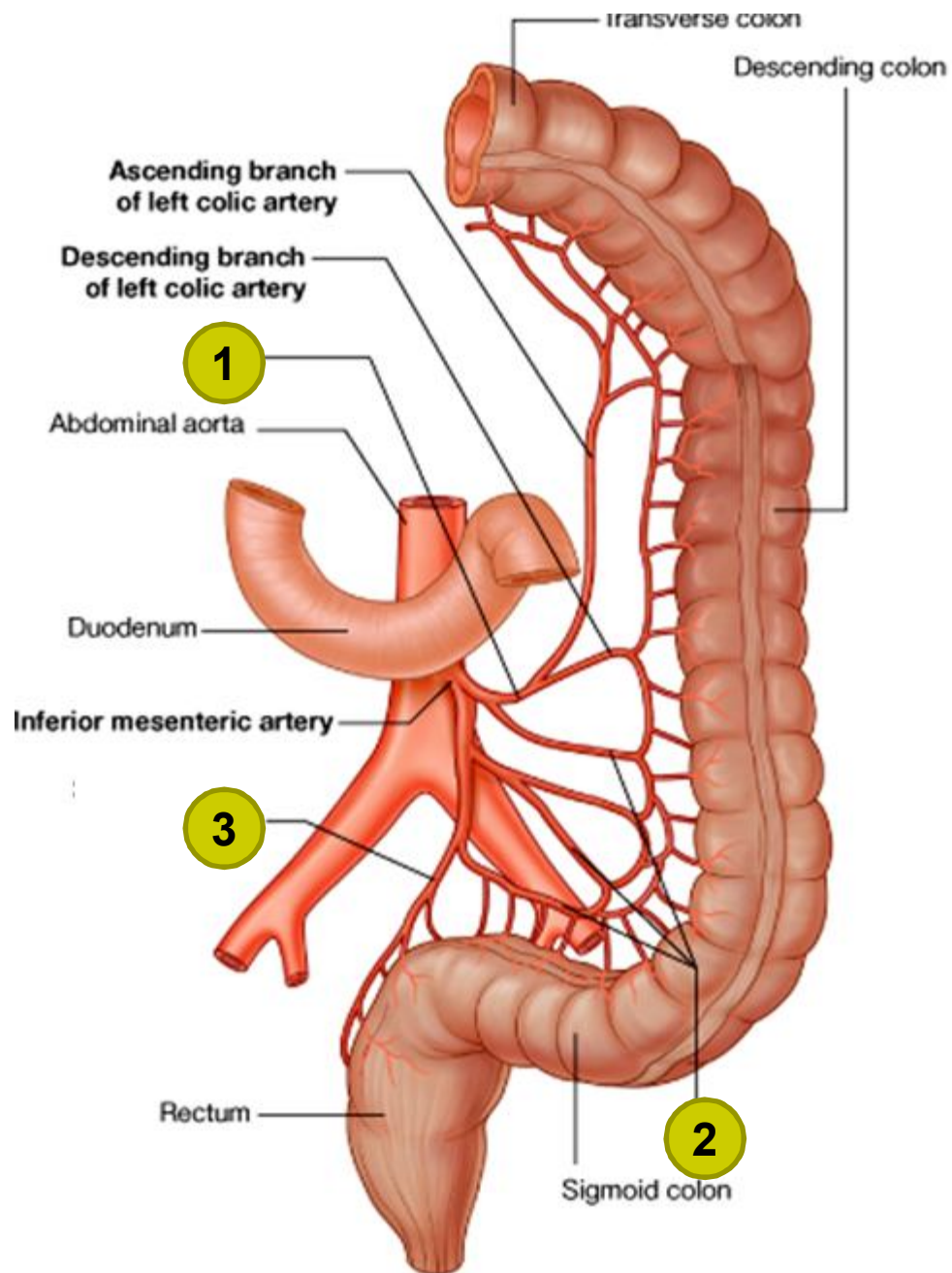
Branches:

- Branches to the **spleen (2)**
- Branches to the **neck, body, and tail of pancreas (3)**
- **Left gastroepiploic (4)** artery that supplies the left side of the **greater** curvature of the stomach where it **anastomoses** the **right gastroepiploic**
- **Short gastric (5)** branches that supply to the **fundus** of the **stomach**



SMA Branches:

- (1) Inferior pancreaticoduodenal arteries
- (2) Jejunal and (3) Ileal branches
- (4) Ileocolic artery
 - Ascending branch
 - Anterior cecal artery
 - Posterior cecal artery
 - (5) Appendicular artery
- (6) Right colic artery
- (7) Middle colic artery



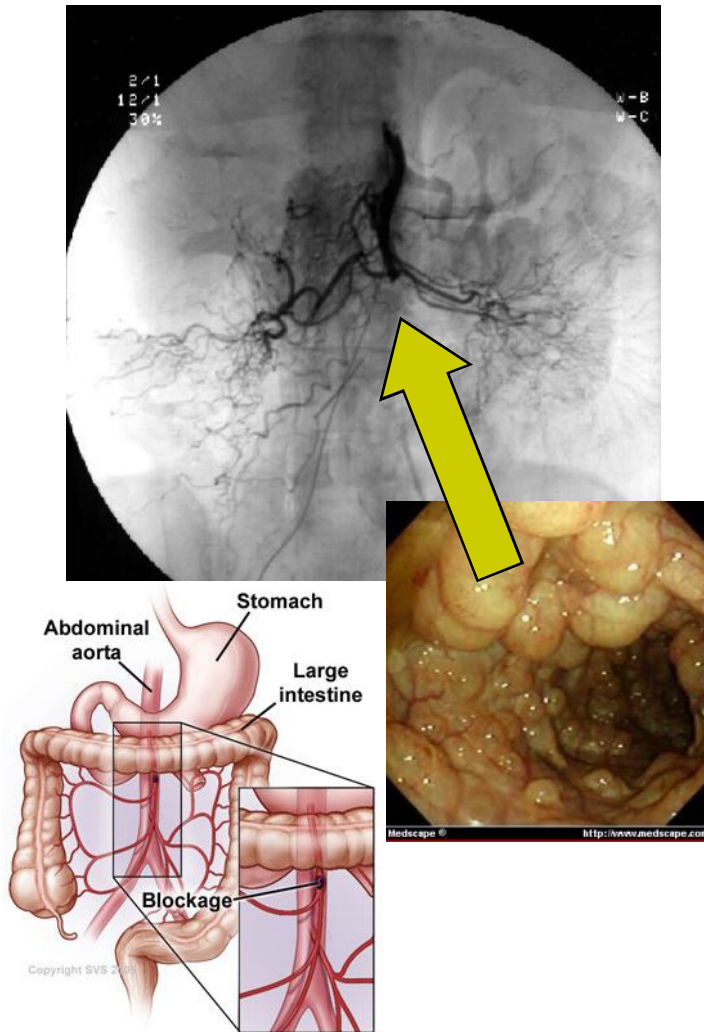
IMA Branches:

- (1) Left colic artery
- (2) Sigmoid arteries
- (3) Superior rectal artery

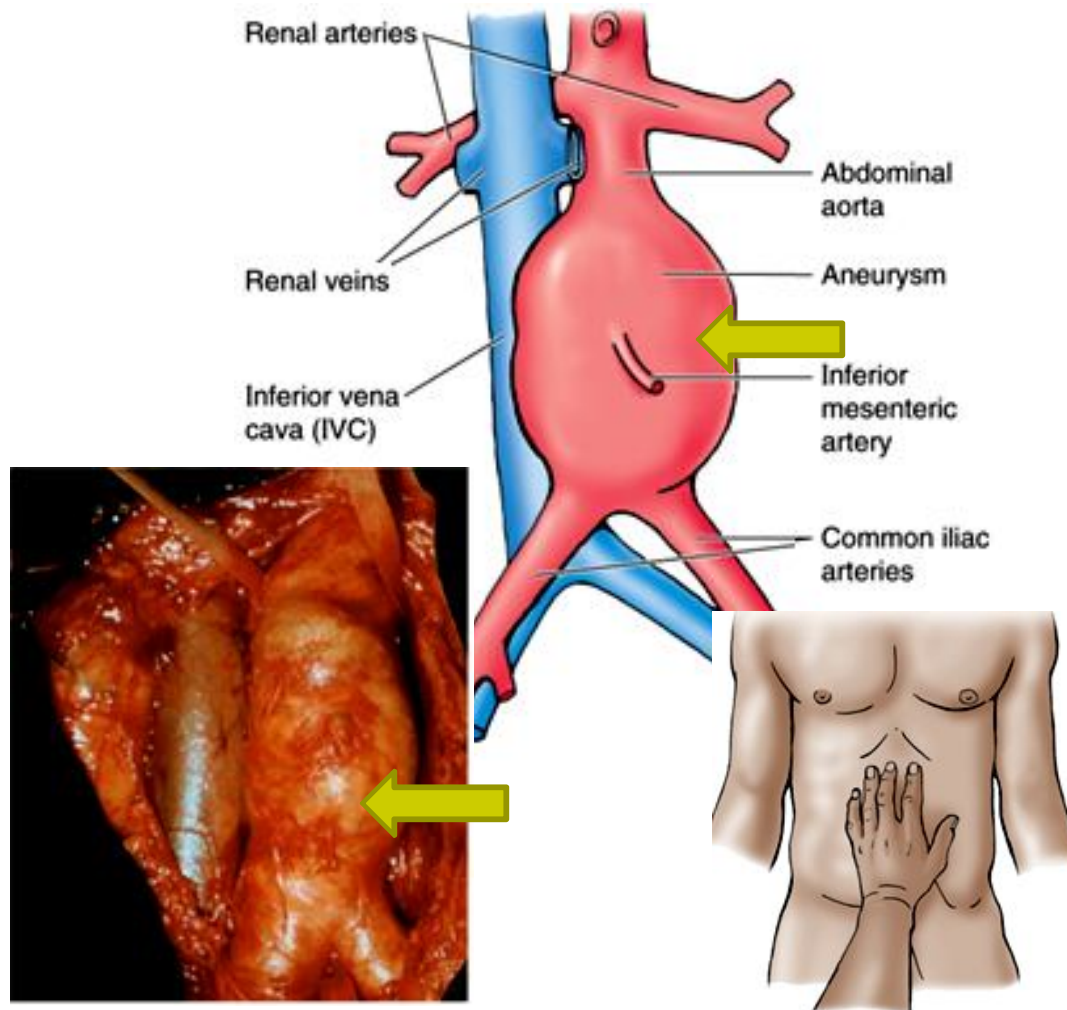


41. Mesenteric ischemia

- Ischemia occurs when your blood cannot flow through arteries as well as it should, and intestines do not receive the necessary oxygen to perform normally. Mesenteric ischemia usually involves the **small intestine**.
- Mesenteric ischemia usually occurs in **people older than age 60**. You may be more likely to experience mesenteric ischemia if you are a **smoker** or have a **high cholesterol** level.
- **Atherosclerosis**, which slows the amount blood flowing through arteries, is a frequent cause of chronic mesenteric ischemia.



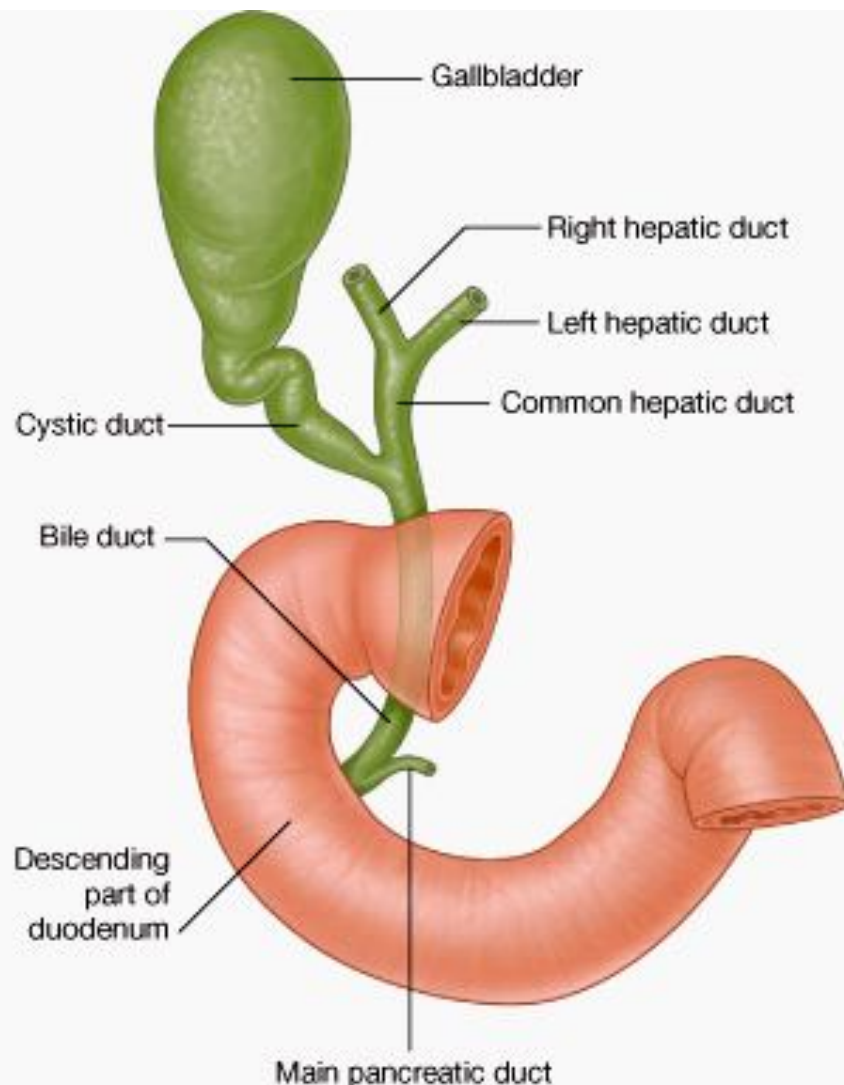
42. Abdominal aortic aneurysm



- It is a localized **dilatation** of the aorta. It is typically happened just above of the **bifurcation** at level of **L4** and crossed by **3rd part of duodenum**.
- Pulsations of a large aneurysm can be detected to the **left of the midline** at the **umbilical region**.
- **Acute rupture** of an abdominal aortic aneurysm is associated with severe pain in the abdomen or back (mortality rate is nearly **90%**).
- Surgeons can repair an aneurysm by opening it and inserting a **prosthetic graft**.

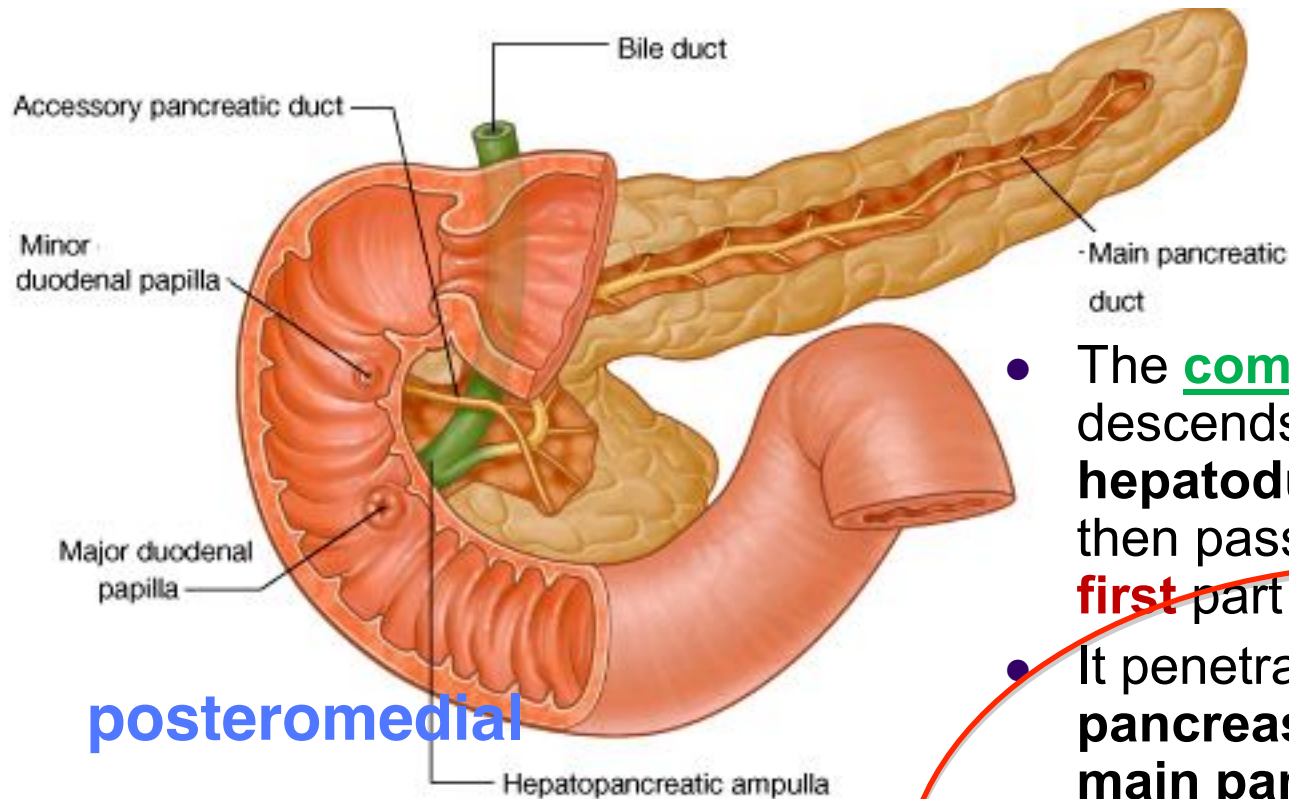


43. Biliary system



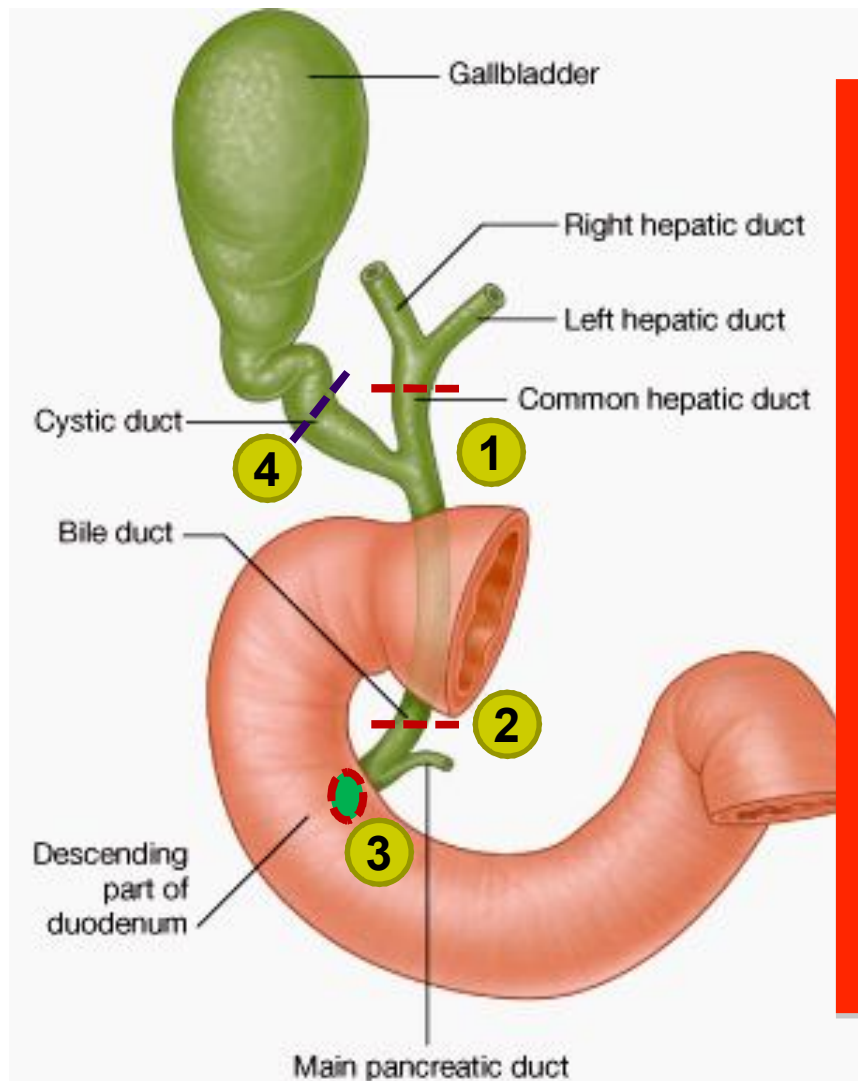
- Bile is secreted by the **liver** cells, stored, and concentrated in the **gallbladder** and later it is delivered to the **duodenum**.
- The **gallbladder** lies in a fossa on the visceral surface of the liver to the right of the quadrate lobe.
- It stores and concentrates bile, which **enters and leaves** through the **cystic duct**.
- The cystic duct joins the **common hepatic (from left and right hepatic)** due to form the **common bile duct**.

Biliary system



- The common bile duct descends in the **hepatoduodenal ligament**, then passes **posterior** to the **first** part of the **duodenum**
- It penetrates the head of the **pancreas** where it **joins the main pancreatic duct** and forms the **hepatopancreatic ampulla (sphincter of Oddi)**, which drains into the **second** part of the **duodenum** at the **major duodenal papilla**.

44. Cholelithiasis (gallstones)

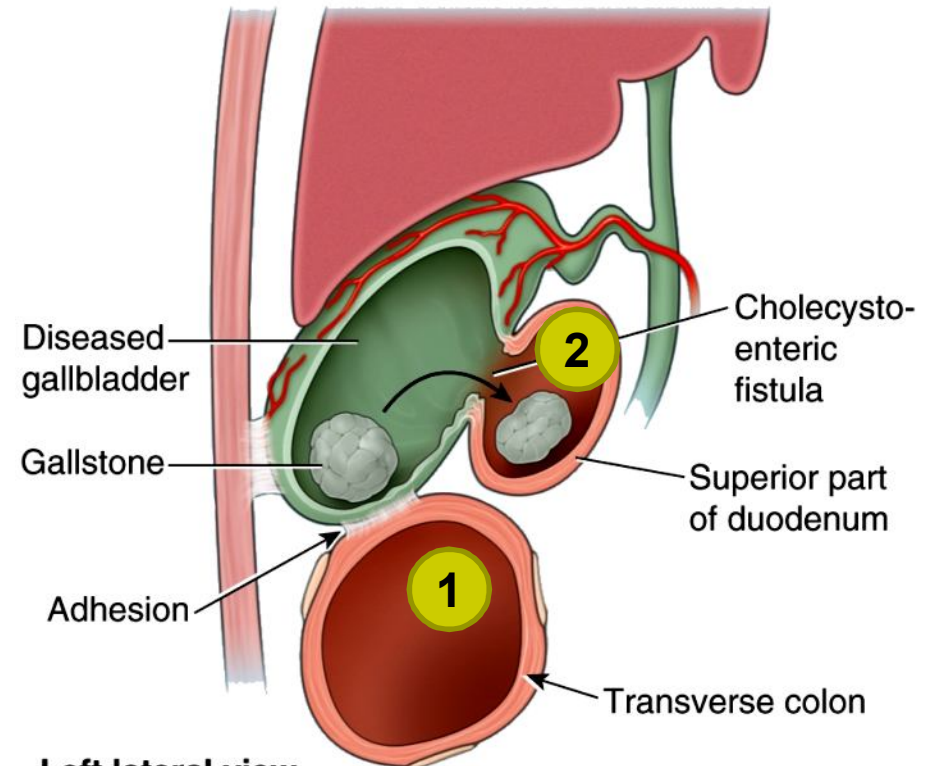


- The distal end of the hepatopancreatic ampulla is the narrowest part of the biliary passages and is the **common site for impaction of gallstones**. As result of common hepatic (1), bile duct (2), or hepatopancreatic ampulla (3) obstruction patient **will have yellow eyes and jaundice**
- Gallstones may also lodge in the **cystic duct**. A stone lodged in the cystic duct (4) causes **biliary colic** (intense, spasmodic pain in the gallbladder) but **doesn't produce jaundice**.

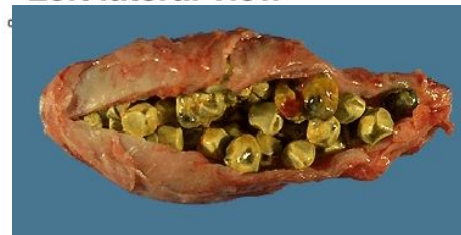

Gallstones

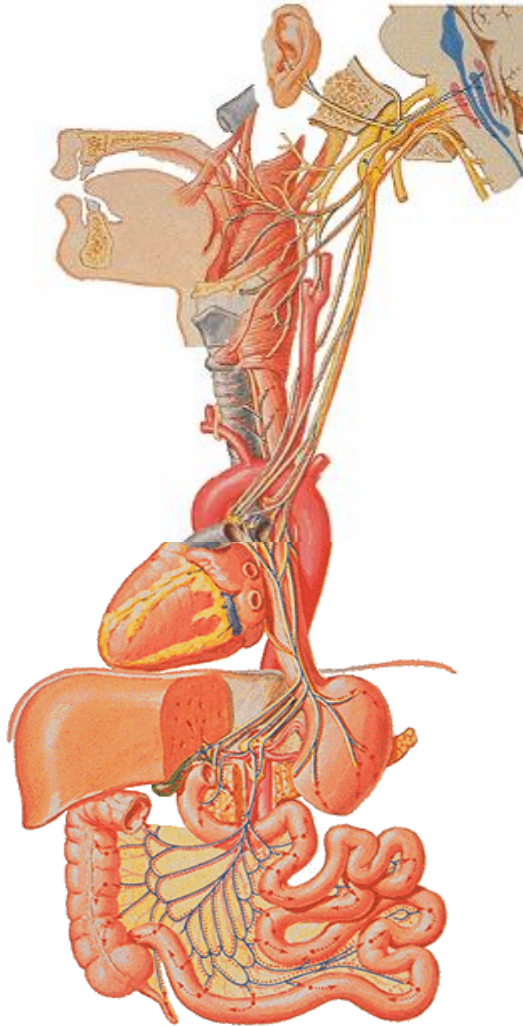
- The **fundus (1)** of the gallbladder is in contact with the **transverse colon** and thus gallstones erode through the posterior wall of the gallbladder and enter the transverse colon. They are passed naturally to the rectum through the descending colon and sigmoid colon.
- Gallstones lodged in the **body (2)** of the **gallbladder** may ulcerate through the posterior wall of the body of the gallbladder into the **duodenum** (because the gallbladder body is in contact with the duodenum) and may be held up at the ileocecal junction, producing an **intestinal obstruction**.



Left lateral view

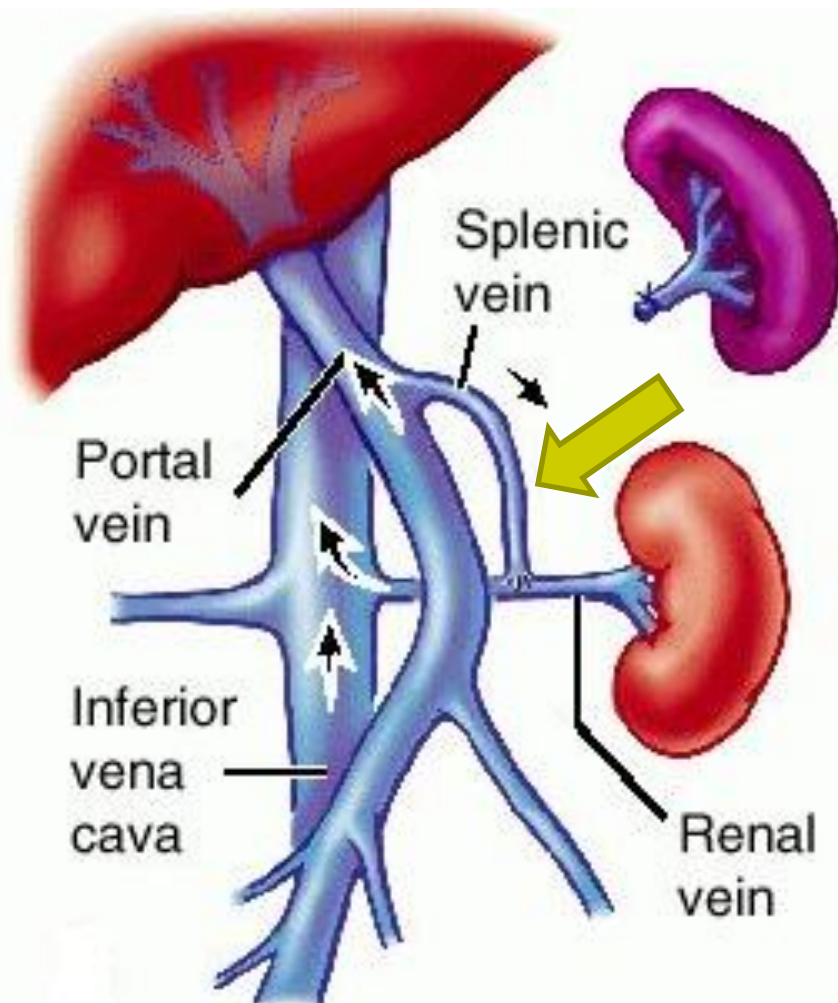


45. Nerve supply of the liver and gallbladder



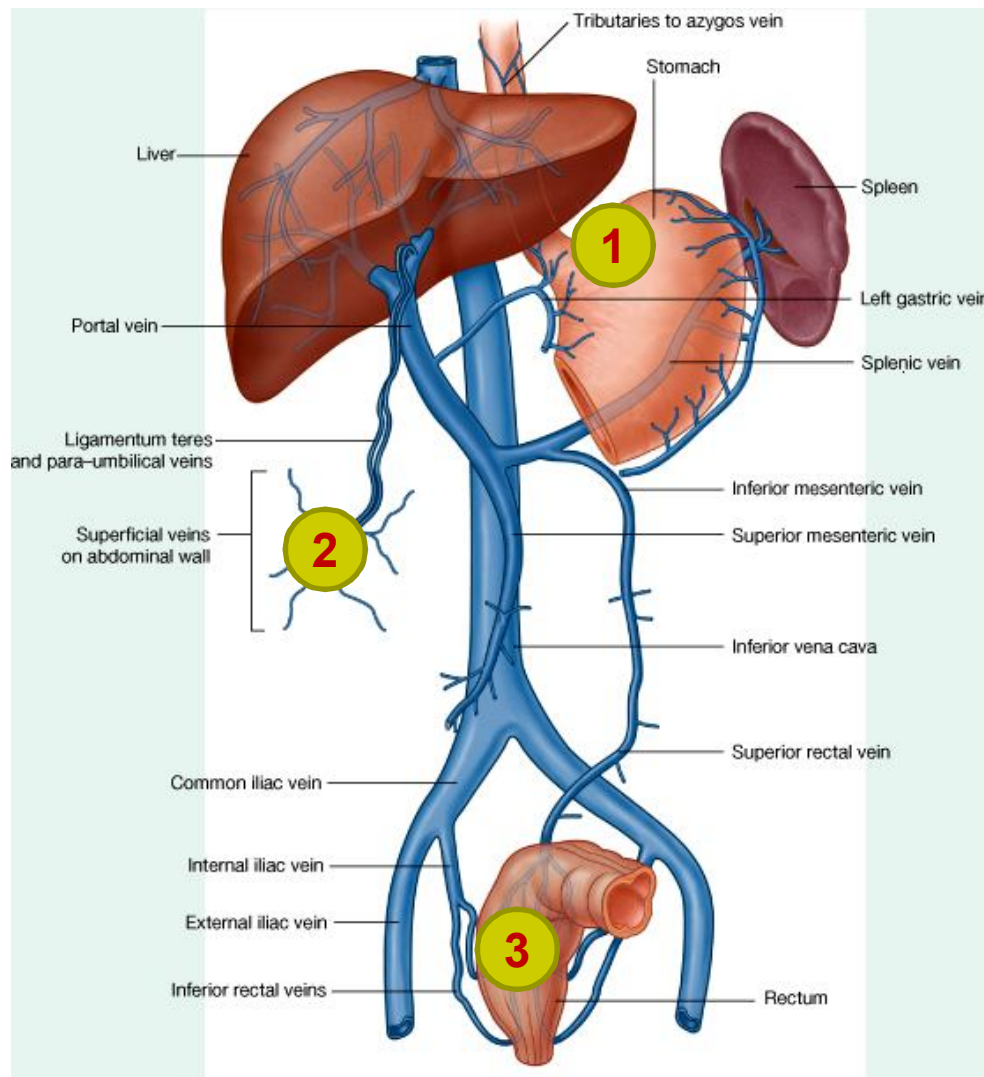
- **Sensory innervation** of the liver is done by the **right phrenic nerve** (C3-C5). **Pain may radiate to the right shoulder.**
- The **liver** receives **parasympathetic innervation** from the **vagi nerves** (CNX), reaching it through the **celiac plexuses** around the supplying arteries. The preganglionic fibers synapse on the cells of the **uxtaramural plexuses** in hilum of the liver and shot **postganglionic fibers** supply organs.
- **Sympathetic fibers** of **preganglionic neurons** **T5-T9** segments (**IML**) come through the sympathetic trunk and form **greater splanchnic nerves**. They contribute to the **celiac plexus**, where **postganglionic neurons** are located. Branches of celiac plexus reach the liver wrapping around the branches of the celiac artery.

46. Portal Hypertension



- **Portal hypertension** is a common clinical condition, and for this reason the list of portal-systemic anastomoses should be remembered. Enlargement of the portal-systemic connections is frequently accompanied by congestive enlargement of the spleen.
- **Portacaval shunt** for the treatment of portal hypertension: the **splenic vein** may be anastomoses to the **left renal vein after removing the spleen**.

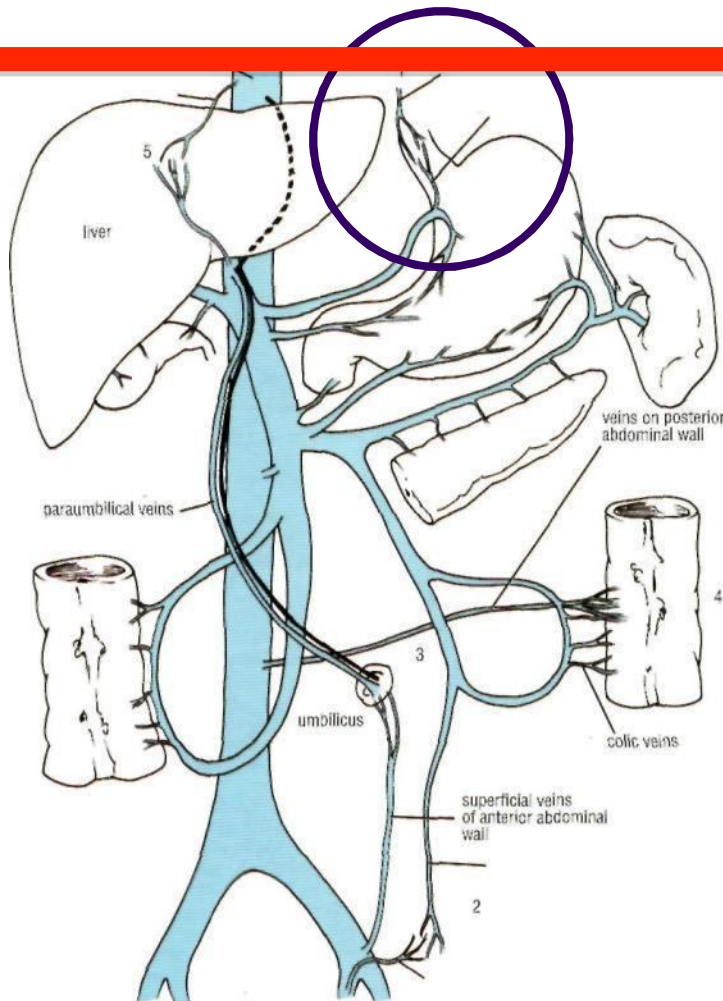
Portocaval anastomosis



© Elsevier. Drake et al: Gray's Anatomy for Students - www.studentconsult.com

- If there is an **obstruction to flow** through the portal system (**portal hypertension**), blood can flow in a **retrograde direction** (because of the absence of valves in the portal system) and pass through **anastomoses** to reach the **caval system**.
- Sites for these anastomoses include the (1) **esophageal veins**, (2) **thoracoepigastric veins**, and (3) **rectal veins**.
- Enlargement of these veins may result in (1) **esophageal varices**, (2) a **caput medusae** and (3) **internal hemorrhoids**.

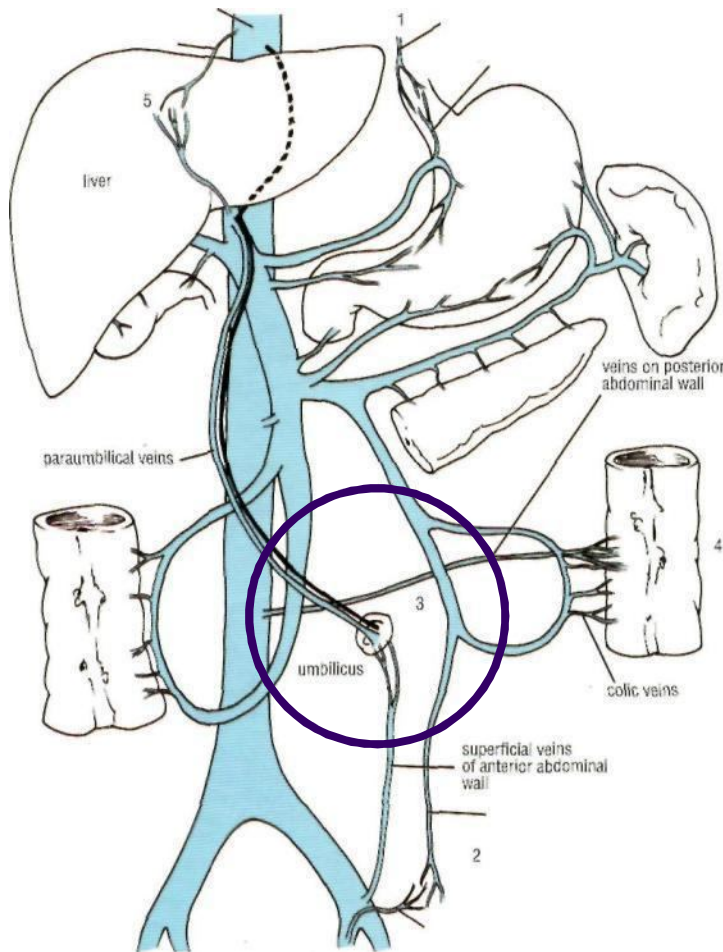
Esophageal anastomosis



- **Anastomosis** between the tributaries of the **left gastric vein** (portal vein) and the tributaries of the **azygous vein** (SVC) in the wall of the **lower end of the esophagus**.
- In portal hypertension these anastomoses veins enlarge in the wall of the **esophagus** and later burst into the lumen of the esophagus (**esophageal varices**) resulting in **hematemesis** (vomiting red blood).

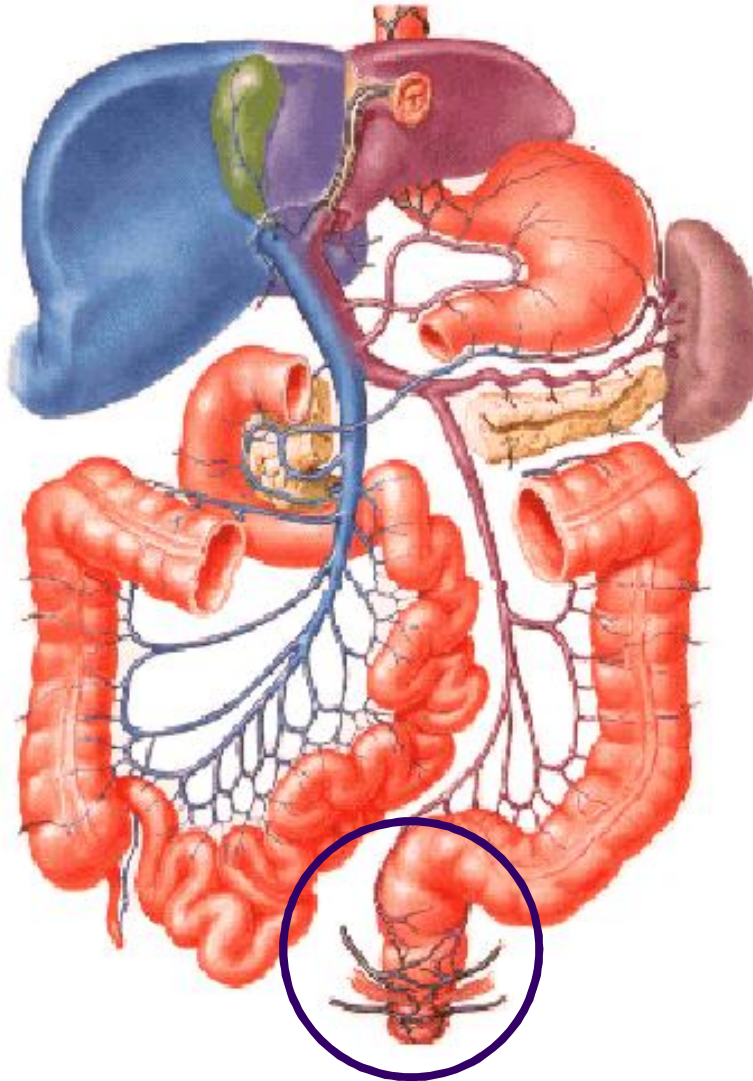


Umbilical anastomosis



- Anastomosis between the **paraumbilical vein** (portal vein) and the **superior** and **inferior epigastric** veins (**SVC** and **IVC**) of the anterior abdominal wall around the **umbilicus**.
- In portal hypertension, this anastomosis gets enlarged and dilated veins form “**caput Medusae**” around the **umbilicus**.

Rectal anastomosis



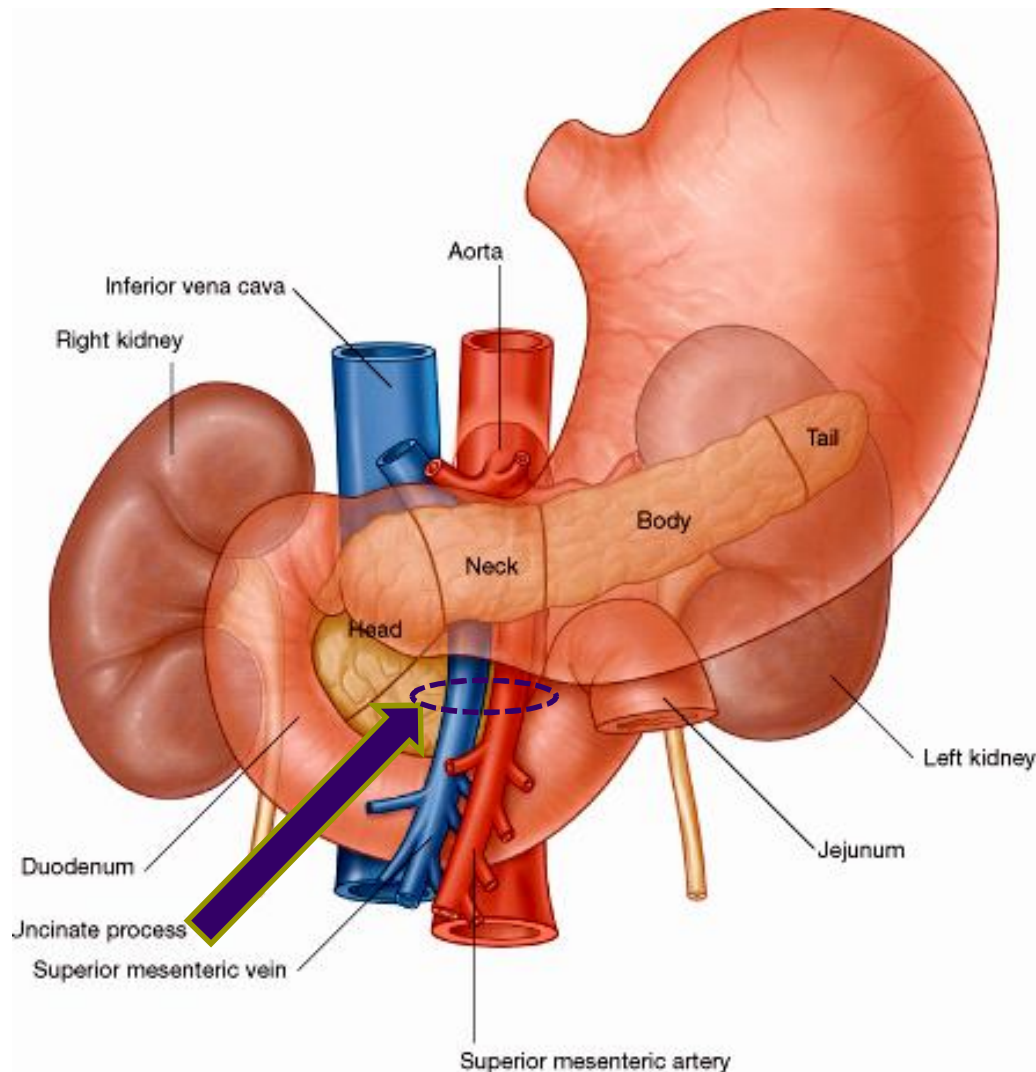
- Anastomosis between the **superior rectal vein** (inferior mesenteric vein and then into **portal vein**) and **inferior rectal vein** which drains into the internal iliac vein (from **IVC** system).
- In portal hypertension this anastomoses gets dilated resulting in **internal hemorrhoids** and bleeding per anus.

47. Pancreas: Head and uncinate process

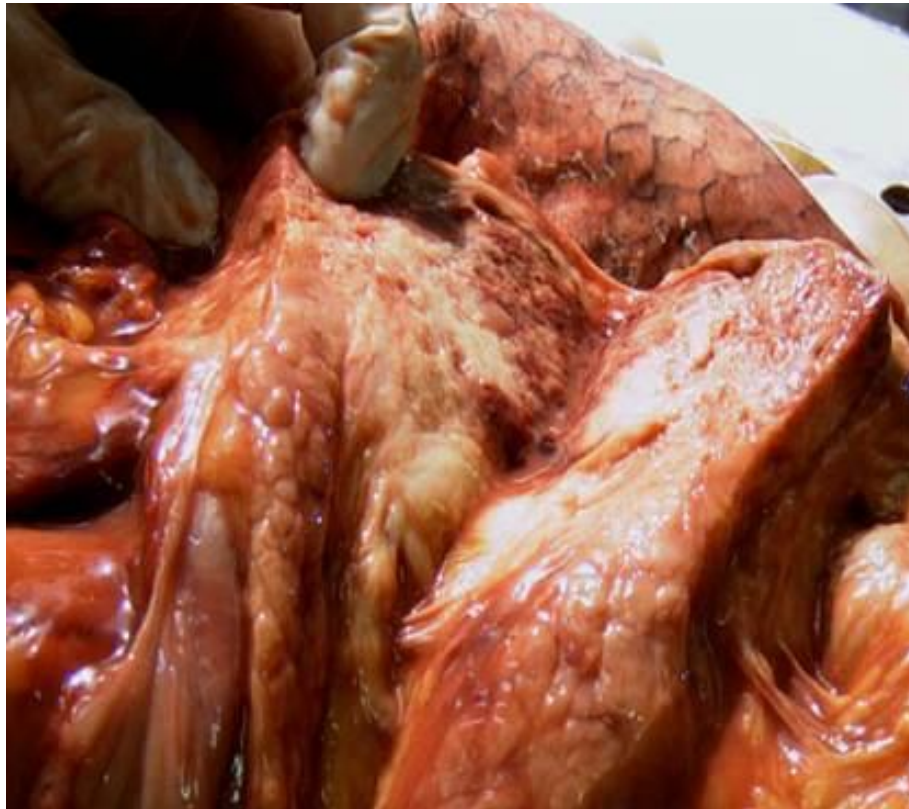

The **head of the pancreas** rests within the **C-shaped area formed by the duodenum** and is traversed by the **common bile duct**.

It includes the **uncinate process** which is crossed by the **superior mesenteric vessels**.



Cancer of the head of the pancreas

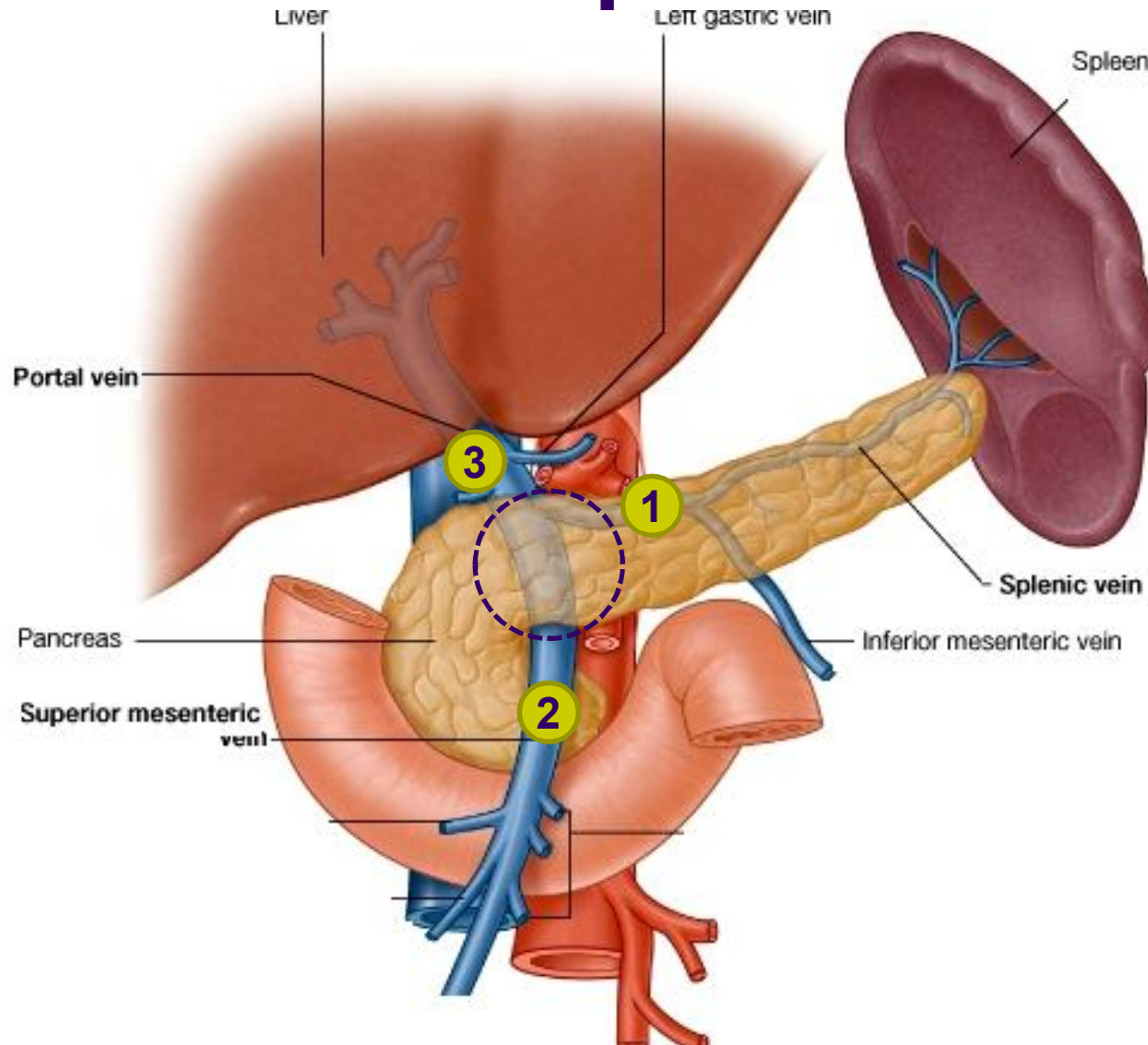


Cancer of the head of the pancreas compresses the bile duct and it results in **OBSTRUCTIVE TYPE OF JAUNDICE.**

- This type of jaundice is **NOT** usually **associated with** pain or **fever**.
- **Hepatitis** also causes jaundice but is **associated with** the **fever**.



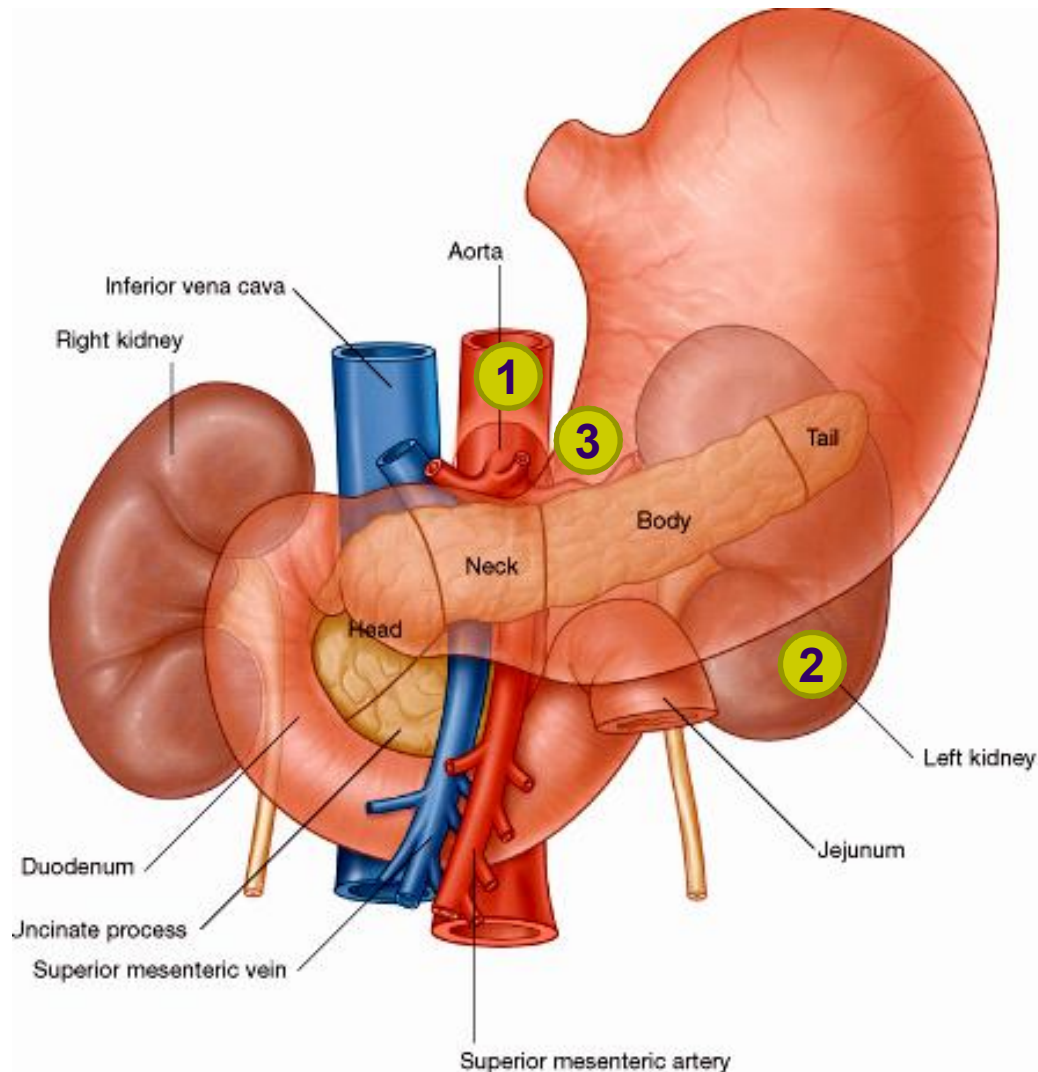
Neck of the pancreas



Posterior to the **neck** of the pancreas is the site of formation of the **PORTAL VEIN**.

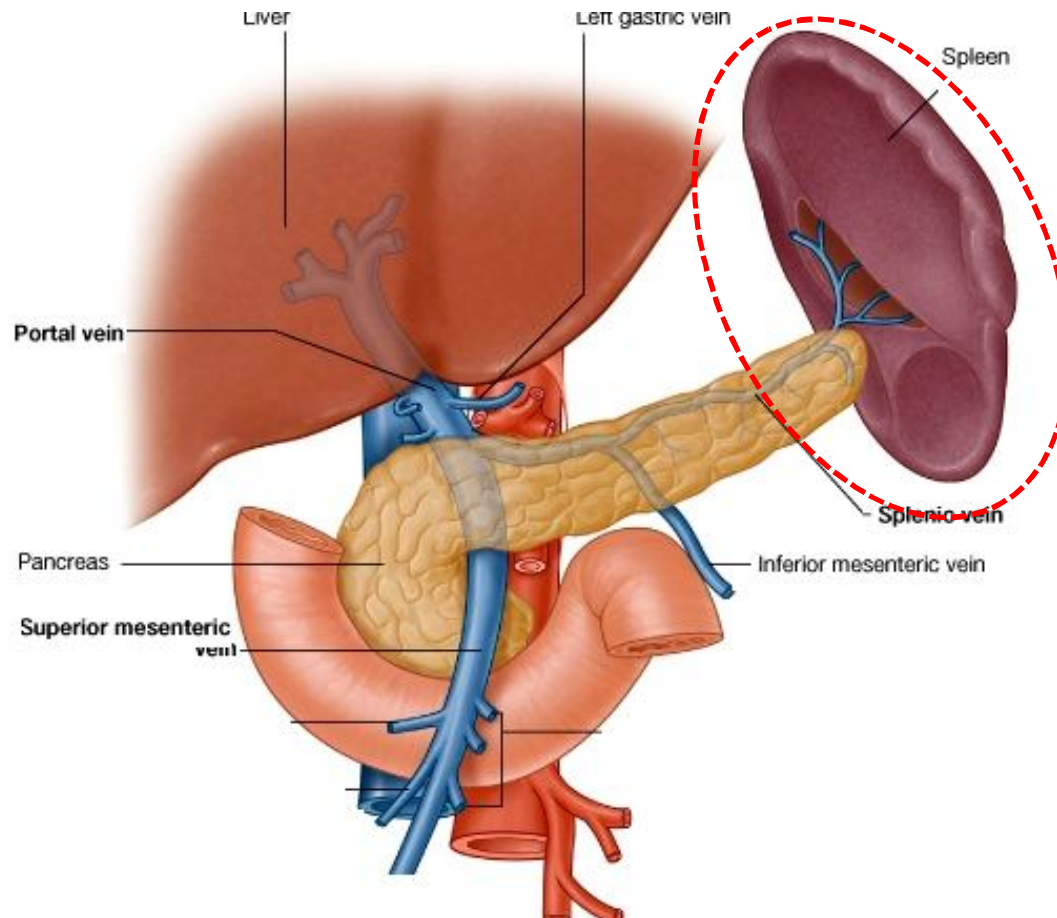
(1) Splenic vein joins with **(2) superior mesenteric vein** to form **(3) portal vein**.

Body of the pancreas



- The **body** passes to the left and passes **anterior** to the (1) **aorta** and the (2) **left kidney**.
- The (3) **splenic artery** undulates along the superior border of the body of the pancreas with the **splenic vein** coursing posterior to the body.

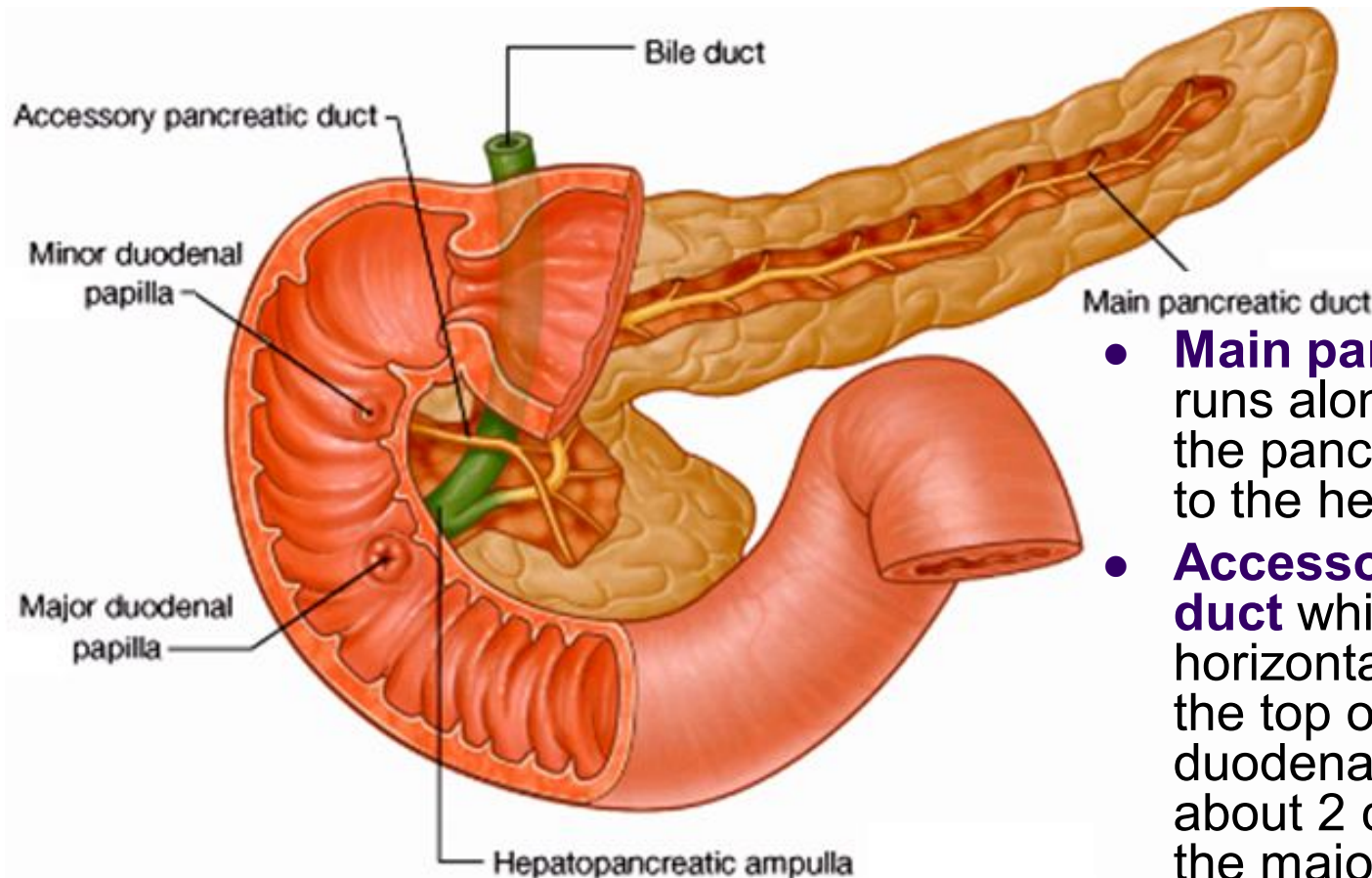
Tail of the pancreas



- The **tail** of the pancreas enters the **splenorenal ligament** to reach the **hilum of the spleen**.
- It is the only part of the pancreas that is **intraperitoneal**.
- **Tail of the pancreas** may be **mistakenly removed** during **splenectomy** and resulting in **sugar diabetes** because it contains a lot endocrine cells.



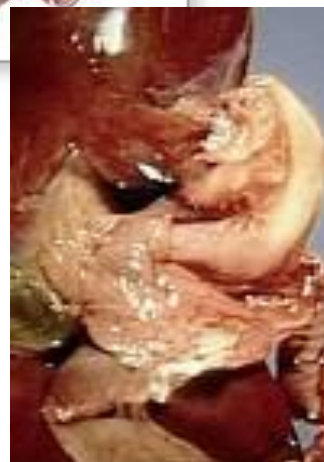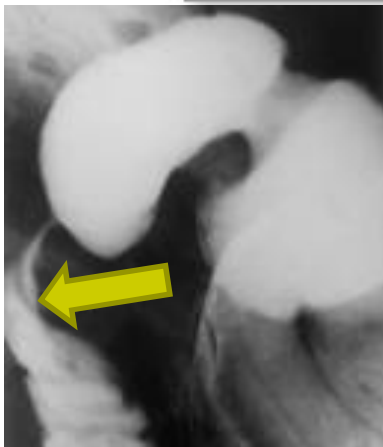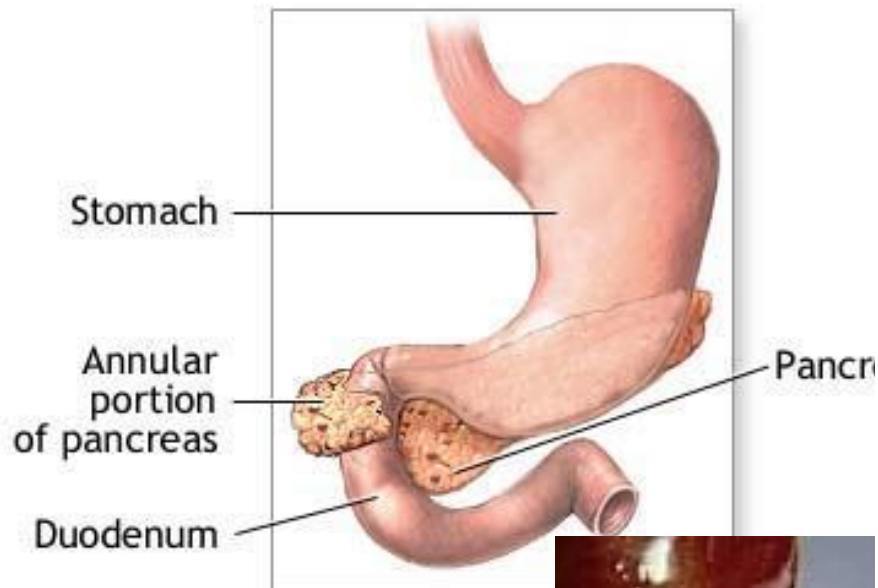
Ducts of the pancreas



- **Main pancreatic duct** runs along the long axis of the pancreas from the tail to the head.
- **Accessory pancreatic duct** which runs horizontally opens onto the top of the minor duodenal papilla which is about 2 cm proximal to the major duodenal papilla on the posteromedial wall of the duodenum.



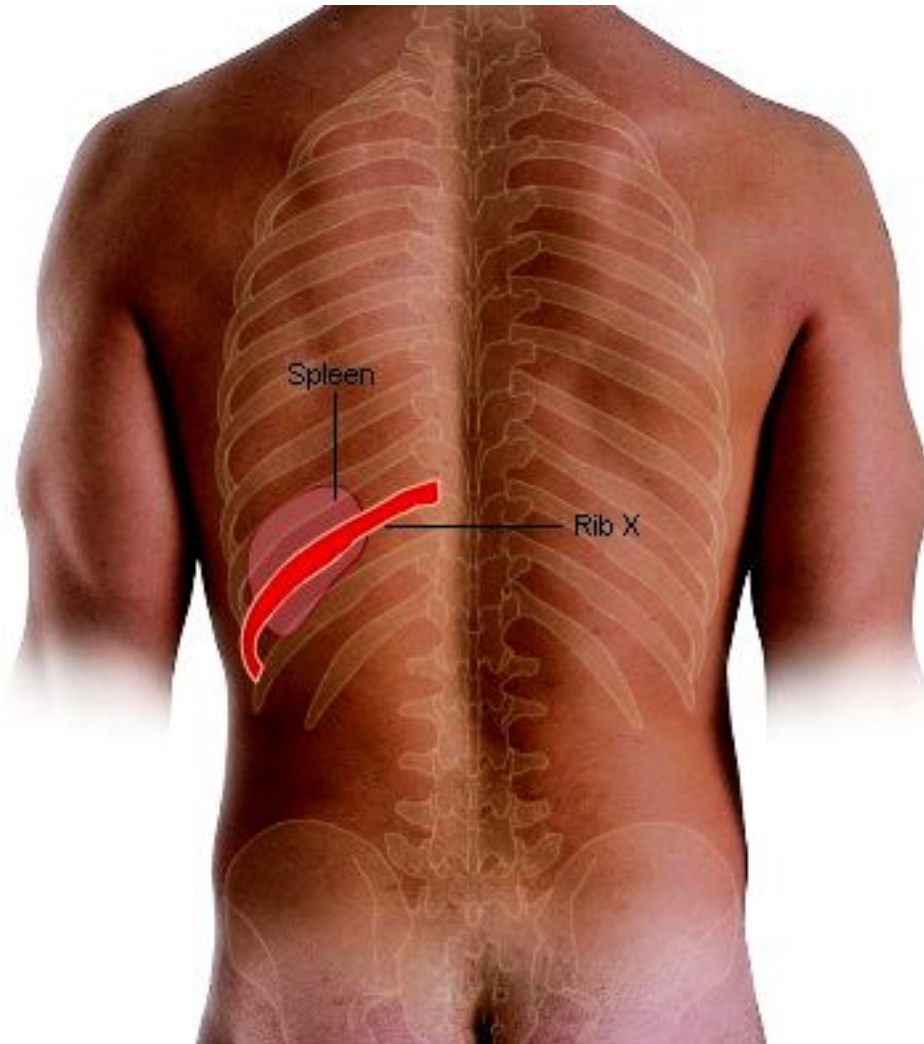
Annular Pancreas



- **Annular pancreas** is caused by malformation during the development of the pancreas, before birth.
- Occurs when the ventral and dorsal pancreatic buds form a **ring around the duodenum**, thereby causing an **obstruction of the duodenum** and **polyhydramnios**
- **Symptoms:**
 1. **Feeding intolerance in newborns**
 2. Fullness after eating
 3. Nausea and **vomiting**
- **Half of cases** are not diagnosed until symptoms occur in **adulthood**.

48. Spleen: Two borders

spleen comes from -dorsal mesogastrium
and liver comes from vental mesogastrium



The spleen is a **peritoneal** organ in the upper left quadrant that is deep to the left **9th, 10th, and 11th ribs.**

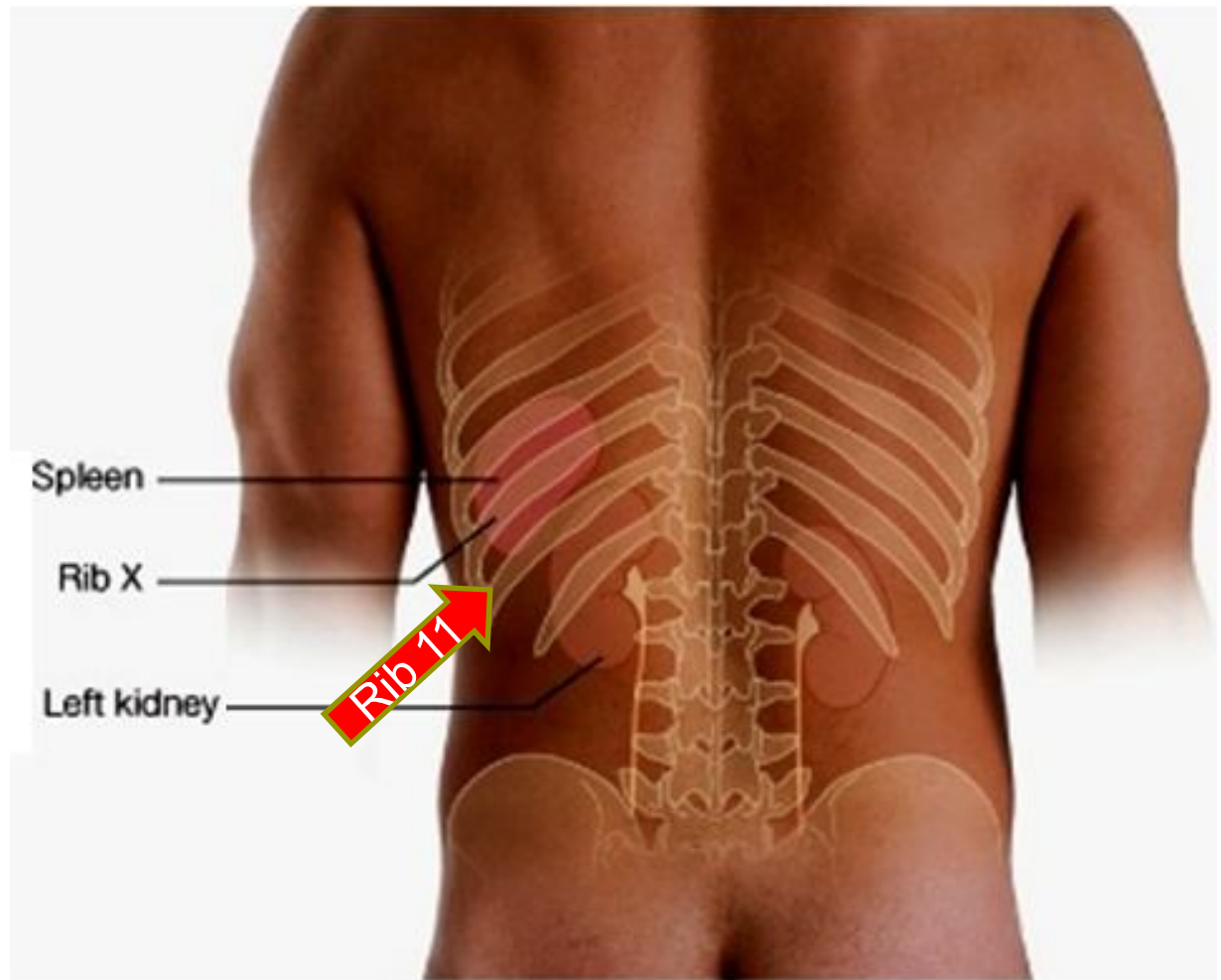
The spleen follows the contour of **rib 10 (axis of the spleen).**

- Because the spleen lies above the costal margin, a normal-sized spleen **is not palpable.**
- The spleen **may be lacerated** with a **fracture of the 9th and 10th ribs.**

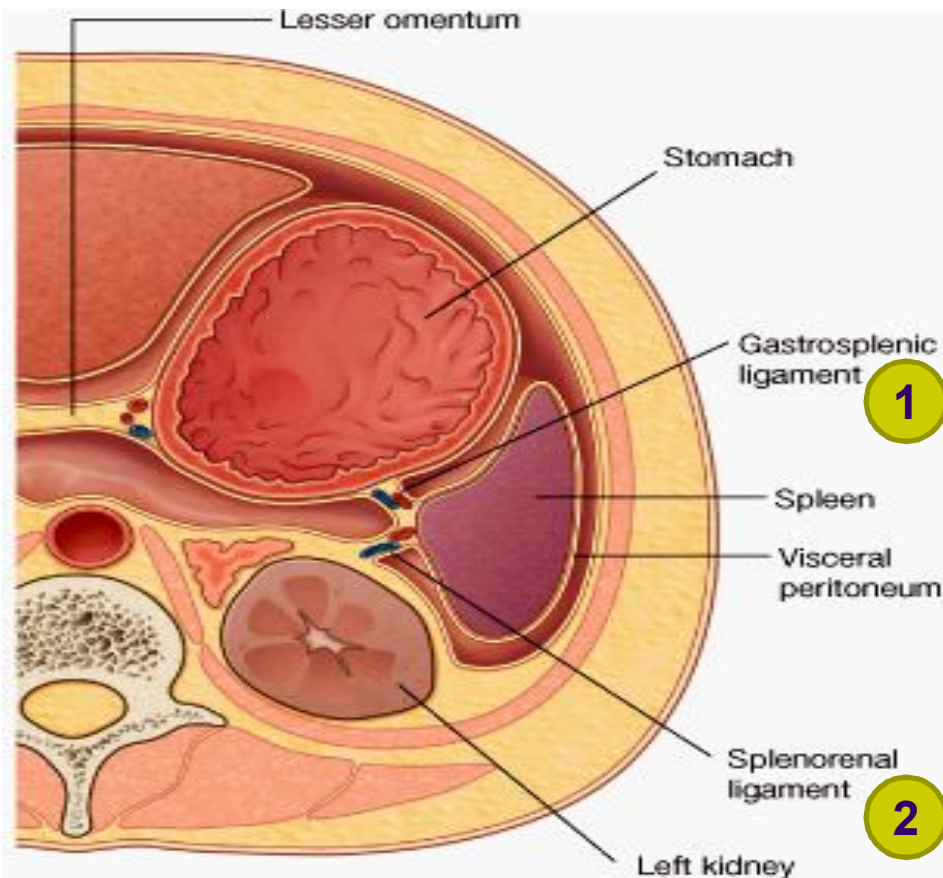
Relations of the Spleen and Left Kidney



- The spleen follows the contour of **10th rib** and extends from the superior pole of the left kidney to just posterior to the midaxillary line.
- **The border between spleen and upper pole of the left kidney is 11th rib.**



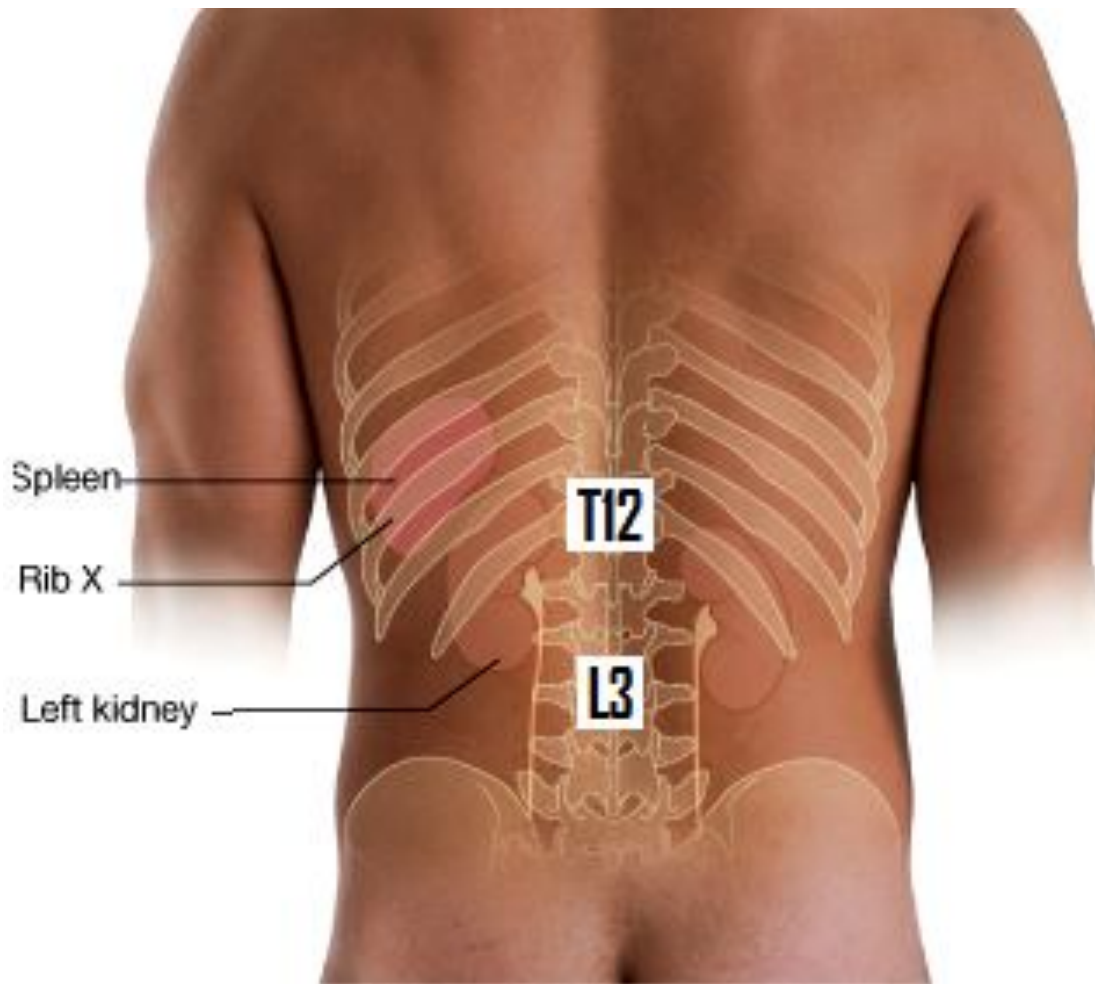
Peritoneal connections



- **Gastrosplenic ligament (1)** connects the spleen with the upper end of the **greater curvature** of the **stomach**. It contains the **short gastric vessels**, **left gastroepiploic (gastroomental) vessels** and accompanying lymph vessels
- **Splenorenal (lienorenal) ligament (2)** connects the spleen with the **left kidney**. It contains the **tail of the pancreas**, **splenic vessels**, accompanying lymph vessels and nerves.

49. Kidney:

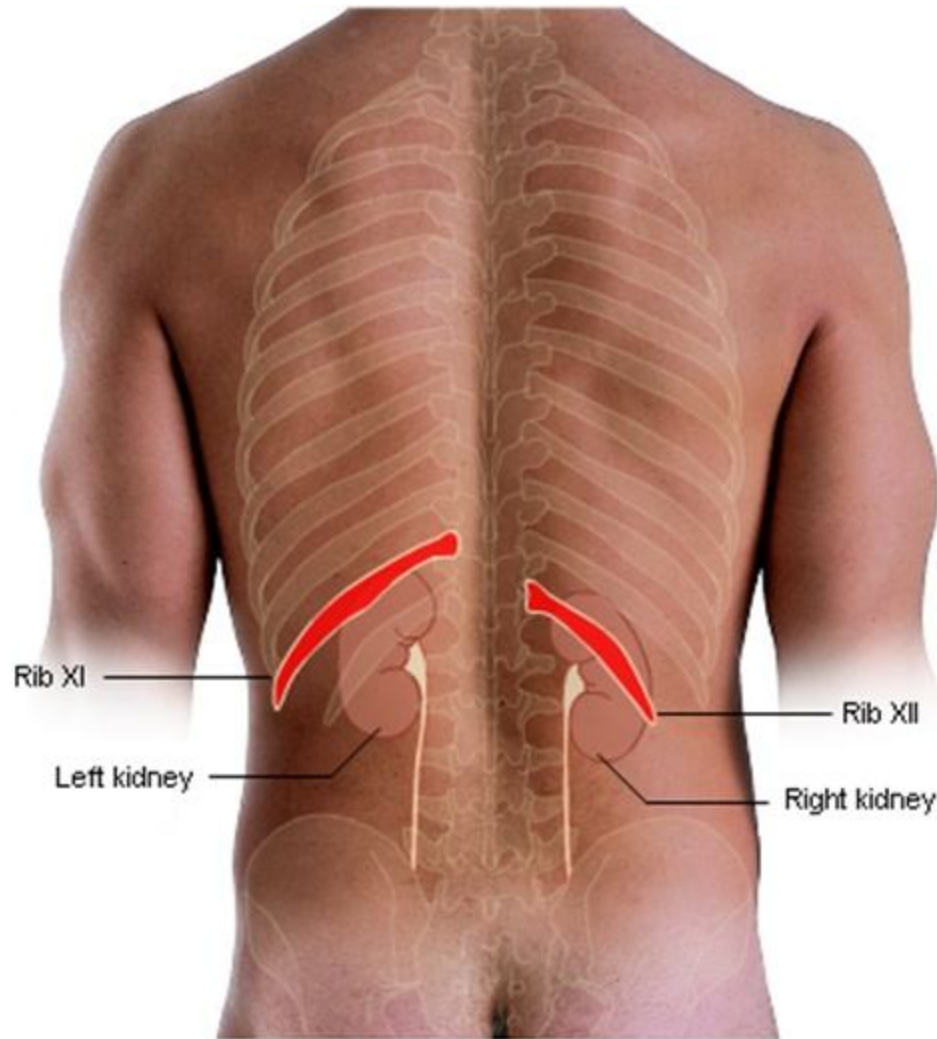
Dimensions and position



- During life, the kidneys are reddish brown and measure approximately **11-12 cm in length**, **5-6 cm in width**, and **2.5-3 cm in thickness**.
- They are extending from the level of **T12** to the level of **L3**, the **right kidney** lying **about 2-3 cm lower than the left one**.
- The lateral border of the kidney is convex. Its medial border is convex at both ends but concave in the middle where there is the **hilum** of the kidney.



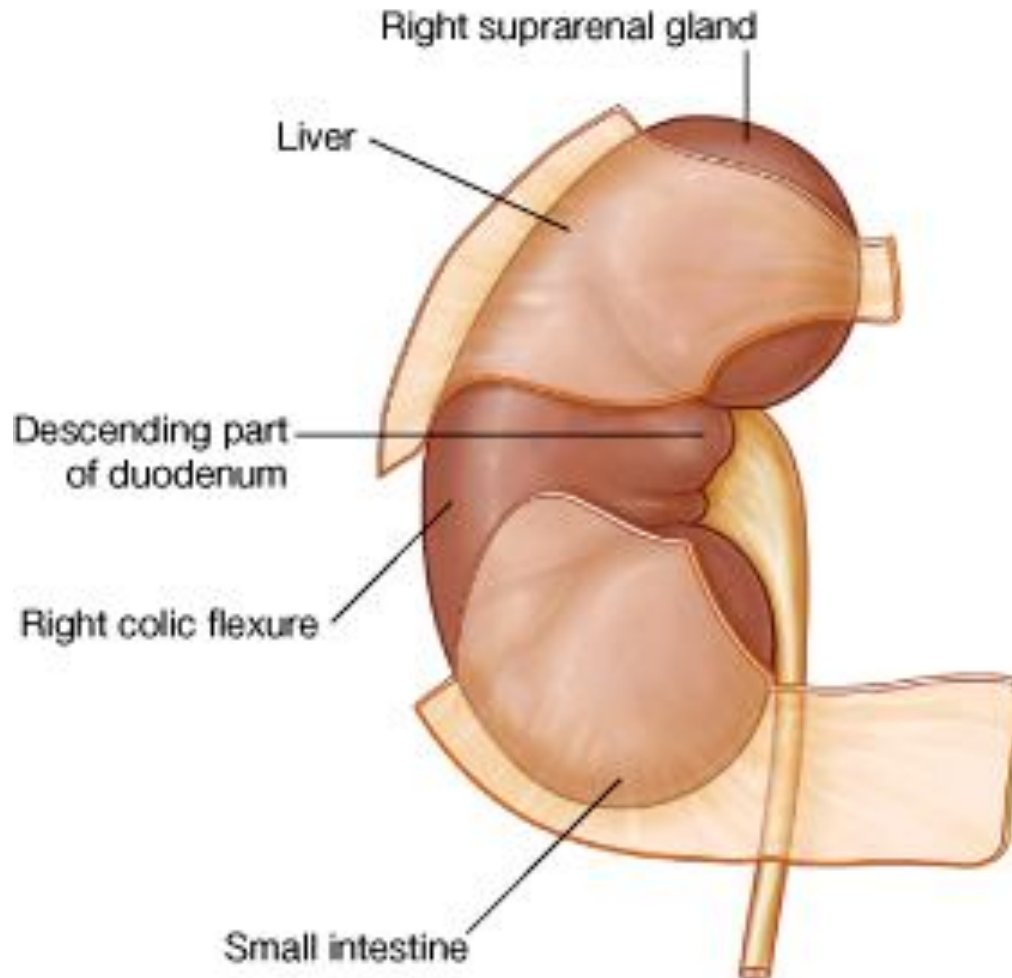
Position of the kidneys



- The **upper** end of the **left** kidney (**XI rib**) is a little higher than the **right** one (**XII rib**).
- The **lower** ends of the kidneys occur around the level of the IV disc L3/L4.
- **N.B.** The border **between left kidney and spleen** is **XI rib**
- The **hila** of the kidneys and the beginnings of the ureters are at approximately the **L1** vertebra.
- The **ureters** descend vertically anterior to the tips of the transverse processes of the lower lumbar vertebrae and enter the pelvis and **lies on the psoas major** muscle.



Anterior relations of the **right** kidney

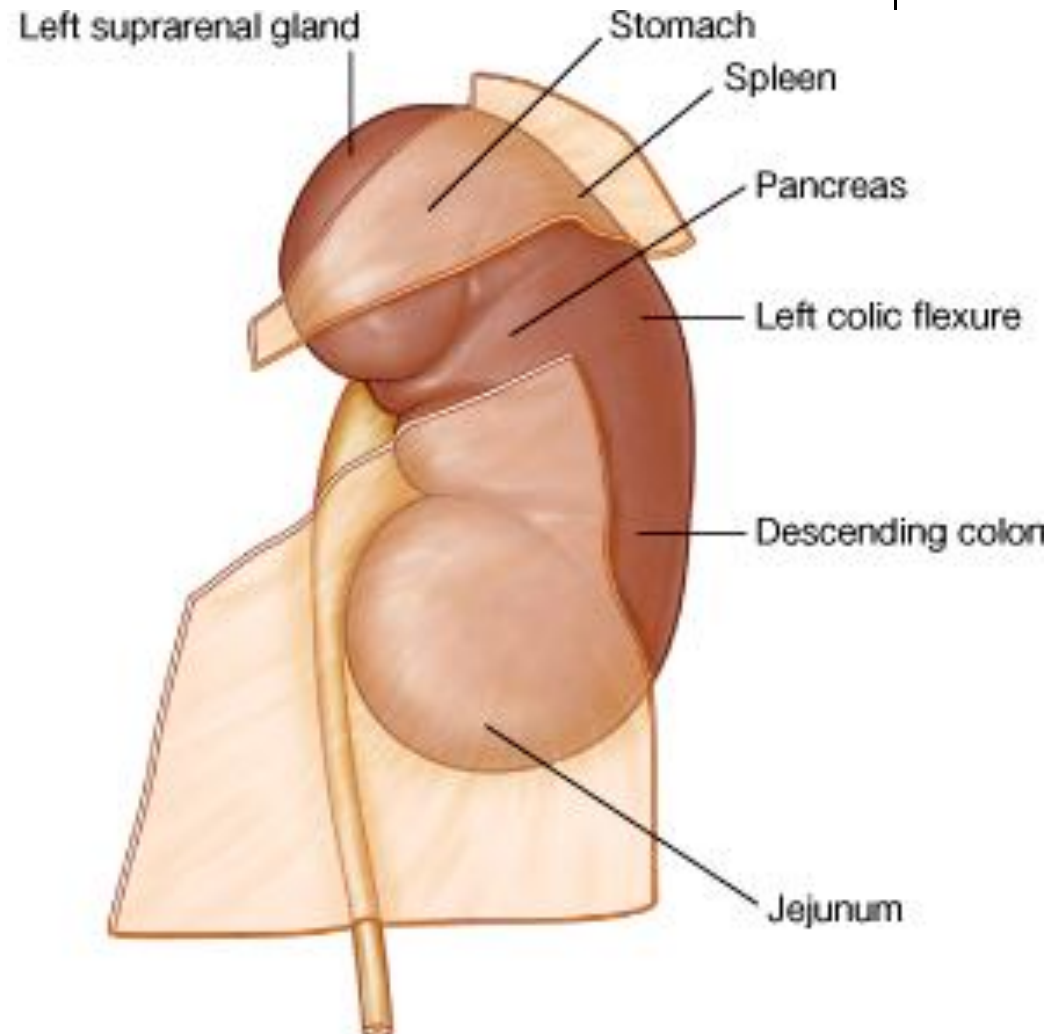


1. **Right suprarenal gland**
2. 2nd part of the duodenum
3. **Right** lobe of the **liver**
4. **Right colic flexure**
5. **Small intestine**

Anterior relations of the **left** kidney

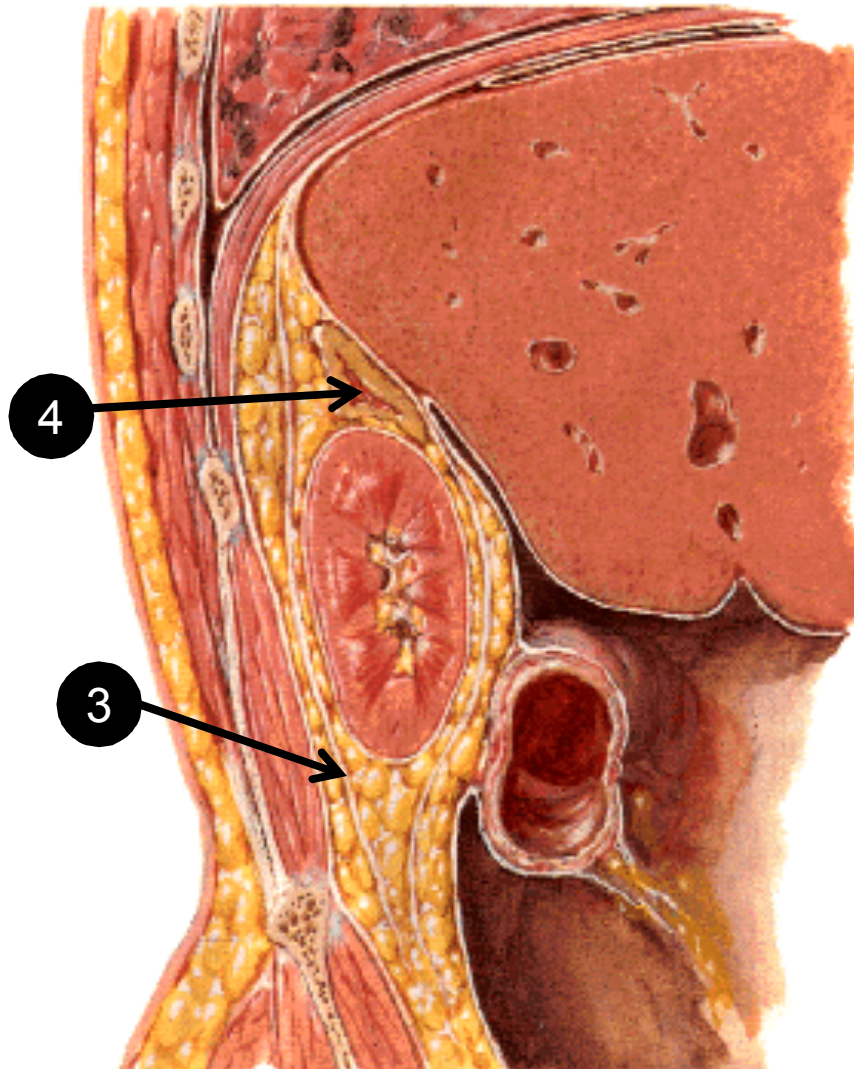


1. **Left suprarenal gland**
2. **Stomach**
3. **Spleen**
4. **Body of pancreas** and
splenic vessels
5. **Descending colon**
6. **Small intestine**





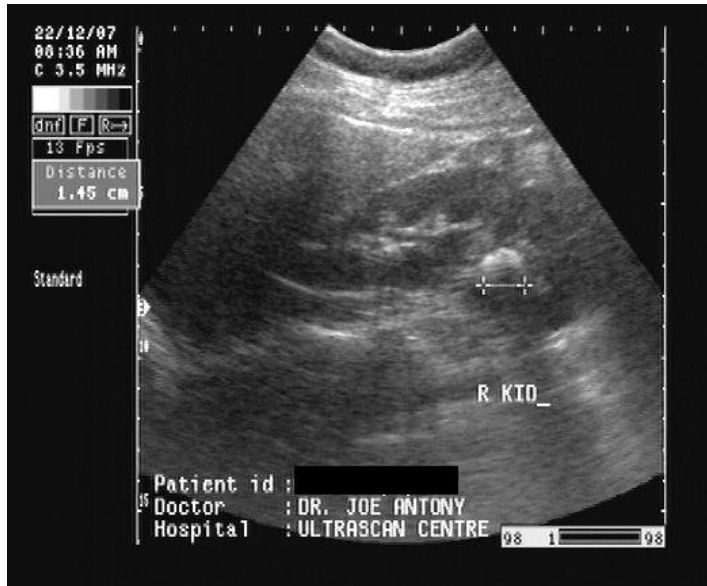
Renal (Gerota) fascia



- Enclosing the perinephric fat is a membranous condensation of the extraperitoneal fascia - the **renal fascia (3)**.
- The **suprarenal glands (4)** are also enclosed in this fascial compartment, usually separated from the kidneys by a thin septum.
- ***N.B. The renal fascia must be incised in any surgical approach to this organ.***

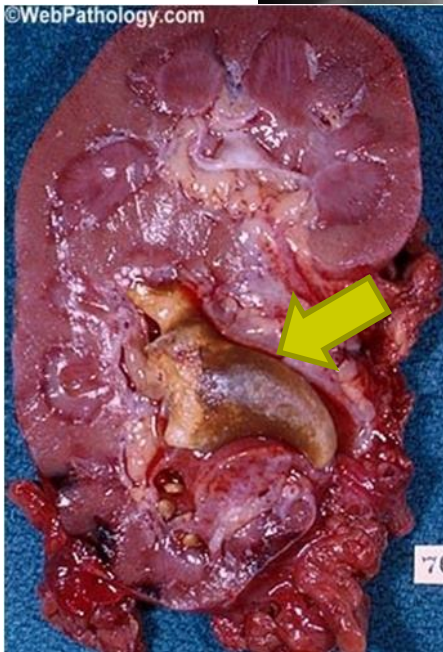
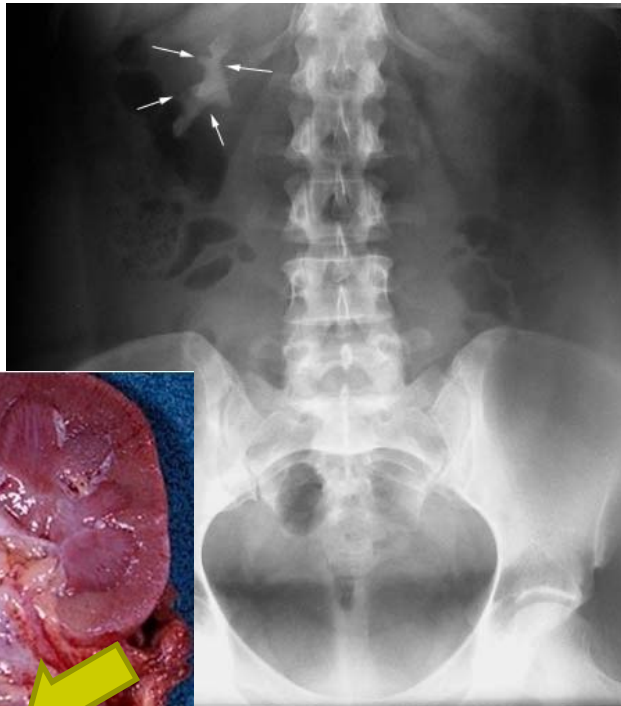


50. Nephrolithiasis



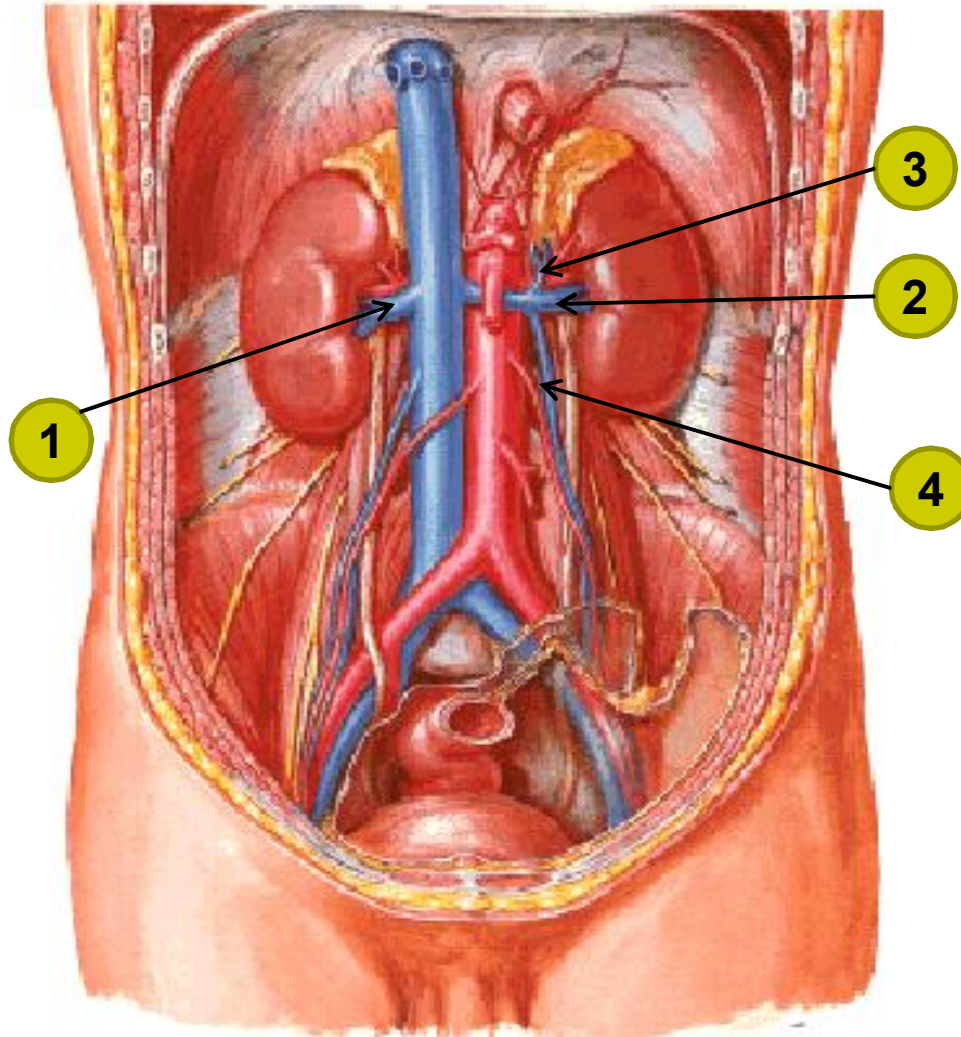
- **Renal calculi** are solid concretions (crystal aggregations) formed in the kidneys from dissolved urinary minerals.
- There are several types of kidney stones. The majority are **calcium oxalate** stones, followed by **calcium phosphate** stones.
- Kidney stones typically leave the body by passage in the urine stream, and many stones are formed and passed without causing symptoms.
- If stones grow to sufficient size before passage (at least 2-3 mm), they can cause **obstruction of the ureter** (renal colic).

Staghorn calculi



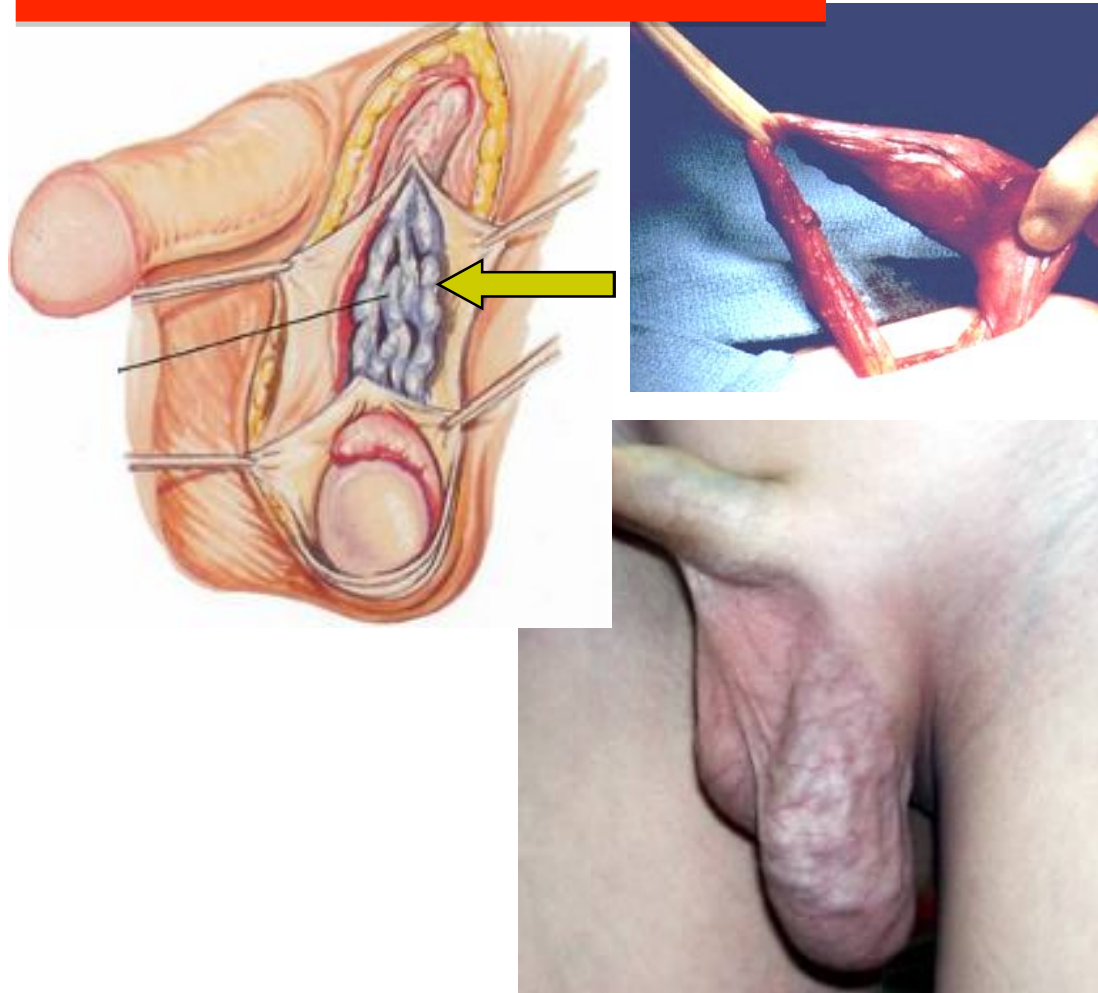
- Renal stone that develops in the **pelvicaliceal system**, and in advanced cases has a branching configuration which resembles the **antlers of a stag**.
- Staghorn calculi are composed of **magnesium ammonium phosphate**, which forms in urine that has an abnormally **high pH** (above 7.2).
- This high pH usually develops because of recurrent urinary tract infection with microorganisms such as **Proteus mirabilis**.

51. Renal veins



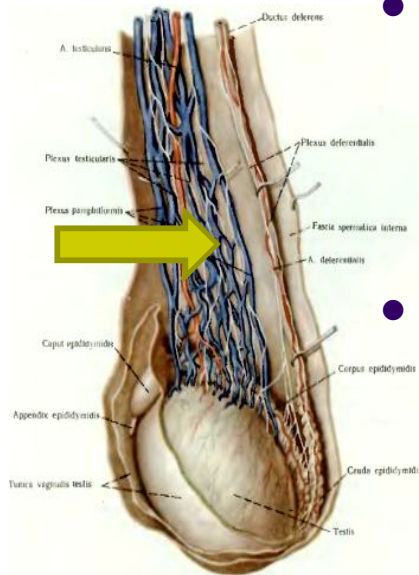
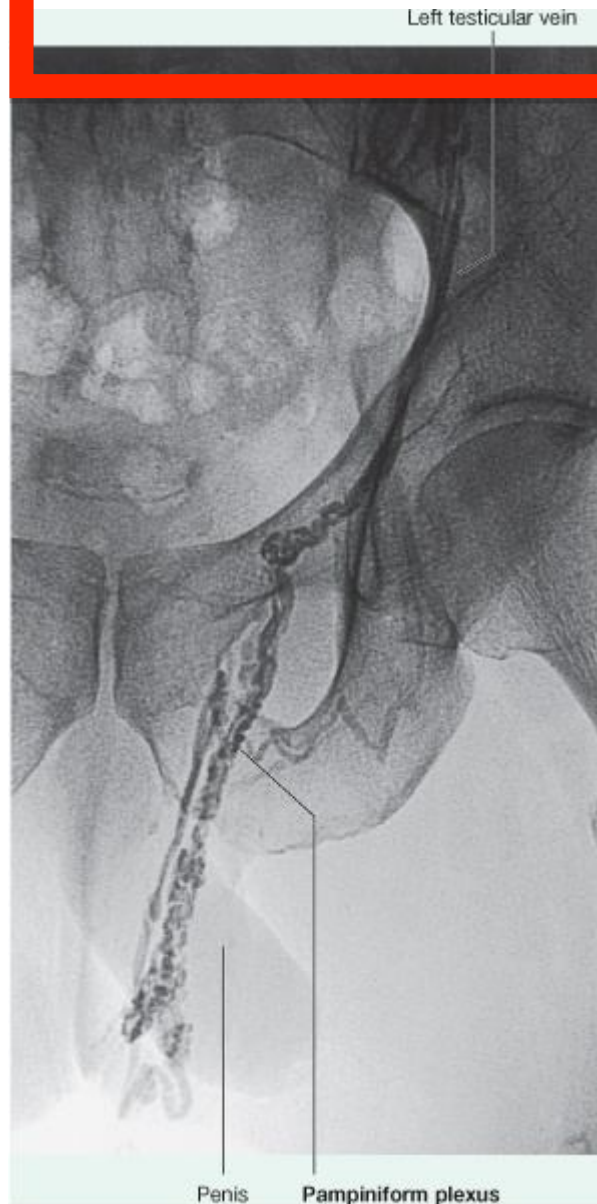
- The **right renal (1)** vein is much **shorter** than the left. Both veins lie anterior to the corresponding artery in hilum of kidneys.
- The long **left renal vein (2)** is joined by the **left suprarenal (3)** and **left gonadal (4)** (testicular or ovarian) **veins** before it reached **IVC**.
- The **left renal** vein **crosses anterior to the aorta**, just inferior to the origin of the **SMA**.

52. Varicocele



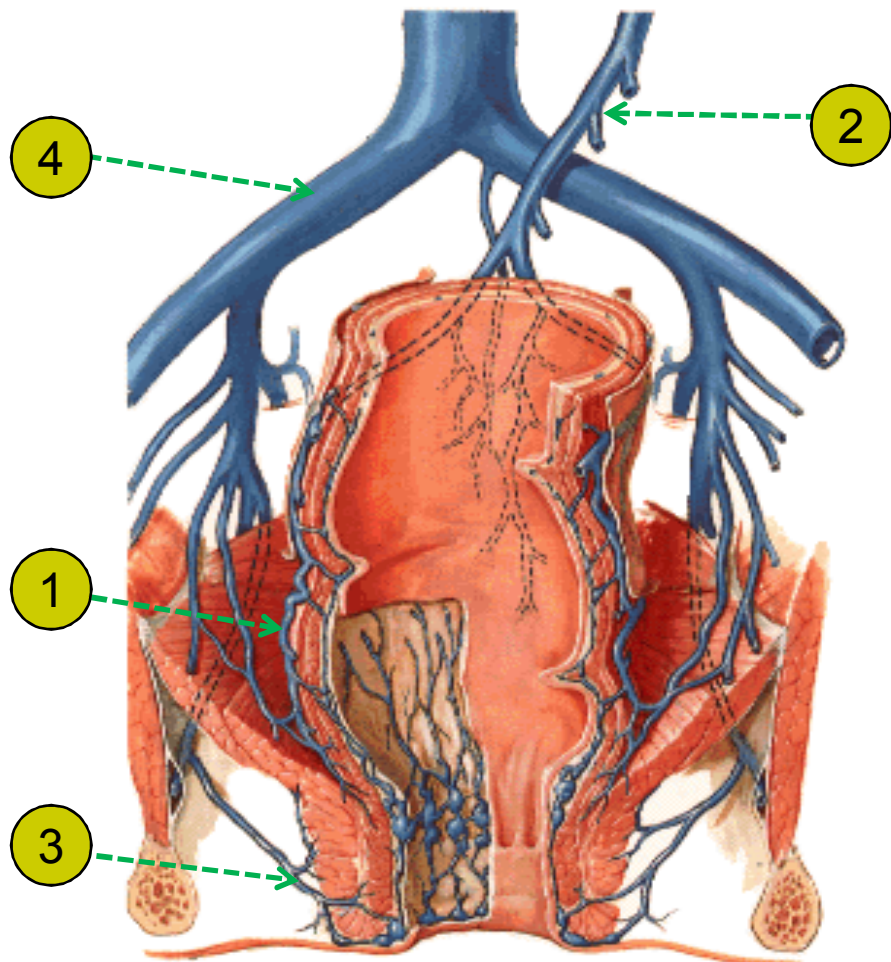
- It is **engorgement** of the **pampiniform plexus** that produces a **wormlike scrotal mass** and enlargement of the spermatic cord.
- Formation is usually on the **left side**.
- Varicocele on either side may indicate **kidney disease** or may signal a retro peritoneal malignancy **obstructing the testicular vein**.

Pampiniform plexus



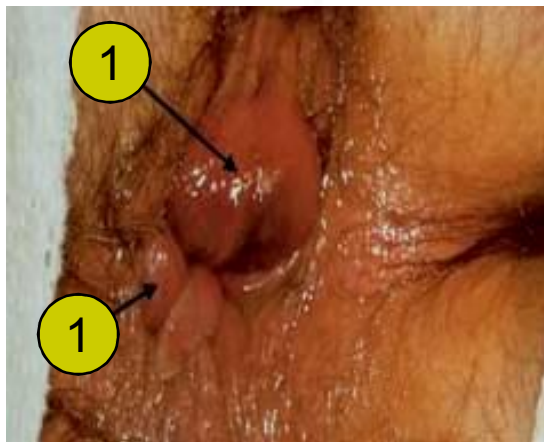
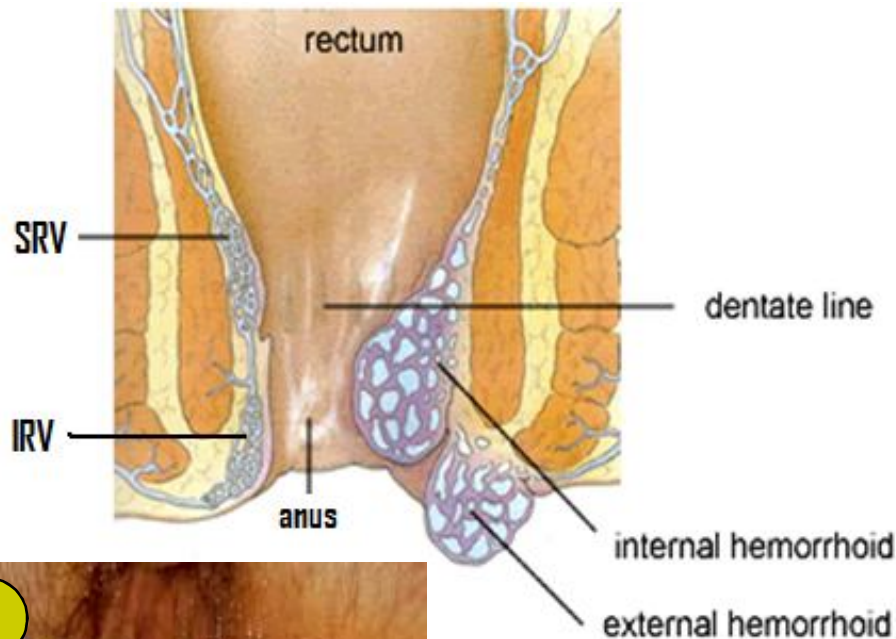
- Each testicular or ovarian vein is formed by coalescence of a **pampiniform plexus**: the testicular at the **deep inguinal ring**, the ovarian at the margin of the superior aperture of the pelvis.
- The veins run accompany the corresponding arteries. The **left pampiniform plexus enters the left renal vein**; the **right one enters directly the IVC** inferior to the renal vein.
- That is why **varicocely** (engorgement of the pampiniform plexus that produces a scrotal mass) is more often located on the **left**.

53. Hemorrhoids: Venous drainage from rectum



- Above pectinate line: **superior rectal vein [1]** into **portal system [2]**.
- Below pectinate line: **inferior rectal vein [3]** into **inferior vena cava [4]**.

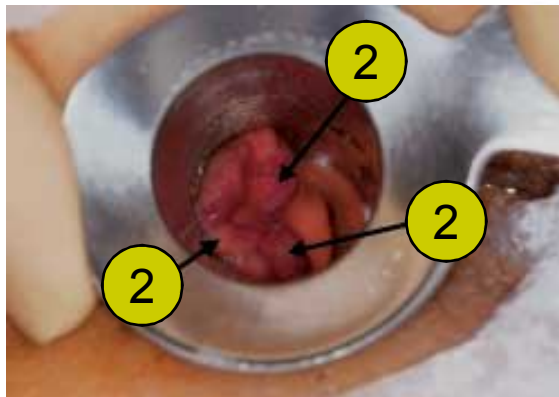
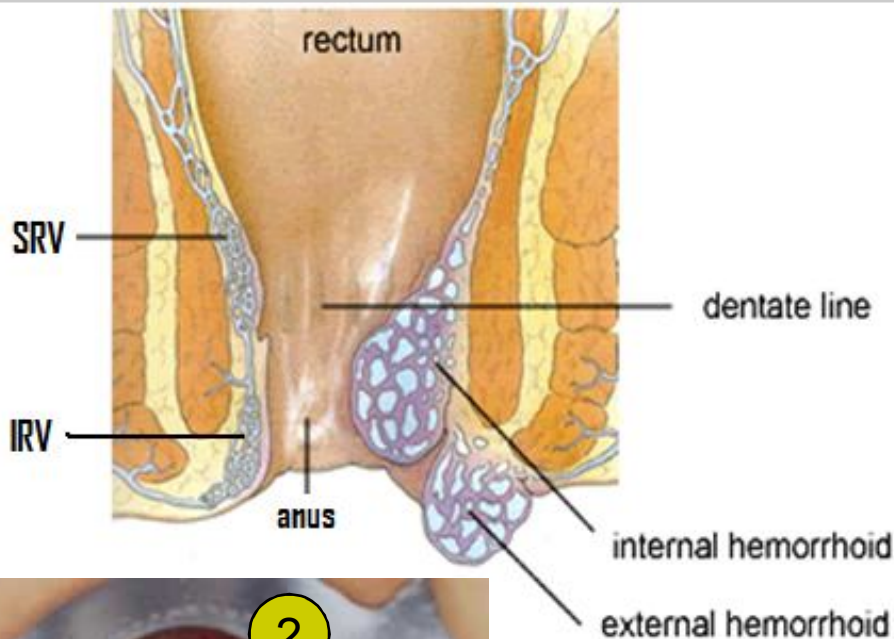
External hemorrhoids



- **Hemorrhoids** are masses that typically **protrude from anus** during **defecation**.
- Hemorrhoids are commonly associated with **constipation**, extended **sitting** and straining at the toilet, **pregnancy**, and disorders that hinder venous return.

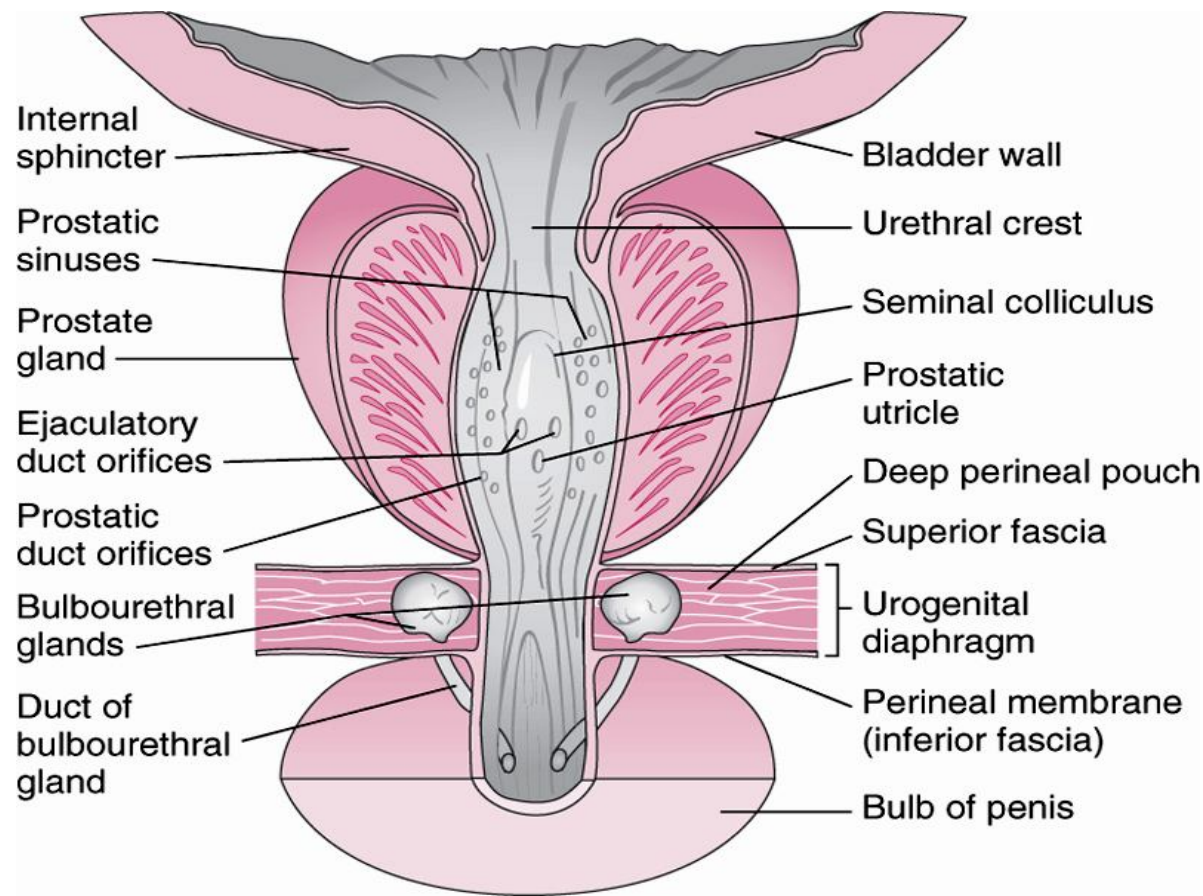
1. **External hemorrhoids** are dilated tributaries of the inferior rectal veins (IRV) below the pectinate line and are **painful** because the mucosa is supplied by somatic afferent fibers of the inferior rectal nerves.

Internal hemorrhoids



- **2. Internal hemorrhoids** are dilated tributaries of the superior rectal veins (SRV) above the pectinate line and are **not painful** because the mucosa is supplied by visceral afferent fibers.
- Internal hemorrhoids frequently develop during **pregnancy** because of pressure on the superior rectal veins.

54. Perineal pouches: Contents of the deep pouch



© Elsevier. Moore & Roy: Rapid Review Gross and Developmental Anatomy 2e - www.studentconsult.com

The deep perineal pouch is formed by the fasciae and muscles of the urogenital diaphragm.

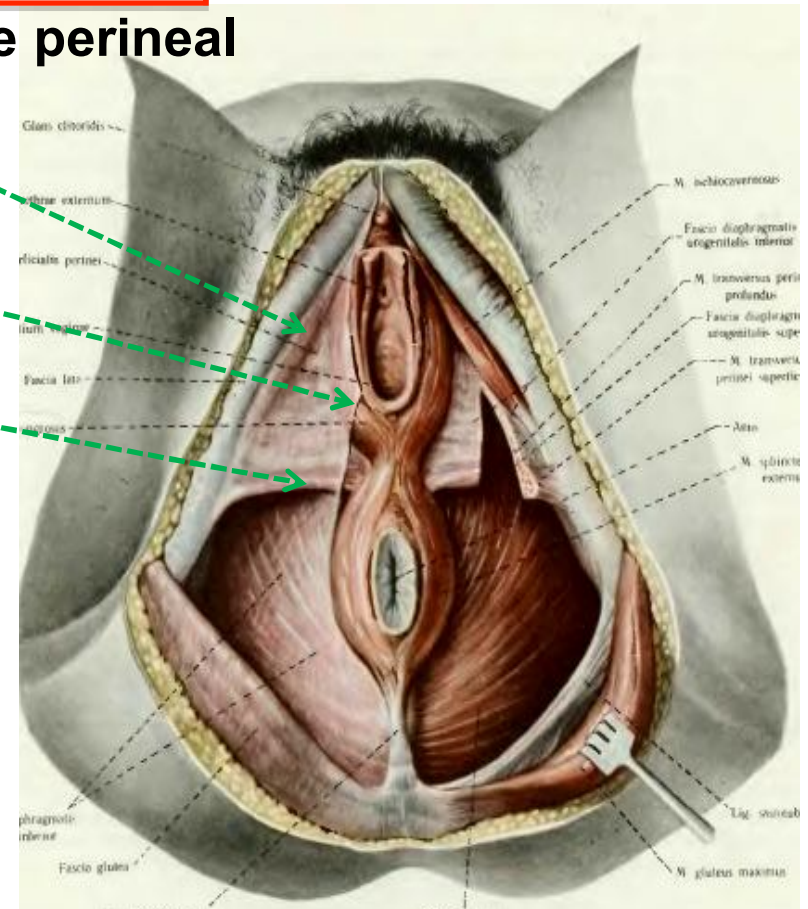
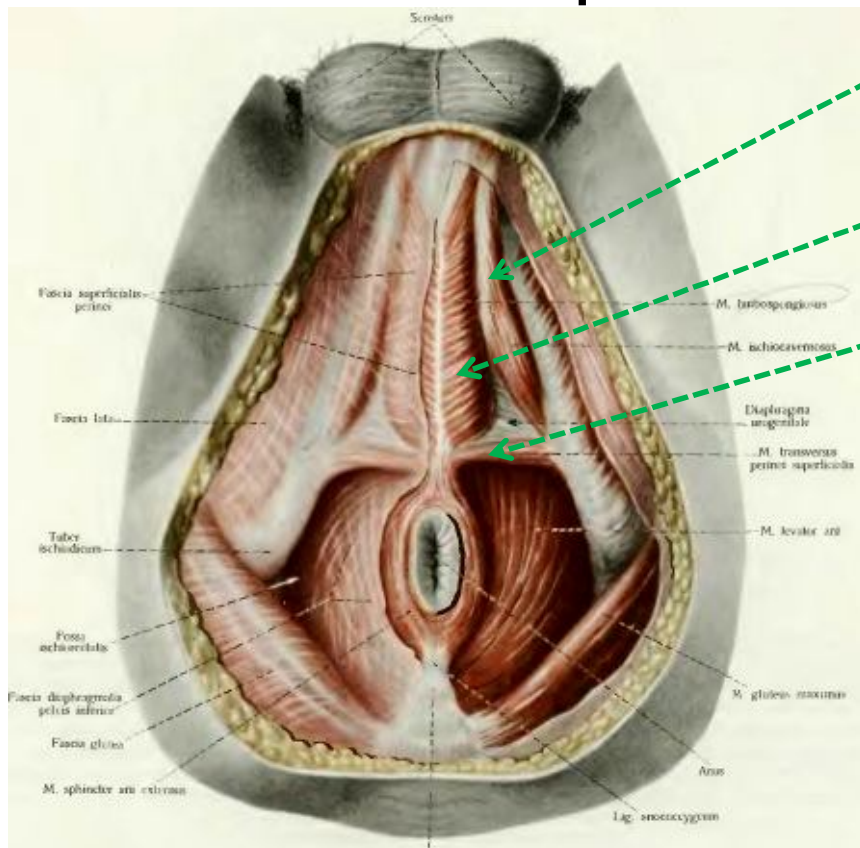
It contains:

1. Sphincter urethrae muscle
2. Deep transverse perineal muscle
3. **Bulbourethral (Cowper) glands** (in the male only) - ducts perforate perineal membrane and enters bulbar urethra.

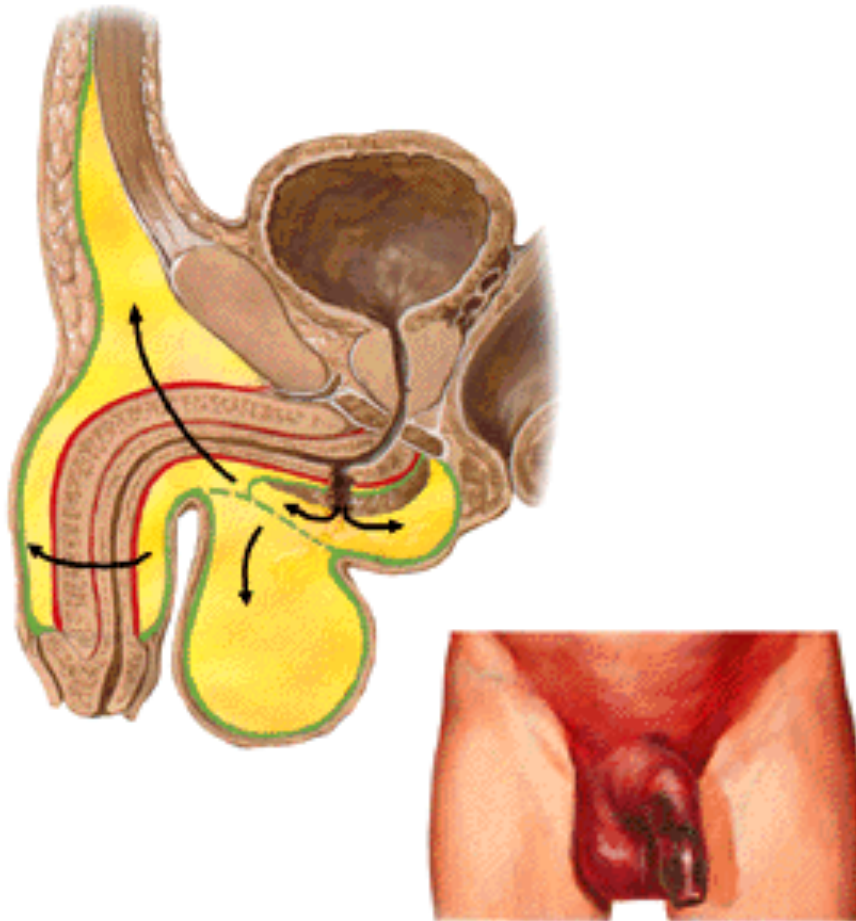


55. Superficial perineal pouch

1. Ischiocavernosus muscle
2. Bulbospongiosus muscle
3. Superficial transverse perineal

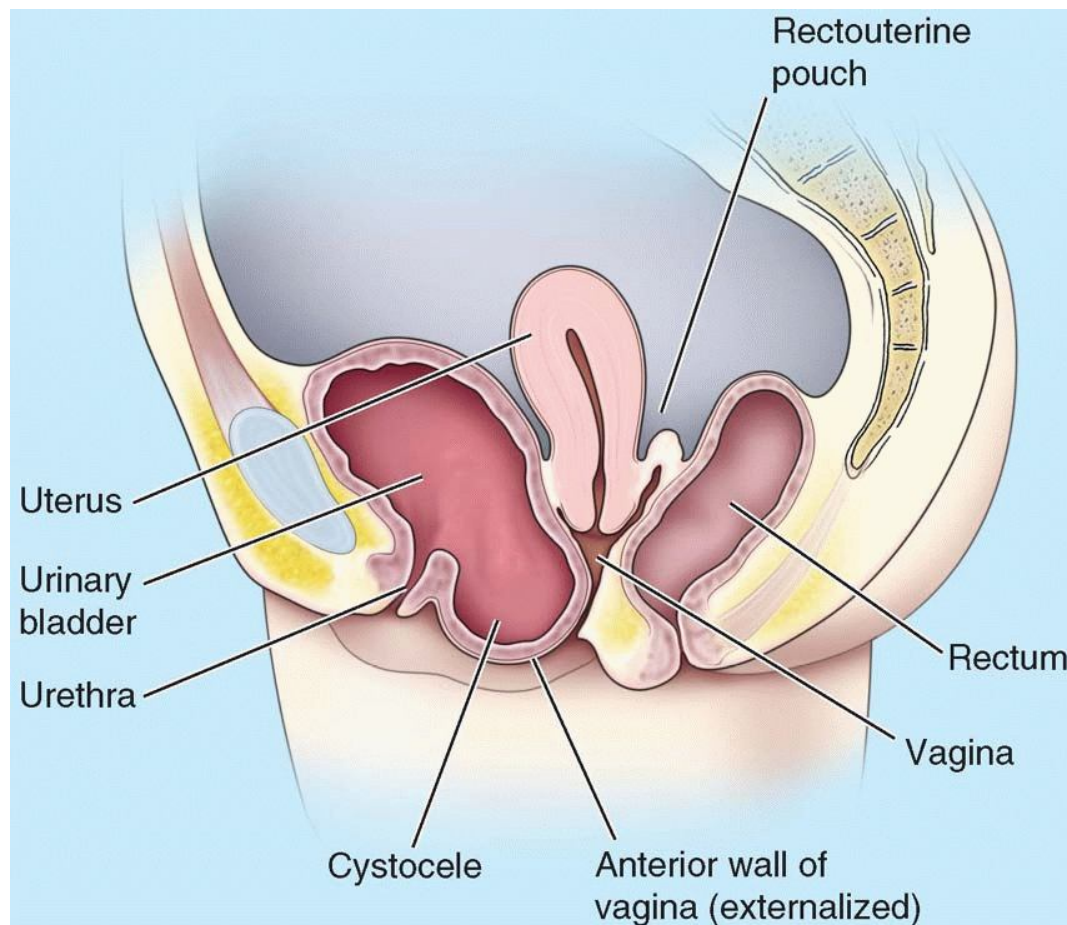


Urine leaks



- After a crushing blow or a penetrating injury, the spongy urethra commonly **ruptures within the bulb of the penis**, and **urine leaks** into the superficial perineal pouch.
- The **superficial perineal fascia keeps urine** from passing into the thigh or the anal triangle, but after distending the scrotum and penis, urine can pass **over the pubis** into the **anterior abdominal wall** deep to the deep layer of superficial abdominal fascia.

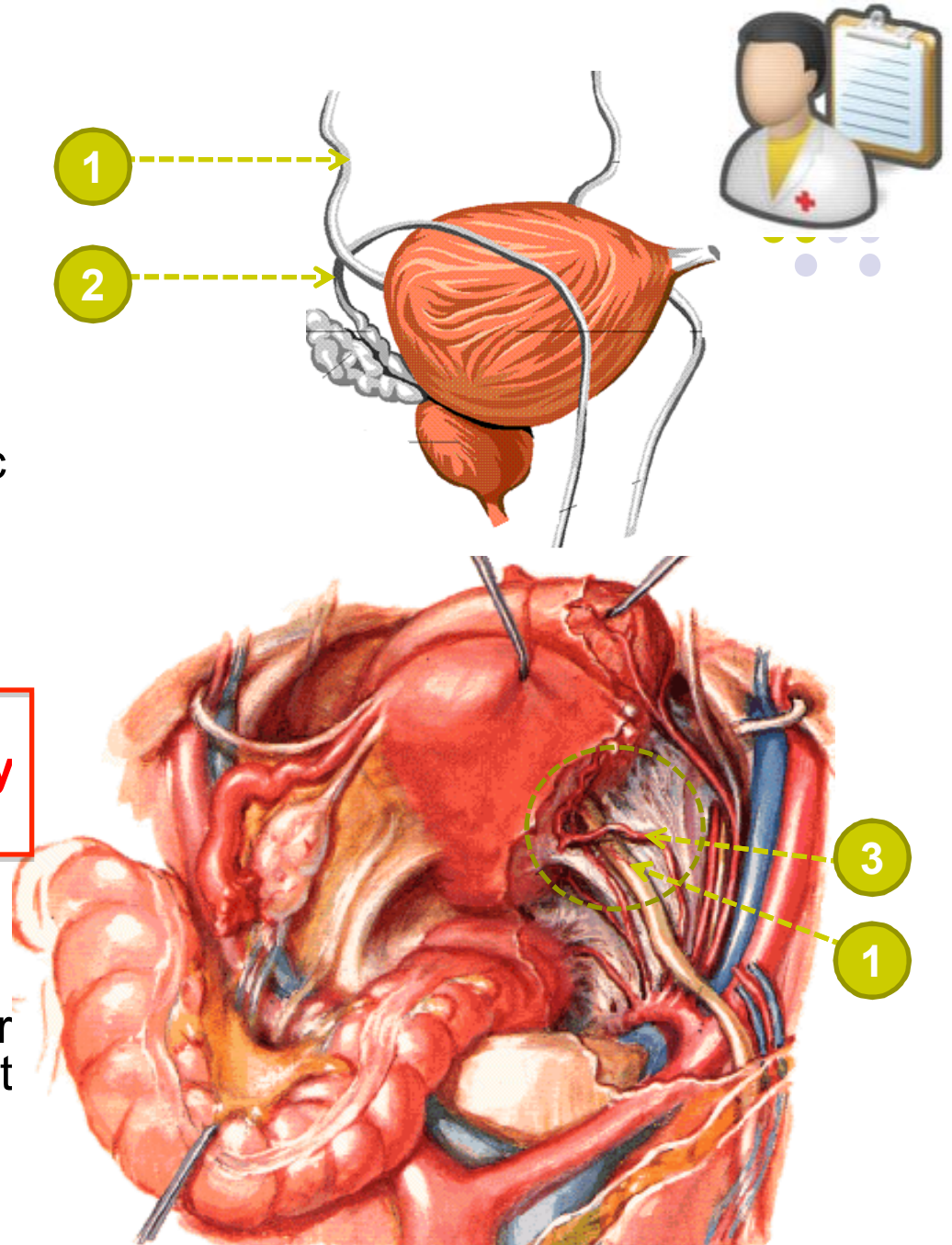
56. Cystocele (hernia of bladder)



- **Loss of bladder support in females** by damage to the pelvic floor during childbirth (e.g., laceration of perineal muscles or a lesion of the nerves supply) can result in **protrusion of the bladder onto the anterior vaginal wall**.
- When **intraabdominal pressure increases** (as when “bearing down” during defecation), the anterior wall of the vagina may protrude through the vaginal orifice into the vestibule

57. Ureter

- **Ureter [1]** crosses pelvic brim near bifurcation of common iliac artery
- **In male**, crossed superiorly by **ductus deferens [2]** near bladder
- **In female**, crossed anteriorly and superiorly by **uterine artery [3]** in base of broad ligament
- **N.B.** The ureter can be damaged during a **hysterectomy** or surgical repair of a prolapsed uterus because it lies posterior and inferior to the uterine artery.





58. Nerve supply of pelvic viscera

Parasympathetic innervation:

- Preganglionic neurons are located in **sacral parasympathetic n. (S2-S4)** in the spinal cord.
- Their processes run into **pelvic splanchnic nerves** and relay with postganglionic neurons located inside of pelvic organs in the **intramural plexus**.

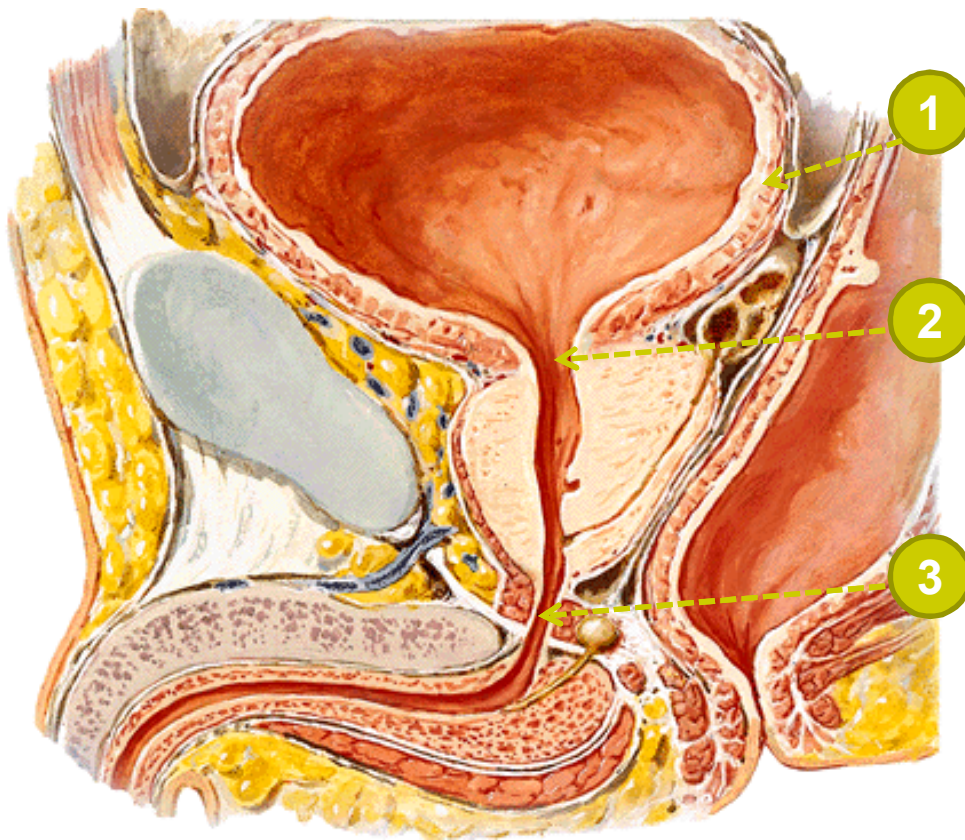
Sympathetic innervation:

- Sympathetic fibers of preganglionic neurons **T12-L2** segments (**IML**) come through the sympathetic trunk and form **sacral splanchnic nerves**.
- They contribute to the **inferior hypogastric plexus**, where postganglionic neurons are located. Branches of inferior hypogastric plexus reach organs wrapping around the branches of the internal iliac artery.

Sensory innervation:

- The sensory fibers from **S2-S4 dorsal root ganglions** comes together with parasympathetic and carry **pain** sensations from the organs.

Micturition reflex



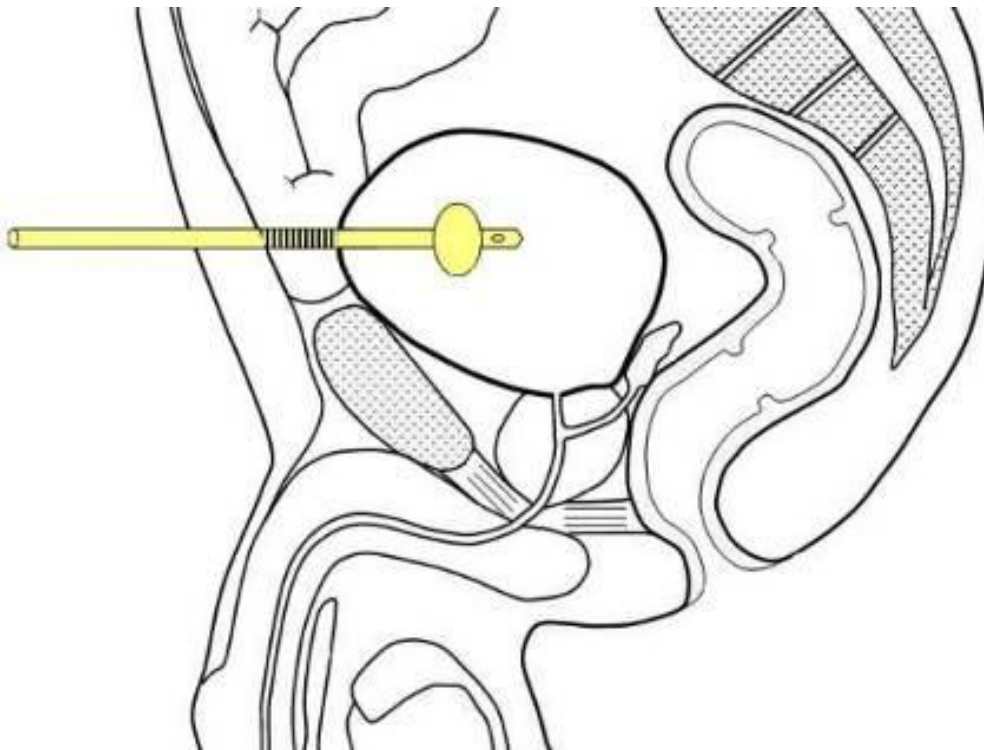
Facilitating emptying:

- **Parasympathetic** fibers (**pelvic splanchnic nn.**) **stimulate** **detrusor** muscle [1] contraction and involuntary relax internal sphincter [2].
- **Somatic motor** fibers (**pudendal nerve**) cause voluntary **relaxation** of **external** [3] urethral sphincter.

Inhibiting emptying:

- **Sympathetic** fibers (**sacral splanchnic nn.**) inhibit detrusor muscle [1] and **stimulate** **internal** sphincter [2].

59. Paracentesis of urinary bladder

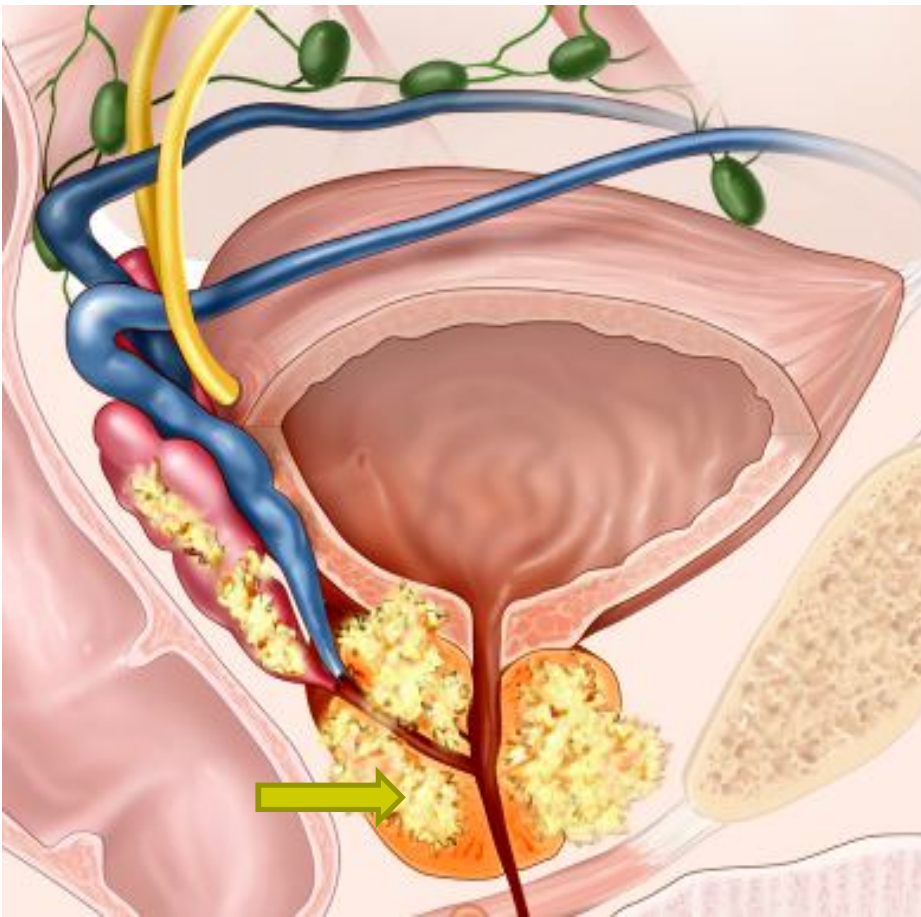


Suprapubic aspiration:

- **Urine can be removed** from the bladder without penetrating the peritoneum by inserting a needle **JUST ABOVE the pubic symphysis**.
- The needle passes successively through skin, superficial and deep layers of superficial fascia, linea alba, transversalis fascia, extraperitoneal connective tissue, and wall of the bladder.

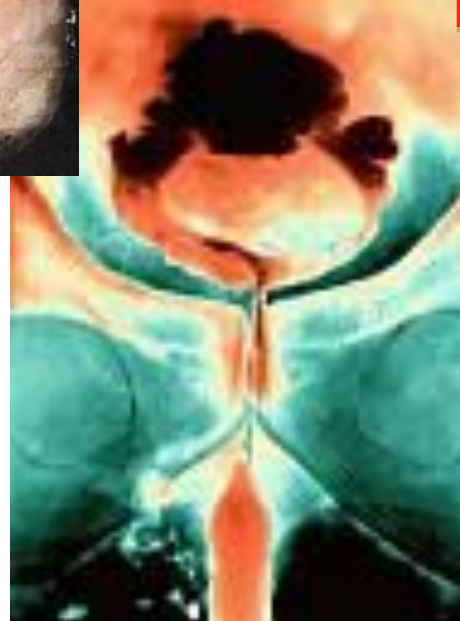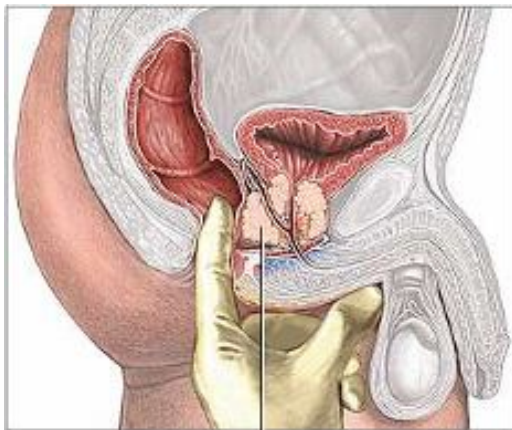
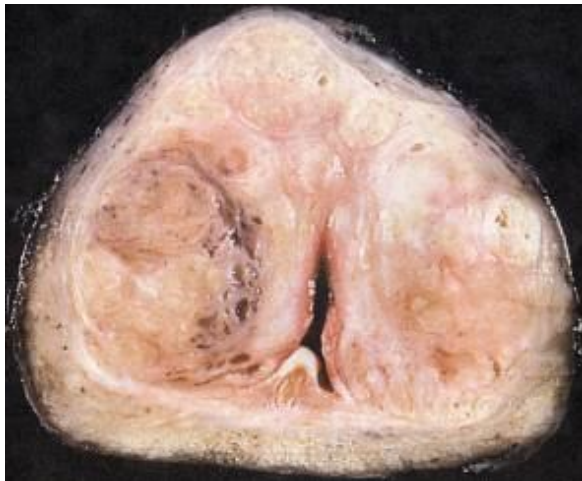60. Prostate tumors

Prostate cancer



- It usually begins in the posterior lobe of the gland, and early stages are often asymptomatic.
- Later malignant enlargement of the prostate can narrow or occlude the prostatic urethra.
- **N.B.** Prostatic malignancies tend to **metastasize to** vertebrae and the brain because the **prostatic venous plexus** has numerous connections with the **vertebral venous plexus via sacral veins**.

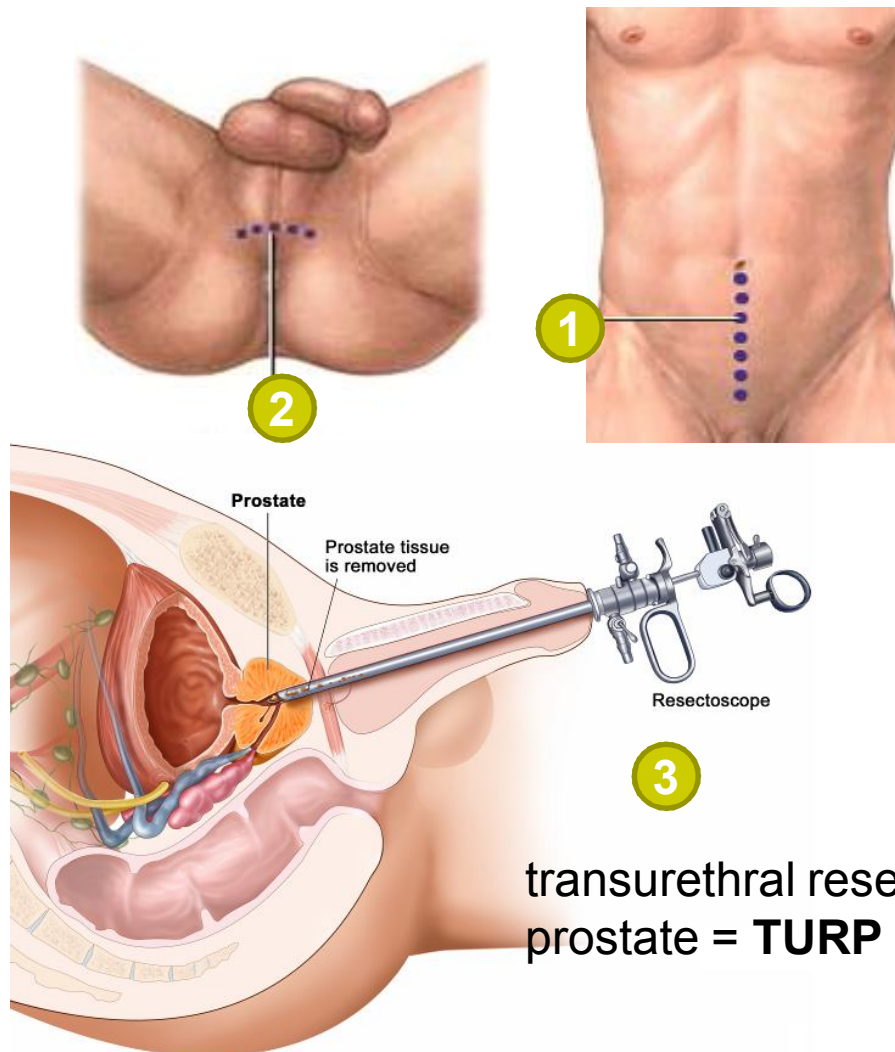
Benign hypertrophy of the prostate (BHP)



- **BHP** is common in **men after middle age**.
- **Prostate adenoma** (benign hypertrophy) usually involves **median lobe**.
- **BHP** is a common cause of **urethral obstruction**, leading to **nocturia** (need to void during the night), **dysuria** (difficulty and/or pain during urination), and **urgency** (sudden desire to void).
- The **prostate is examined** for enlargement and tumors by **DIGITAL RECTAL examination**.



Prostatectomy



- A prostatectomy may be performed through a **suprapubic [1]** or **perineal [2]** incision or **transurethrally**.
- Because damage to nerves in the capsule of the prostate and around the urethra (**cavernous nerves**) **can cause impotence** and/or **urinary incontinence**.

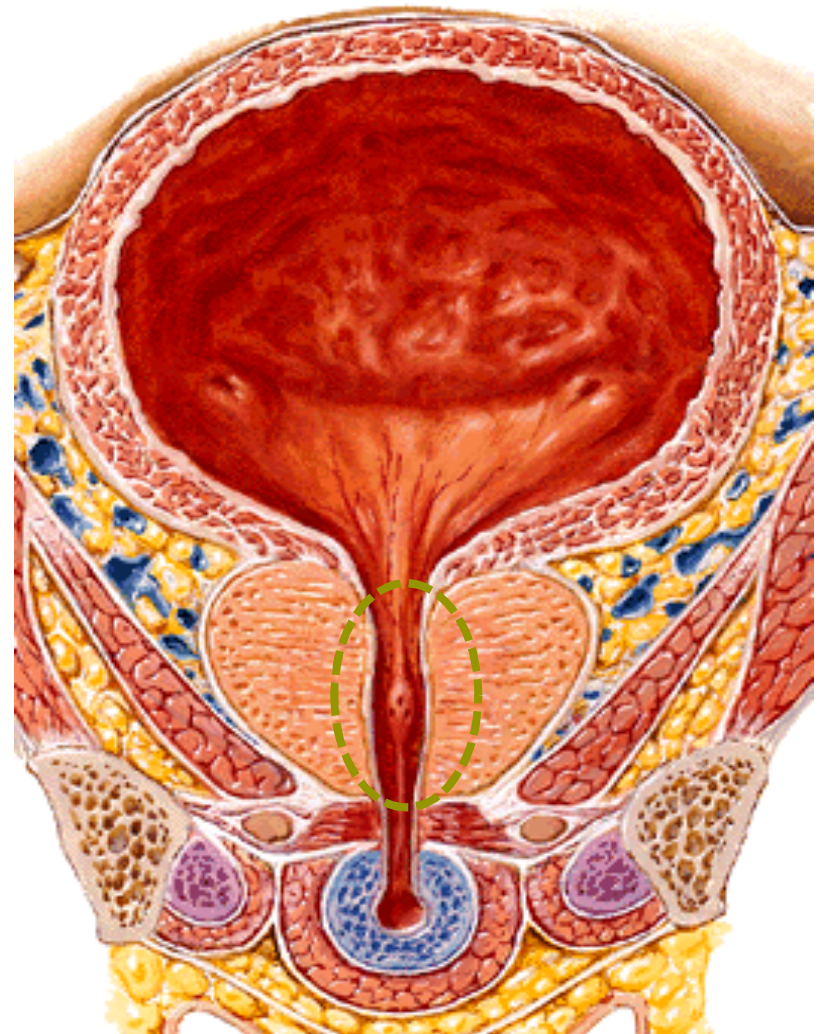
transurethral resection of the prostate = **TURP**

61. Male urethra

Prostatic part

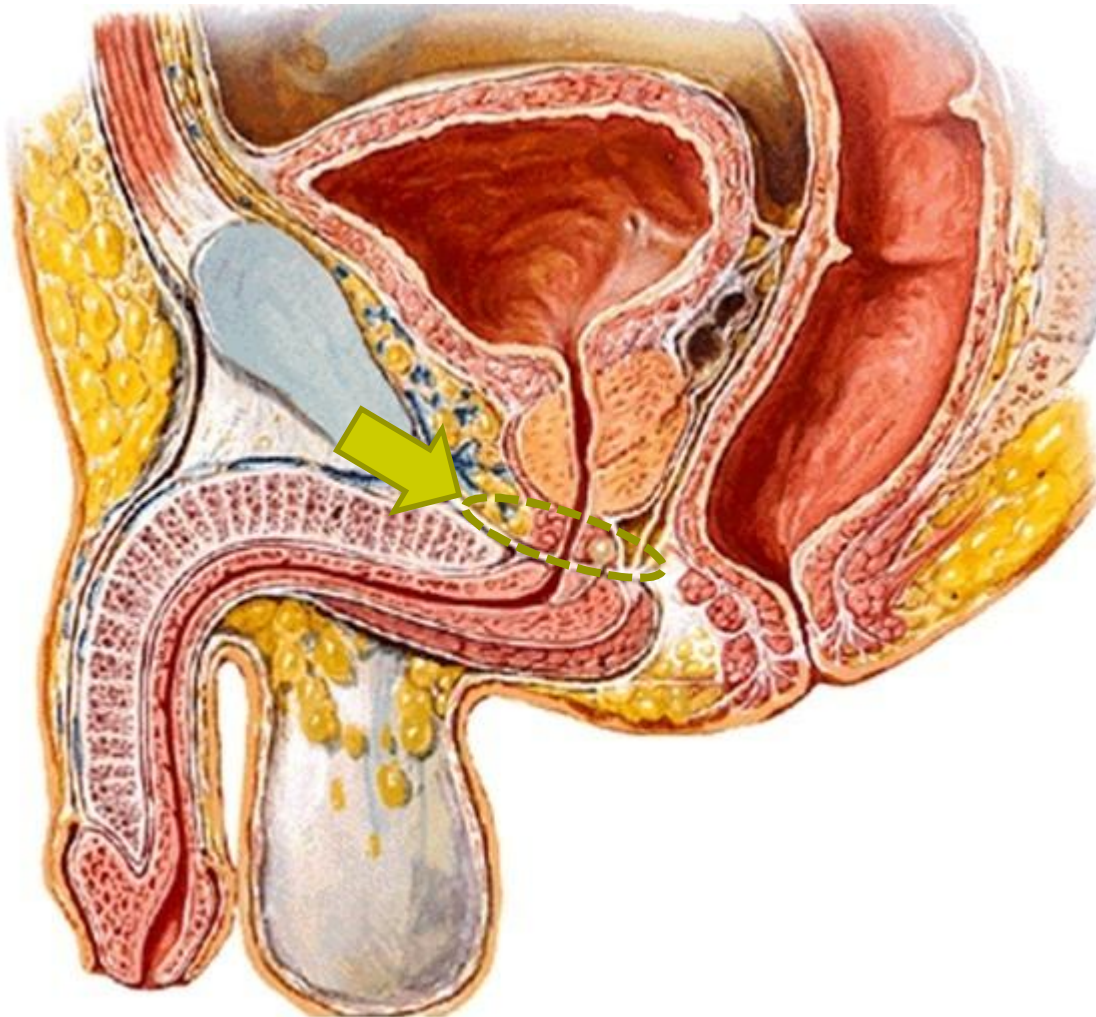


- It is the **widest and the most dilatable part.**
- It is **spindle** shaped (middle part is dilated)
- Its posterior wall presents the following features:
 - Urethral crest - vertical ridge in the midline
 - Seminal colliculus- a spherical swelling in the middle of the urethral crest
 - **Openings of the 2 ejaculatory ducts** are seen on each side on the seminal colliculus
 - Ducts of the prostate gland open into the male urethra



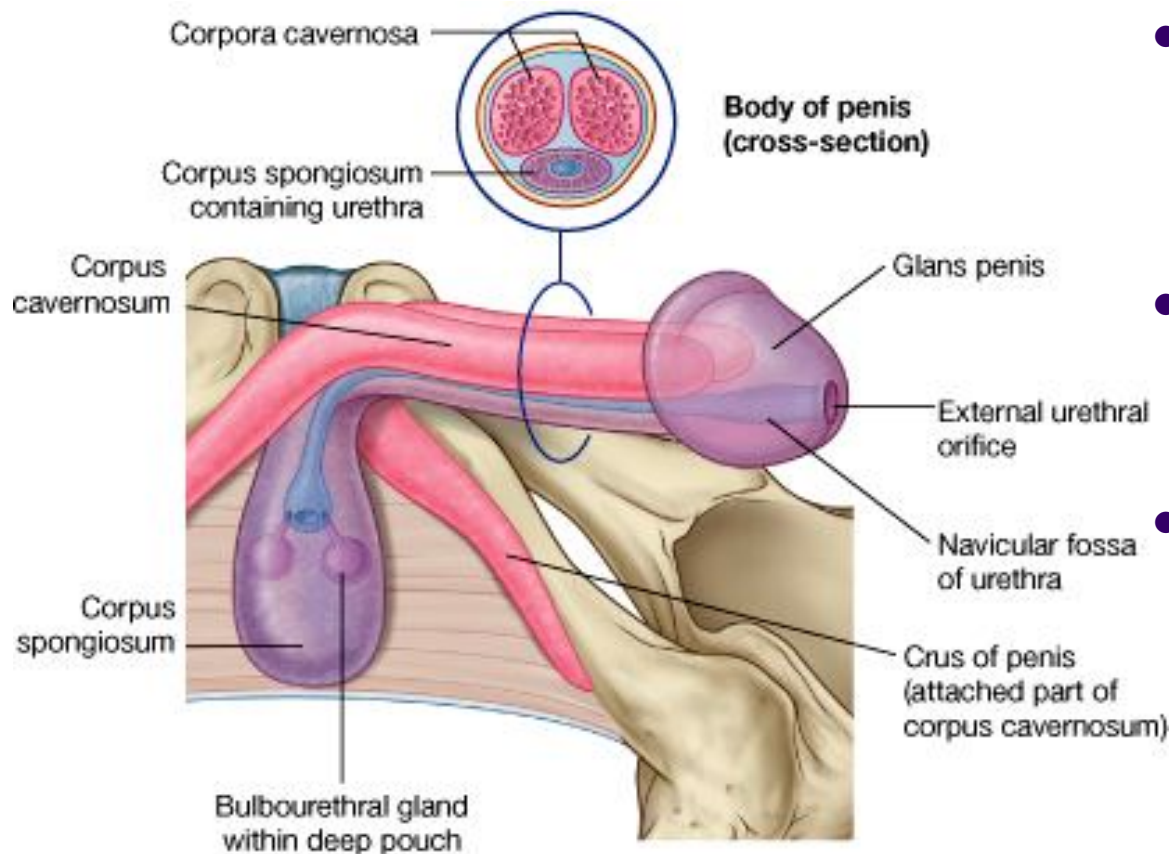


Membranous part



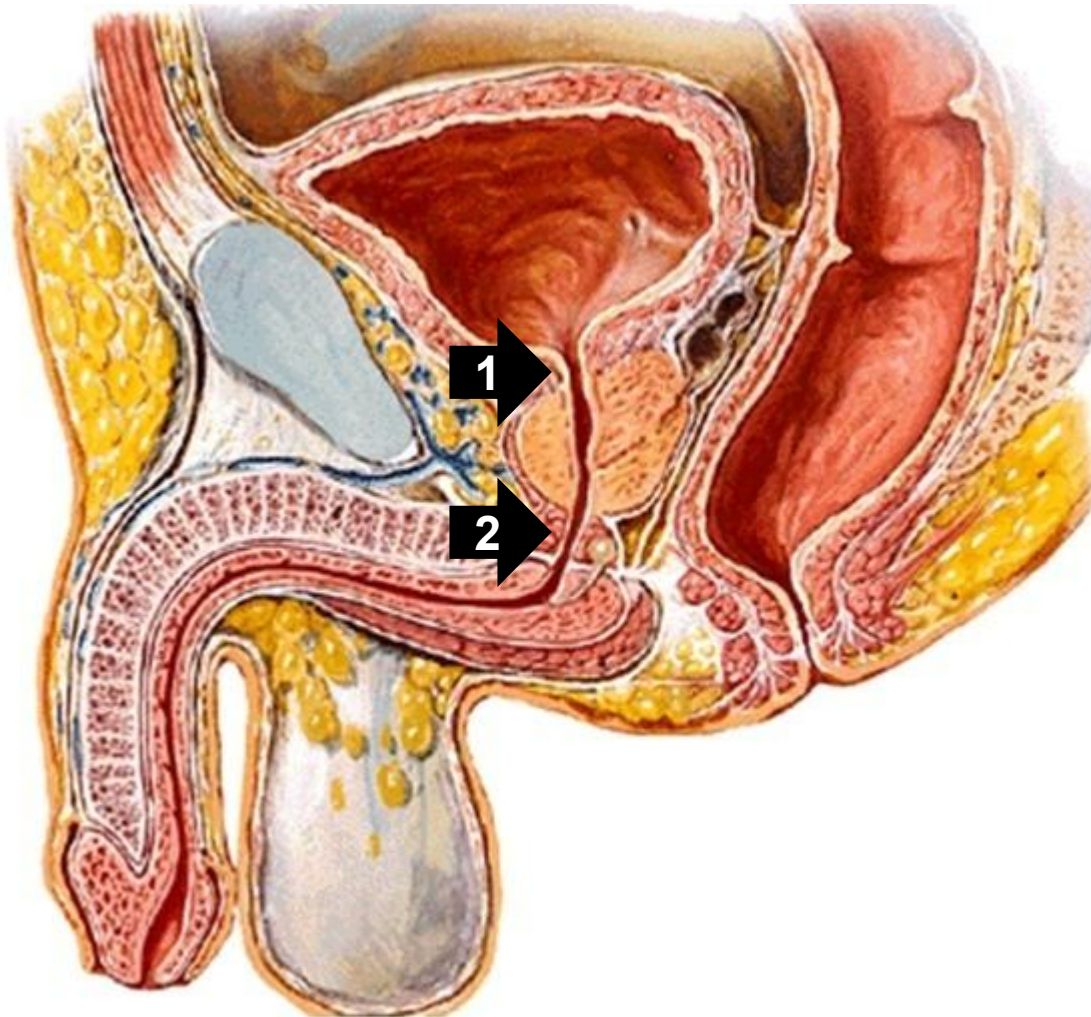
- Passes through the **urogenital diaphragm** to enter the bulb of the penis
- It is the **shortest, narrowest** and the least dilatable part
- It is surrounded by the **external sphincter urethra**
- **Bulbourethral glands** lie posterolateral to this part inside of urogenital diaphragm (**deep perineal pouch**)

Spongy part



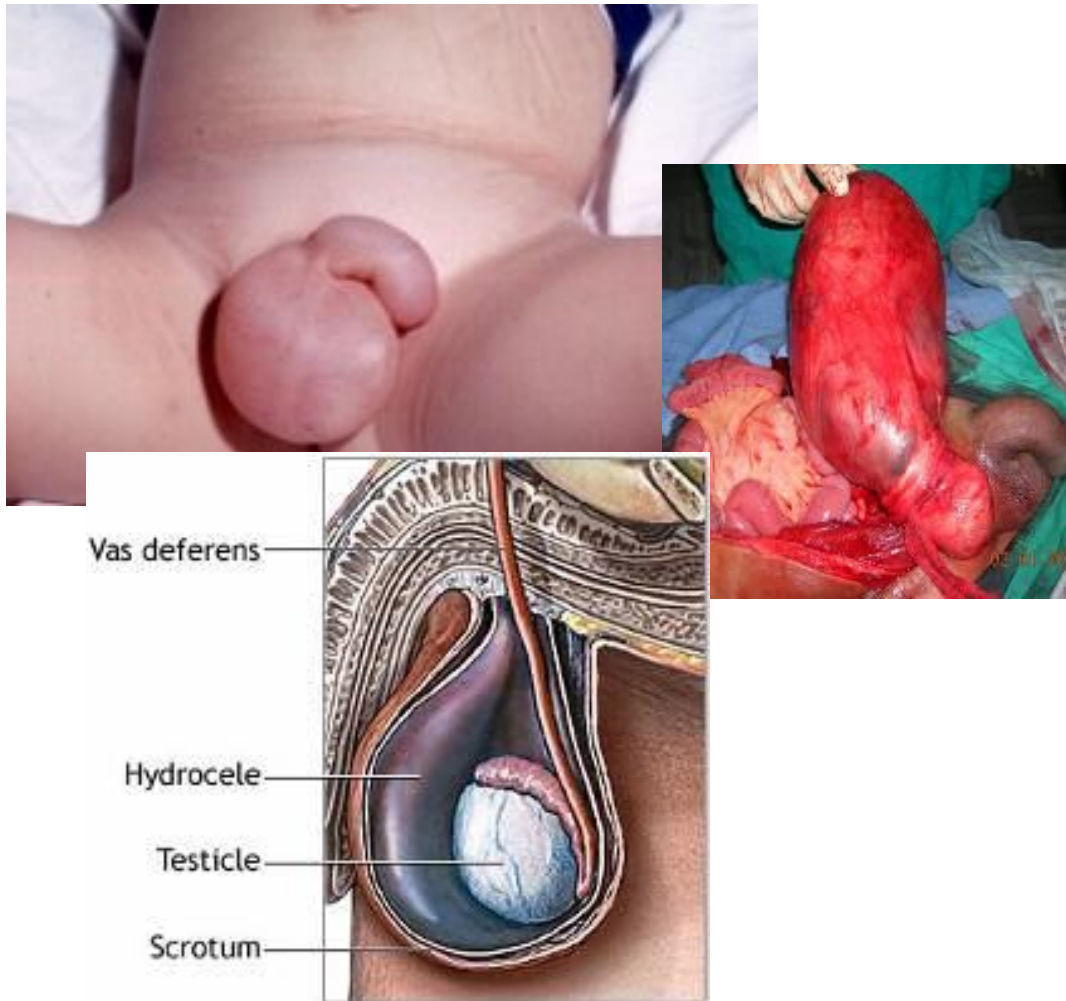
- Average 15 cm in length.
- Passes through the bulb and corpus spongiosum of the penis to open at the external urethral orifice on the tip of the glans penis.
- There are two dilatations – **bulbar fossa** (in the beginning) and **navicular fossa** (in the glans penis)
- Ducts of the bulbourethral glands open into the floor of the spongy part in its beginning

Sphincters of the urethra



1. **Internal** urethral sphincter is made of **smooth** muscles in the neck of the **bladder** and has **sympathetic** innervation
2. **External** urethral sphincter has **skeletal muscle fibers** and surrounds the **membranous** part of **urethra**, supplied by the perineal branch of the **pudendal nerve**

62. Hydrocele & hematocele

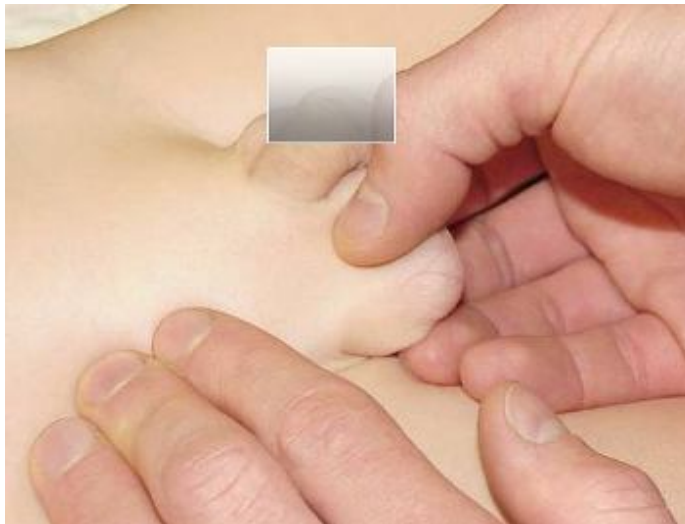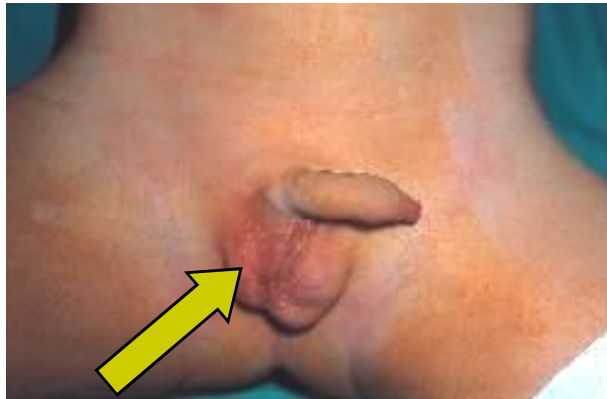


The **tunica vaginalis** testis or other remnants of the processus vaginalis may form a **hydrocele** or **hematocele**.

- **With transillumination, a hydrocele produces a reddish glow**, whereas light will not penetrate other scrotal masses such as a **hematocele**, solid tumor, or **herniated bowel**.



63. Cryptorchism



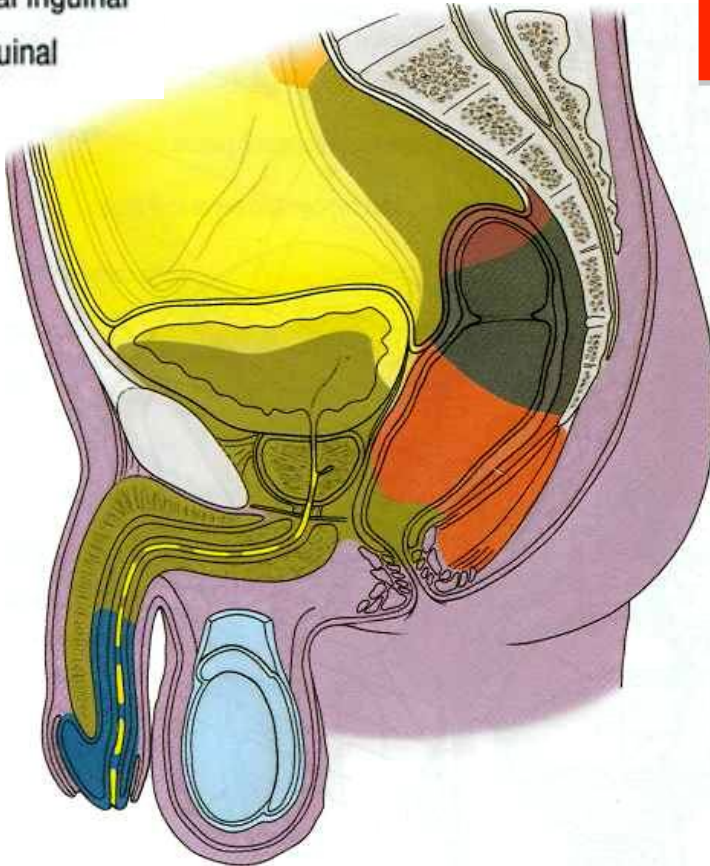
- **Undescended testes (cryptorchism)** occurs when the **testes fail to descend** into the scrotum. This normally occurs within **3 months** after birth.
- The undescended testes may be found in the abdominal cavity or in the **inguinal canal**.
- If neglected, **malignant transformation** may occur in the undescended testis.
- **N.B.** In case of cryptorchism, **spermatogenesis is arrested** and the spermatogenic tissue is damaged leading to permanent **sterility in bilateral** cases.

64. Lymphatic drainage of the male viscera




Lymph nodes:

-  Lumbar (caval/aortic)
-  Internal iliac
-  External iliac
-  Superficial inguinal
-  Deep inguinal



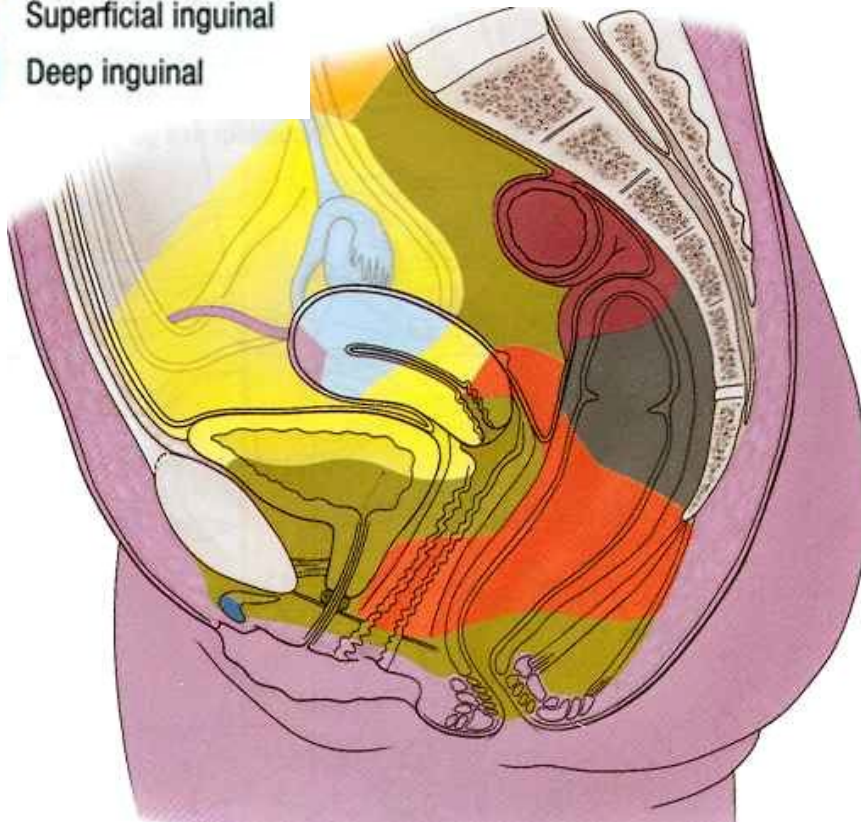
- **Testis & epididymis** – **lumbar** lymph nodes
- **Scrotum** – **superficial inguinal** nodes
- **Penis:**
 - skin - **superficial inguinal** nodes
 - glans – **deep inguinal** nodes
 - body and roots – **internal iliac** nodes
- **Prostate gland & bladder** - **internal iliac** nodes
- **Anal canal:**
 - above pectinate line - **internal iliac**
 - below pectinate line - **superficial inguinal** nodes

65. Lymphatic drainage from the female viscera



Lymph nodes:

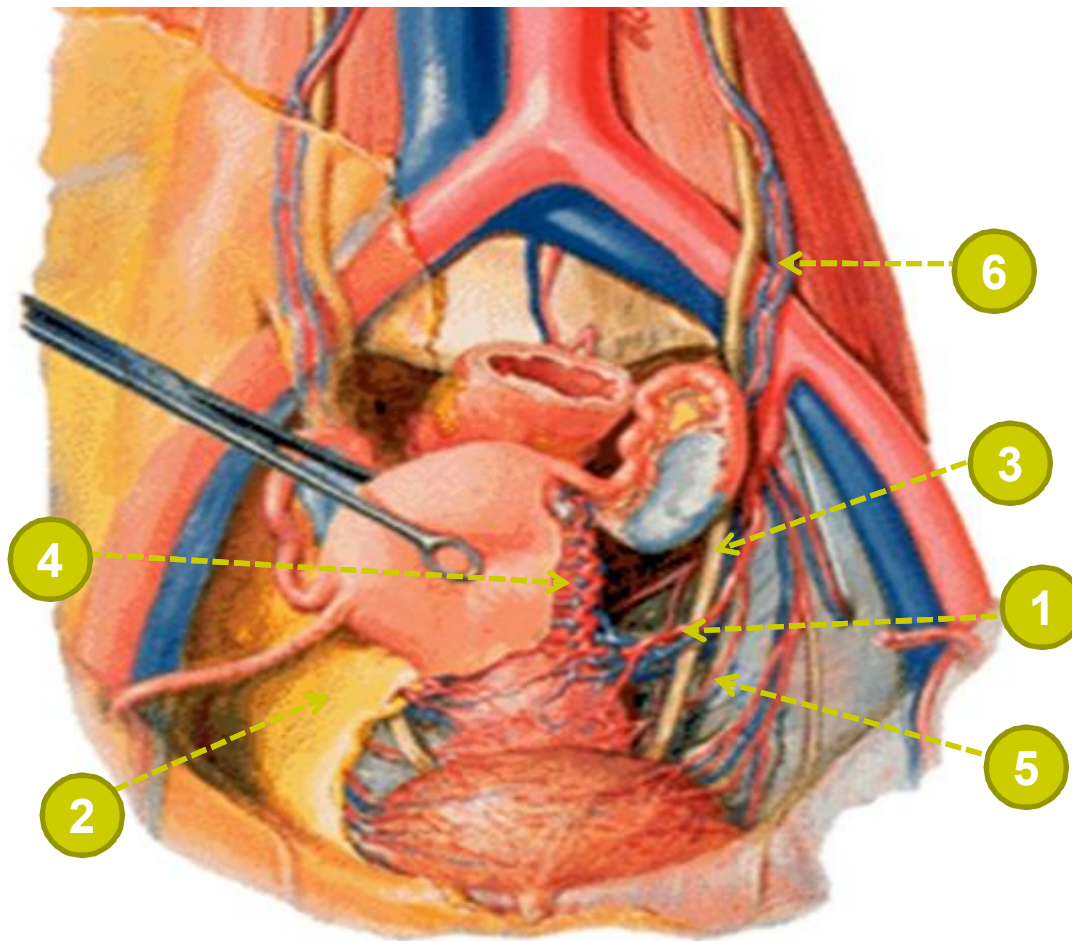
-  Lumbar (caval/aortic)
-  Internal iliac
-  External iliac
-  Superficial inguinal
-  Deep inguinal



- **Ovary and uterine tubes** – to **lumbar** lymph nodes
 - **Uterus:**
 - **lateral angle** and teres ligament – **superficial inguinal** lymph nodes
 - **fundus** and **upper** part of the **body** - **lumbar** lymph nodes
 - **lower** part of the **body** - **external iliac** lymph nodes
 - **cervix** - **external** & **internal iliac**
 - **Vagina:**
 - Superior to hymen - to **external** & **internal iliac**
 - Inferior to hymen - to **superficial inguinal** nodes
- All external genitalia** (with exception - glans clitoris) - **superficial inguinal** lymph nodes
- **Glans clitoris** – **deep inguinal**



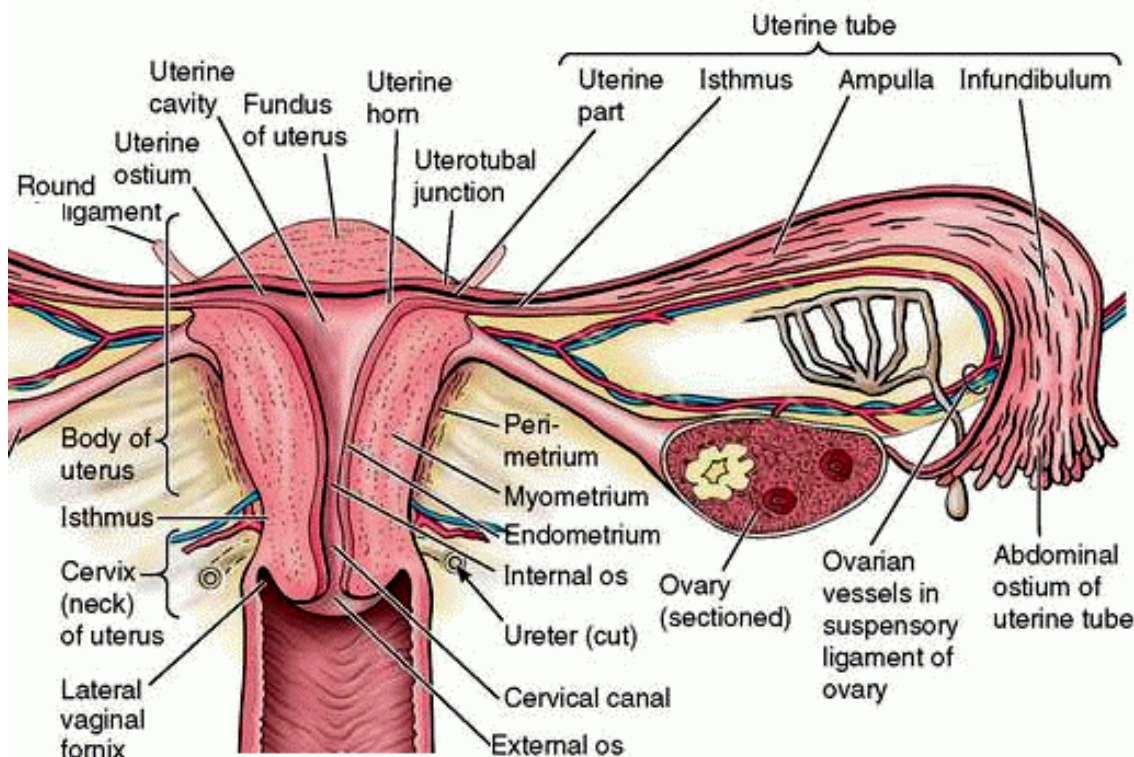
66. Arterial supply of the uterus



The **uterus** is almost exclusively supplied by the **uterine arteries** [1] (from **internal iliac artery**):

- Crosses pelvic floor in **transverse cervical ligament** on the base of **broad ligament** [2]
- Near uterus, passes superior and anterior to **ureter** [3]
- Ascends along **lateral wall** [4] of uterus within broad ligament
- Vaginal branch anastomoses with **vaginal artery** [5]
- Ovarian branch anastomoses with **ovarian artery** [6]

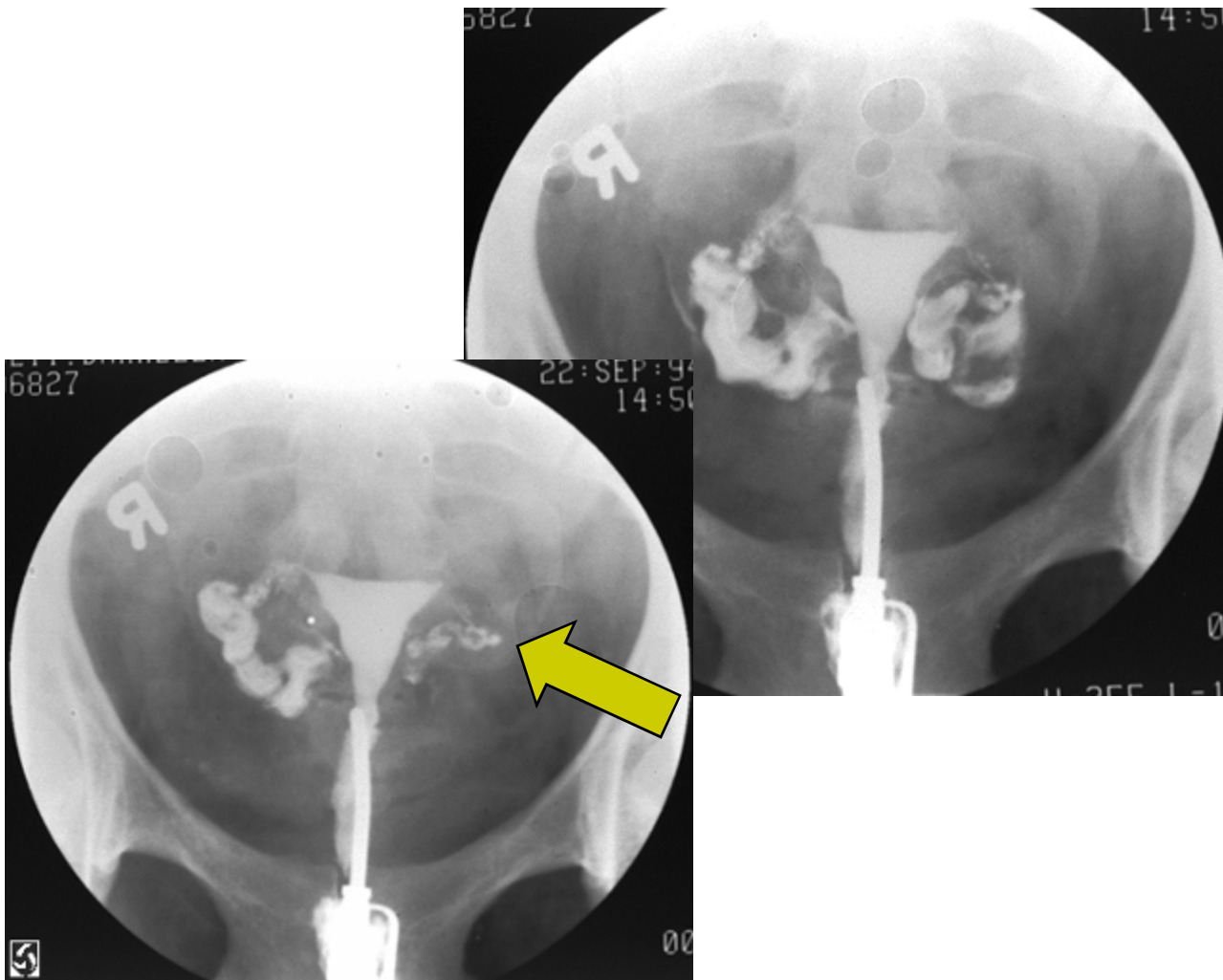
67. Parts of the uterine tube



uterus is amped w fun!

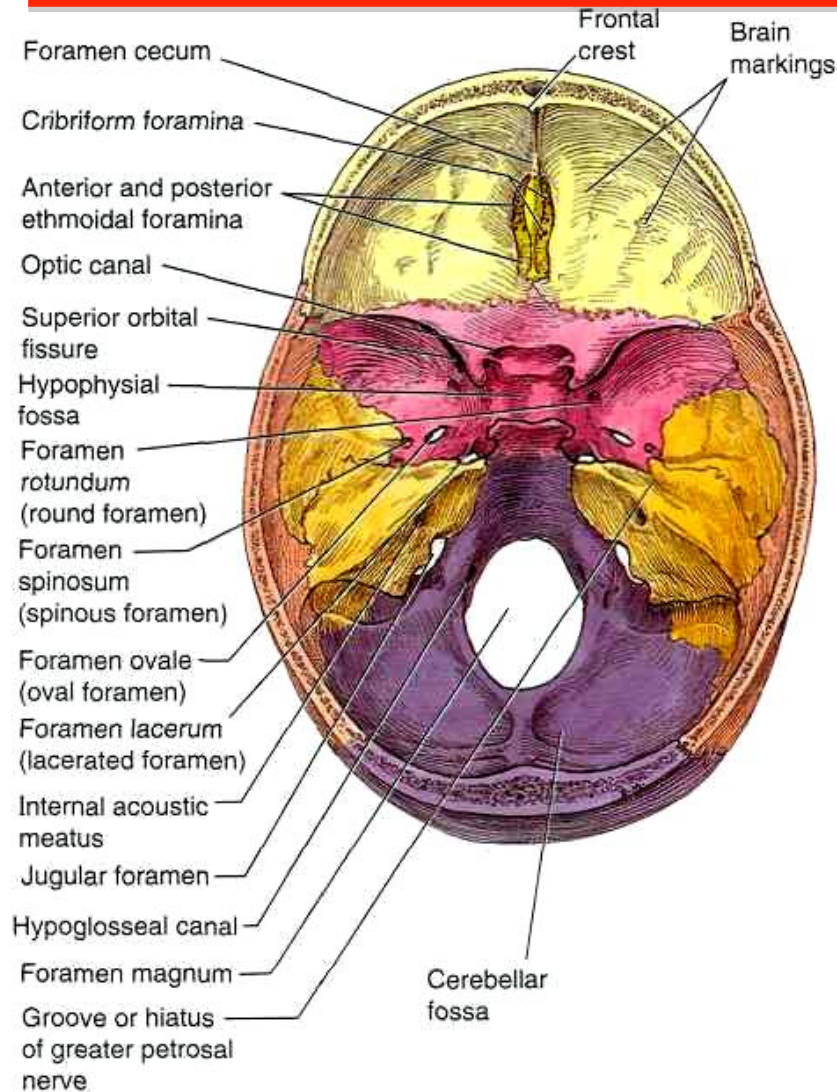
- **Uterine part**
 - Pierces uterine wall to open into uterine cavity
- **Isthmus**
 - Narrowest part of tube just lateral to uterus
- **Ampulla**
 - Medial continuation of infundibulum comprising about half of uterine tube
 - Usual site of fertilization
- **Infundibulum**
 - Funnel-shaped expansion of lateral end, fringed with fimbriae
 - Overlies ovary and **receives oocyte** at ovulation

Hysterosalpingography

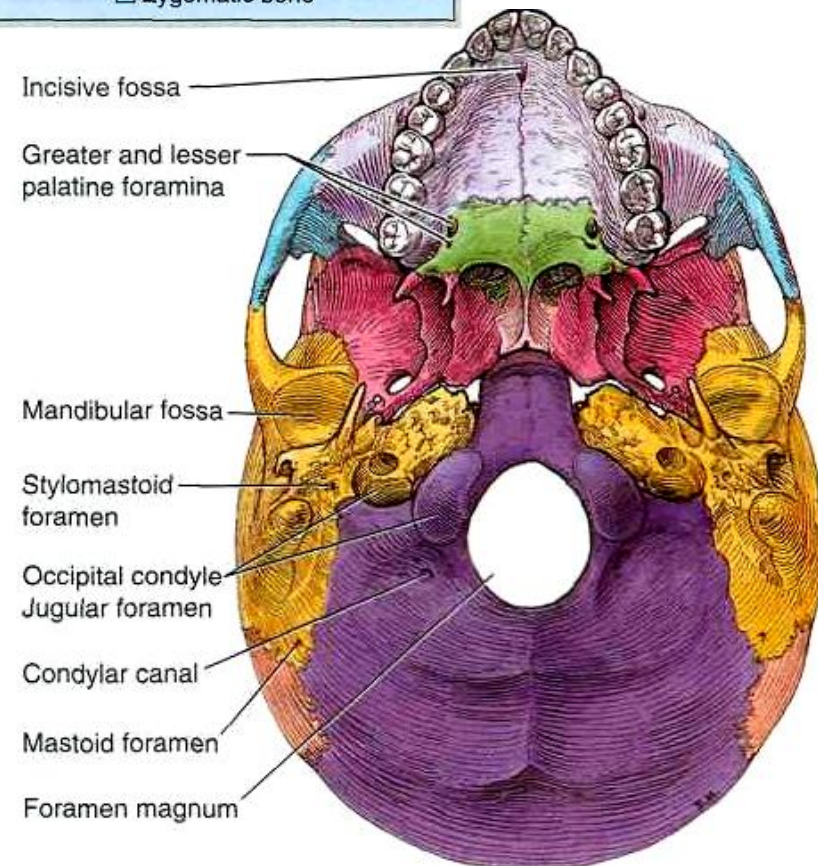


- The **instillation of viscous iodine through the external os of the uterine cervix** allows the lumen of the **cervical canal**, the **uterine cavity**, and the different parts of the **uterine tubes** to be visualized on X-ray.

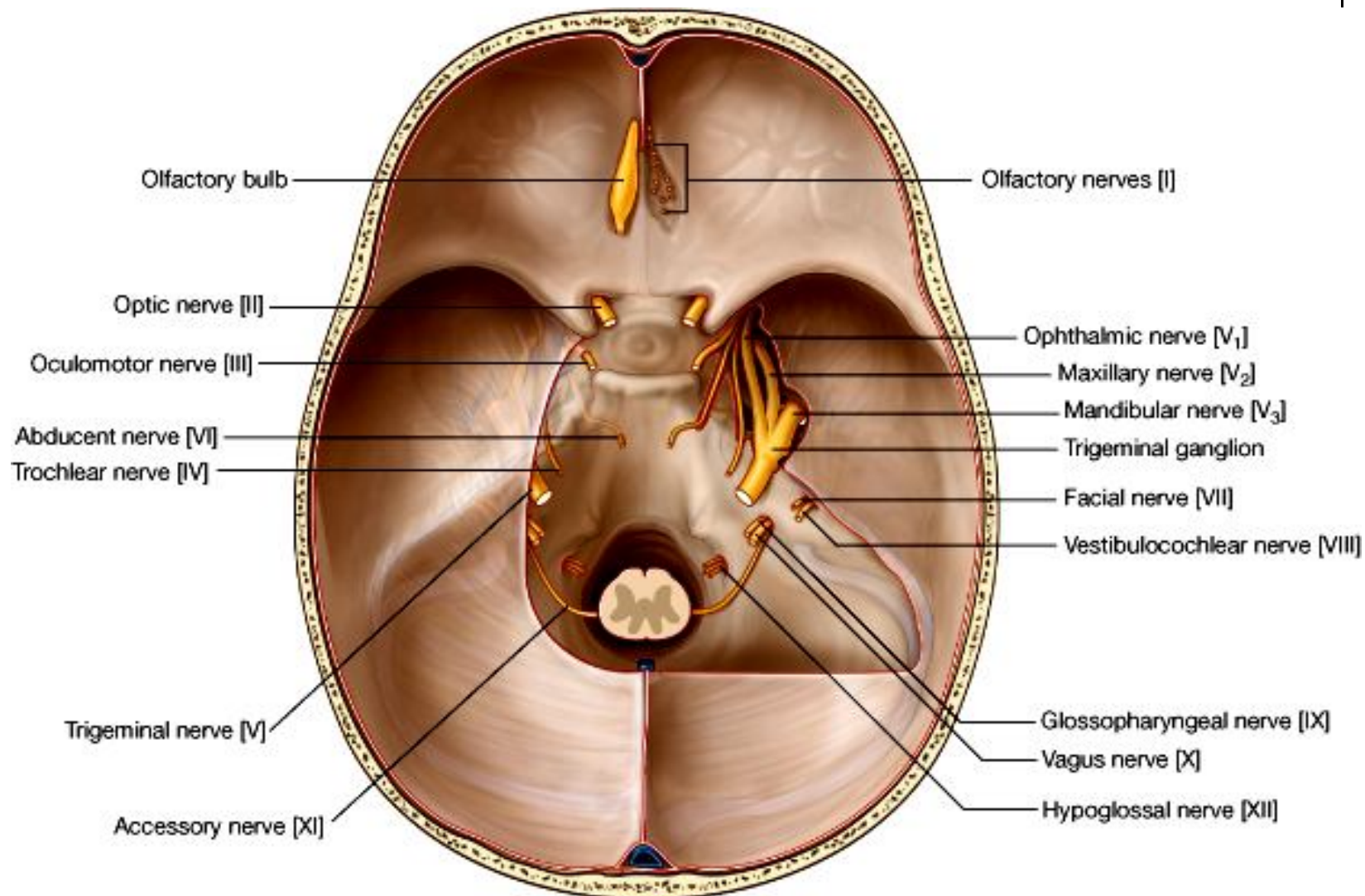
68. Foramina of the base of the skull



Bones	
Frontal bone	Temporal bone
Parietal bone	Occipital bone
Ethmoid bone	Maxillary bone
Sphenoid bone	Palatine bone
Zygomatic bone	



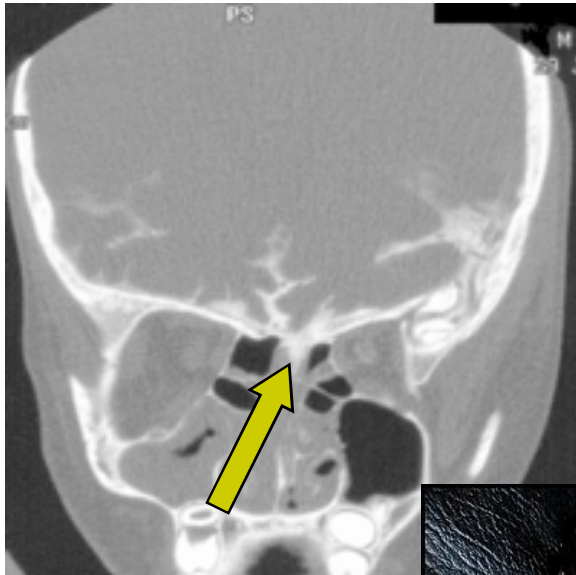
Exit of cranial nerves



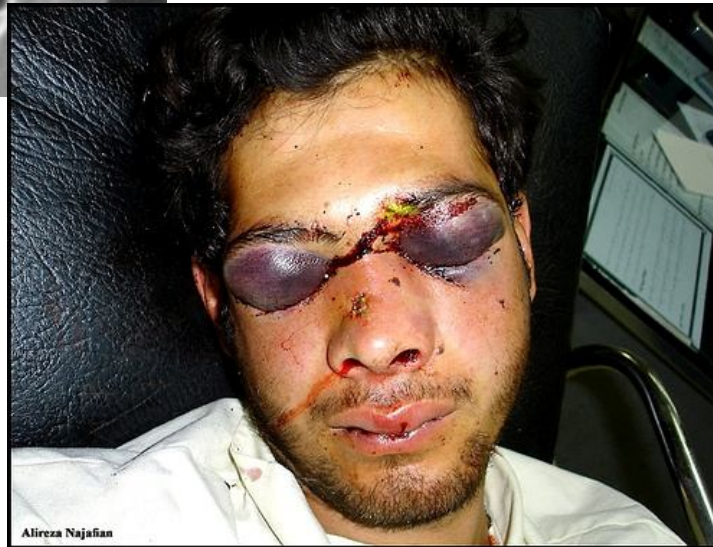© Elsevier. Drake et al: Gray's Anatomy for Students - www.studentconsult.com

Dr. Mavrych, MD, PhD, DSc prof.mavrych@gmail.com

69. Fracture of the anterior cranial fossa



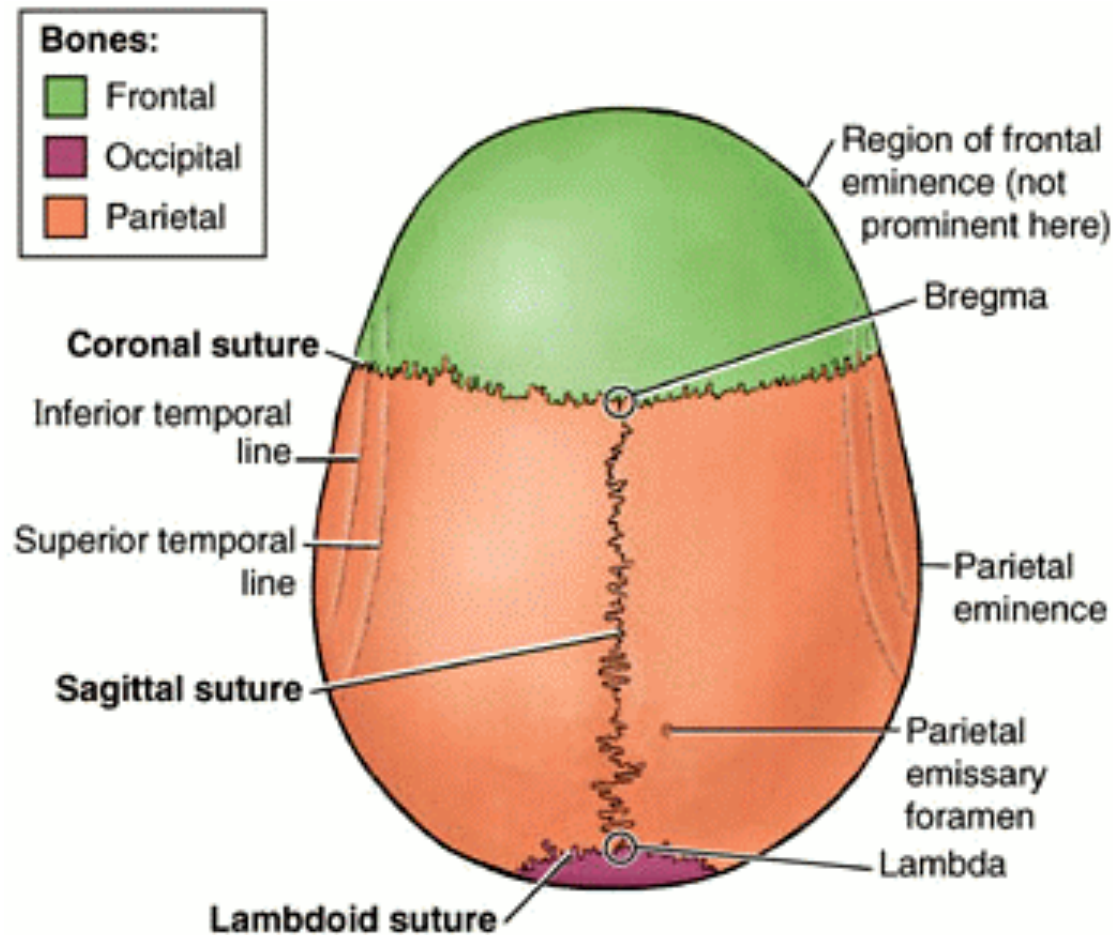
- Fracture of the anterior cranial fossa (cribriform plate of the Ethmoid bone) is suggested by **anosmia**, **periorbital bruising** (raccoon eyes), and **CSF leakage** from the **nose** (**rhinorrhea**).





70. Development of skull

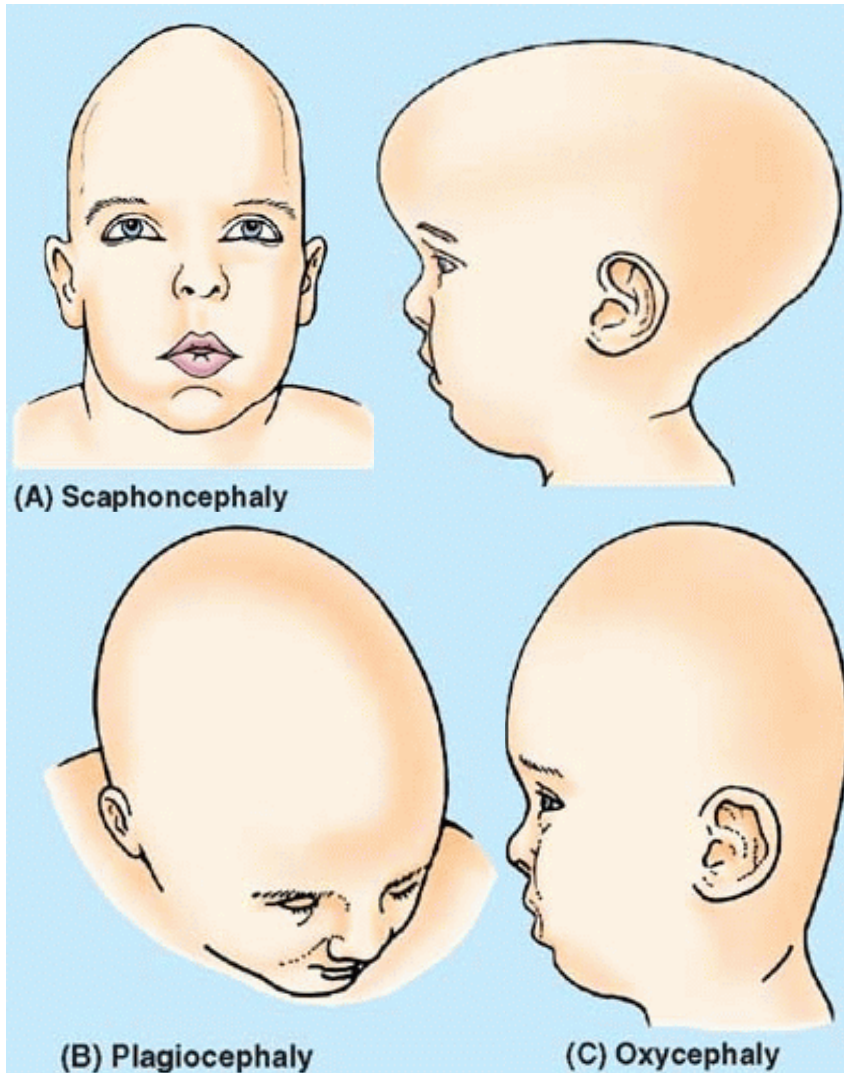
Sutures of neurocranium



- **Coronal suture**: lies between the frontal bone and the two parietal bones.
- **Sagittal suture**: lies between the two parietal bones.
- **Squamous suture**: lies between the parietal bone and the squamous part of the temporal bone.
- **Lambdoid suture**: lies between the two parietal bones and the occipital bone.

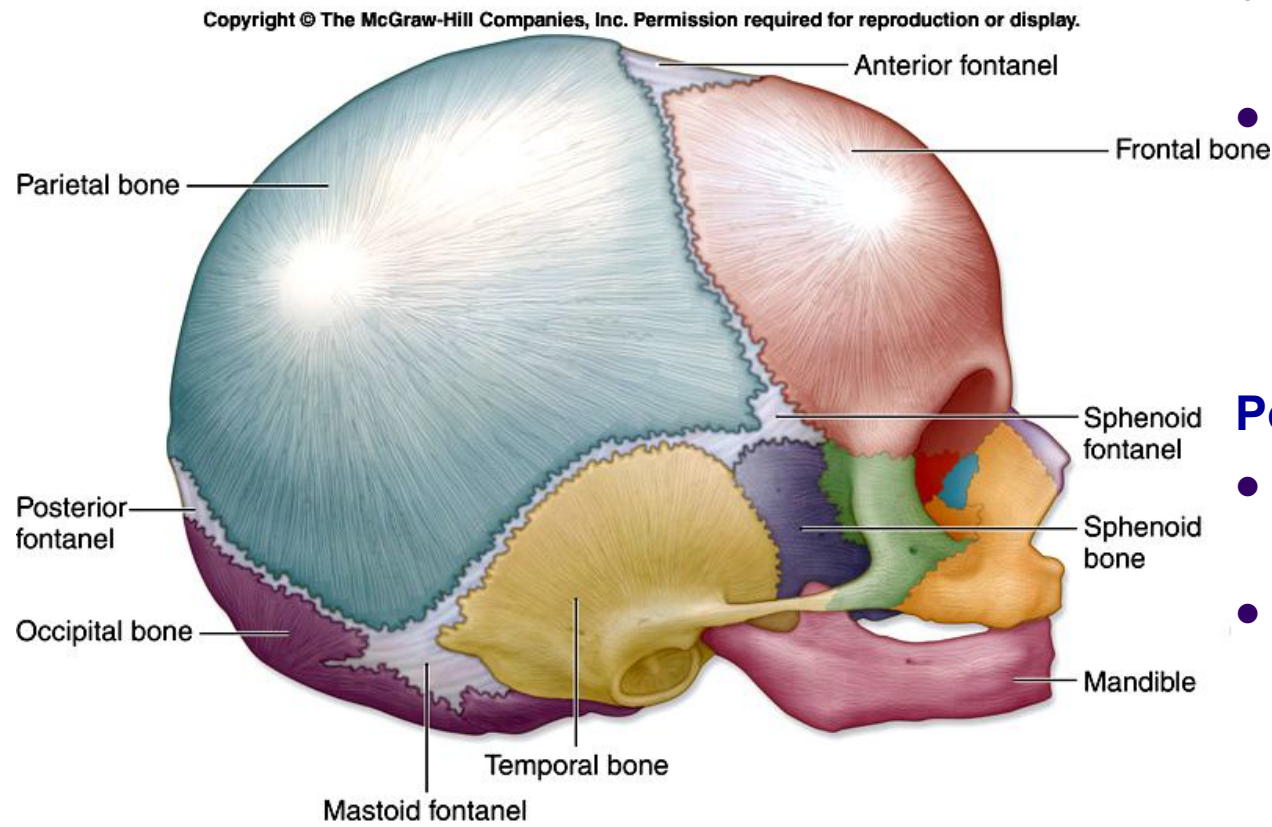


Cranial Malformations



- [A] **Scaphocephaly**: premature closure of the **sagittal suture**, in which the anterior fontanelle is small or absent, results in a **long, narrow, wedge-shaped** cranium.
- [C] **Oxycephaly**: premature closure of the **coronal suture** results in a **high, tower-like** cranium.
- When premature closure of the coronal or the lambdoid suture occurs on **one side only**, the cranium is twisted and asymmetrical, a condition known as **plagiocephaly [B]**.

Fontanelles



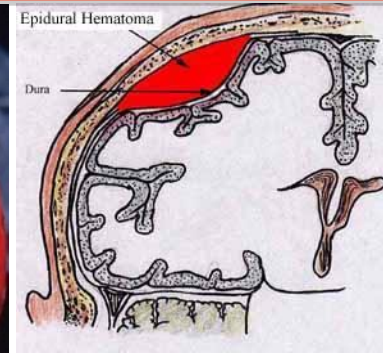
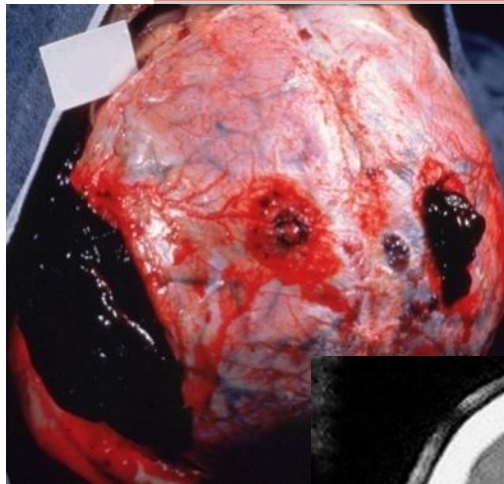
Anterior fontanelle

- present at birth; closes at age **9 to 18 months**
- diminished size or absence at birth may indicate **craniosynostosis** or **microcephaly**.

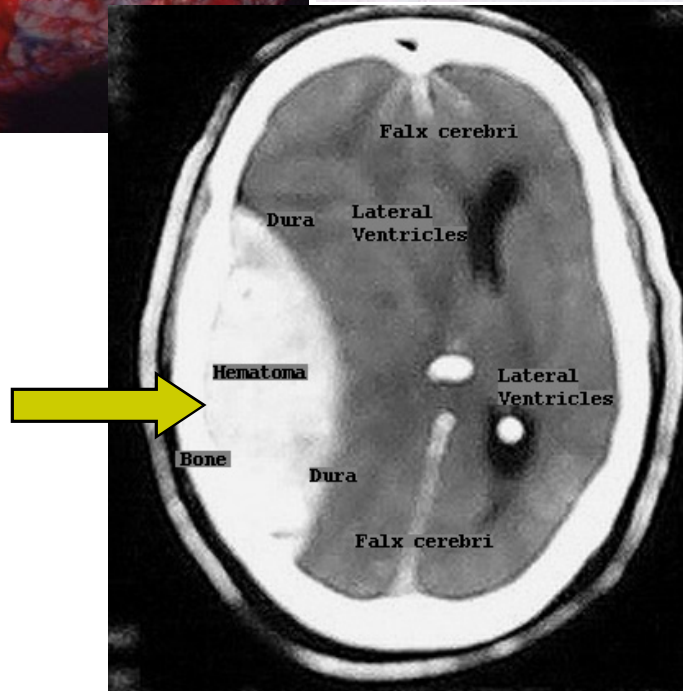
Posterior fontanelle

- present at birth; usually closes by age **2 months**
- Persistence suggests underlying **hydrocephalus** or congenital **hypothyroidism**.

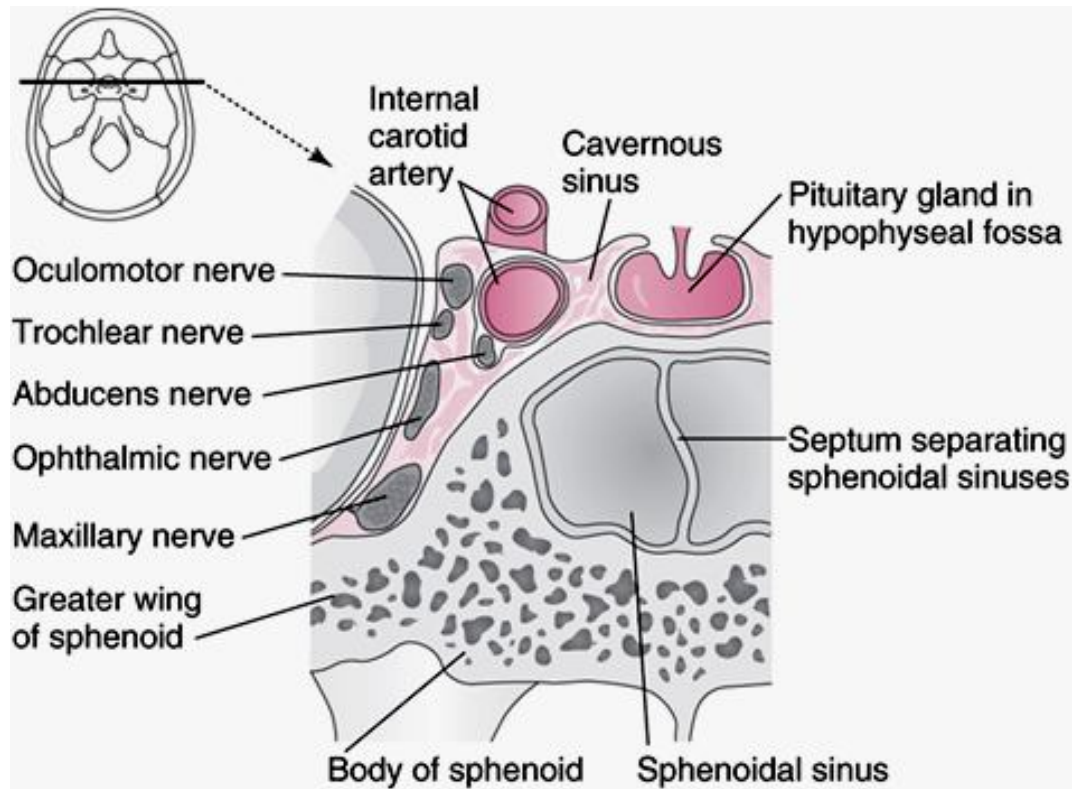
74. Epidural hematoma



- Skull fracture near **pterion** often causes epidural hematoma from torn **middle meningeal artery**.
- Unconsciousness and **death** are **rapid** because the bleeding dissects a **wide space** as it strips the dura from the inner surface of the skull, which puts pressure on the brain.
- An epidural hematoma forms a characteristic **biconvex pattern** on computed tomography images.



75. Infection of the Cavernous sinus

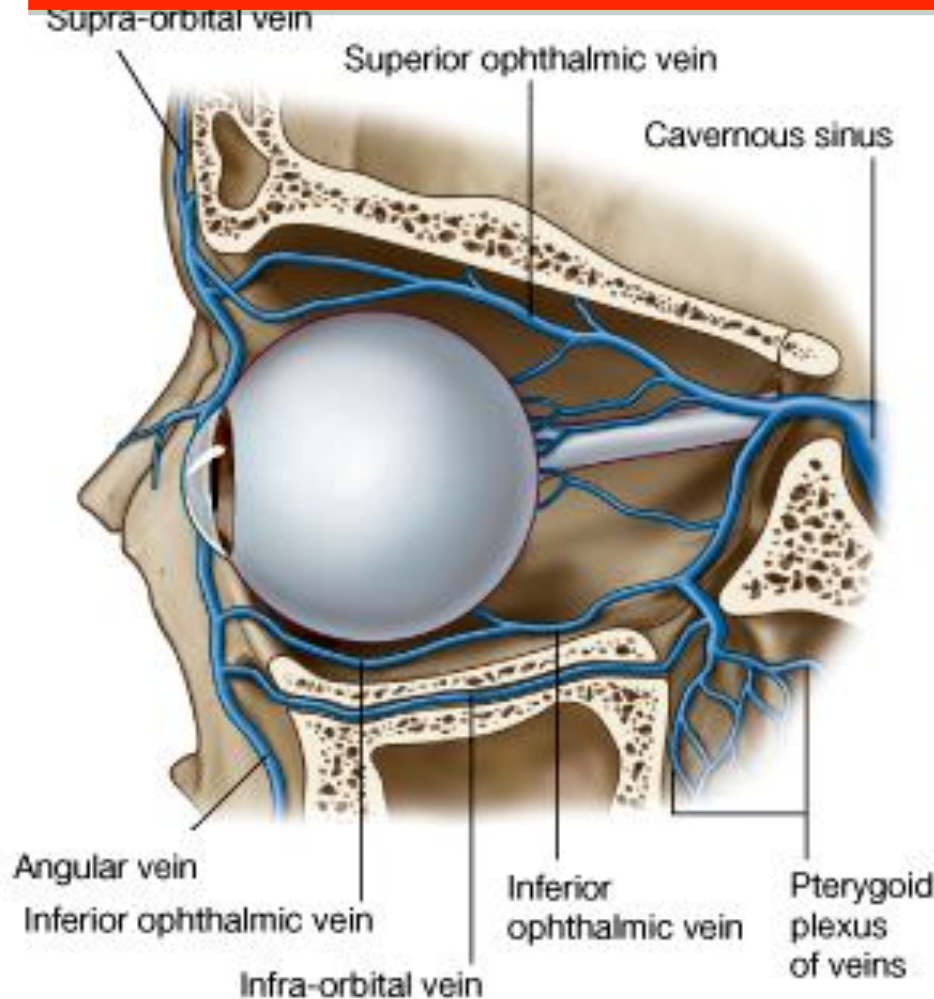


- Lateral to body of sphenoid bone and sella turcica, forming lateral wall of hypophyseal fossa

Related structures:

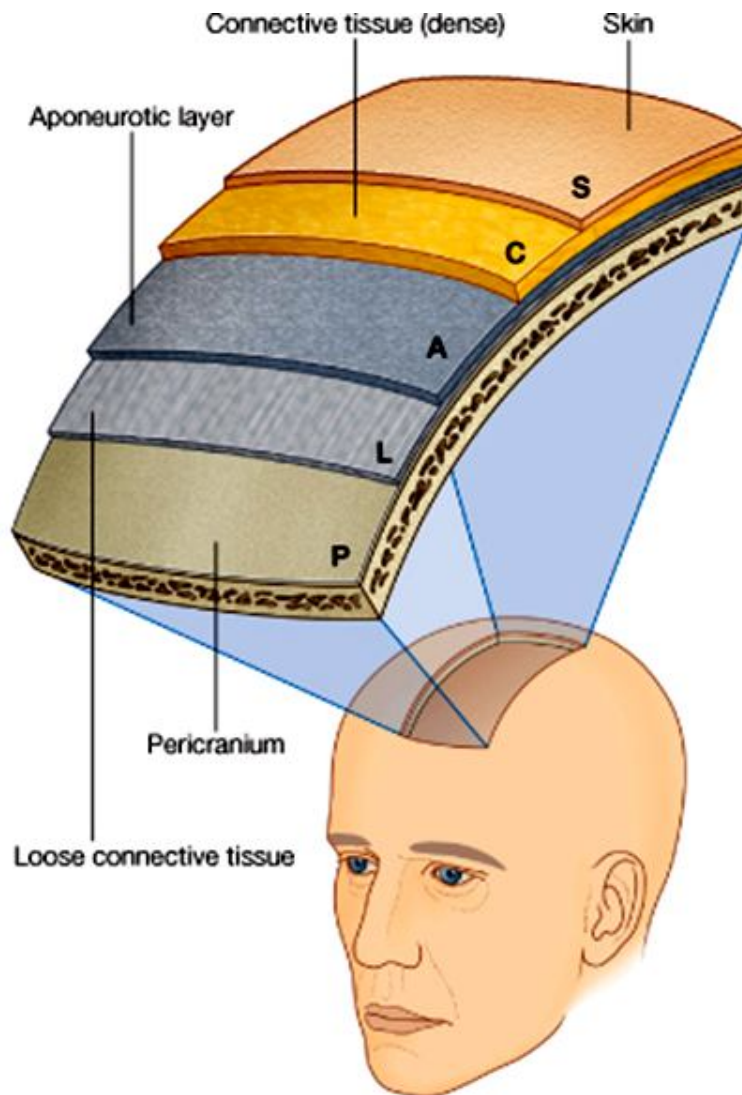
- Structures that pass **through** sinus:
 1. **Internal carotid artery** and internal carotid plexus
 2. **Abducens nerve** (CN VI)
- Structures on lateral wall of sinus:
 1. **Oculomotor nerve** (CN III)
 2. **Trochlear nerve** (CN IV)

Ophthalmic Veins



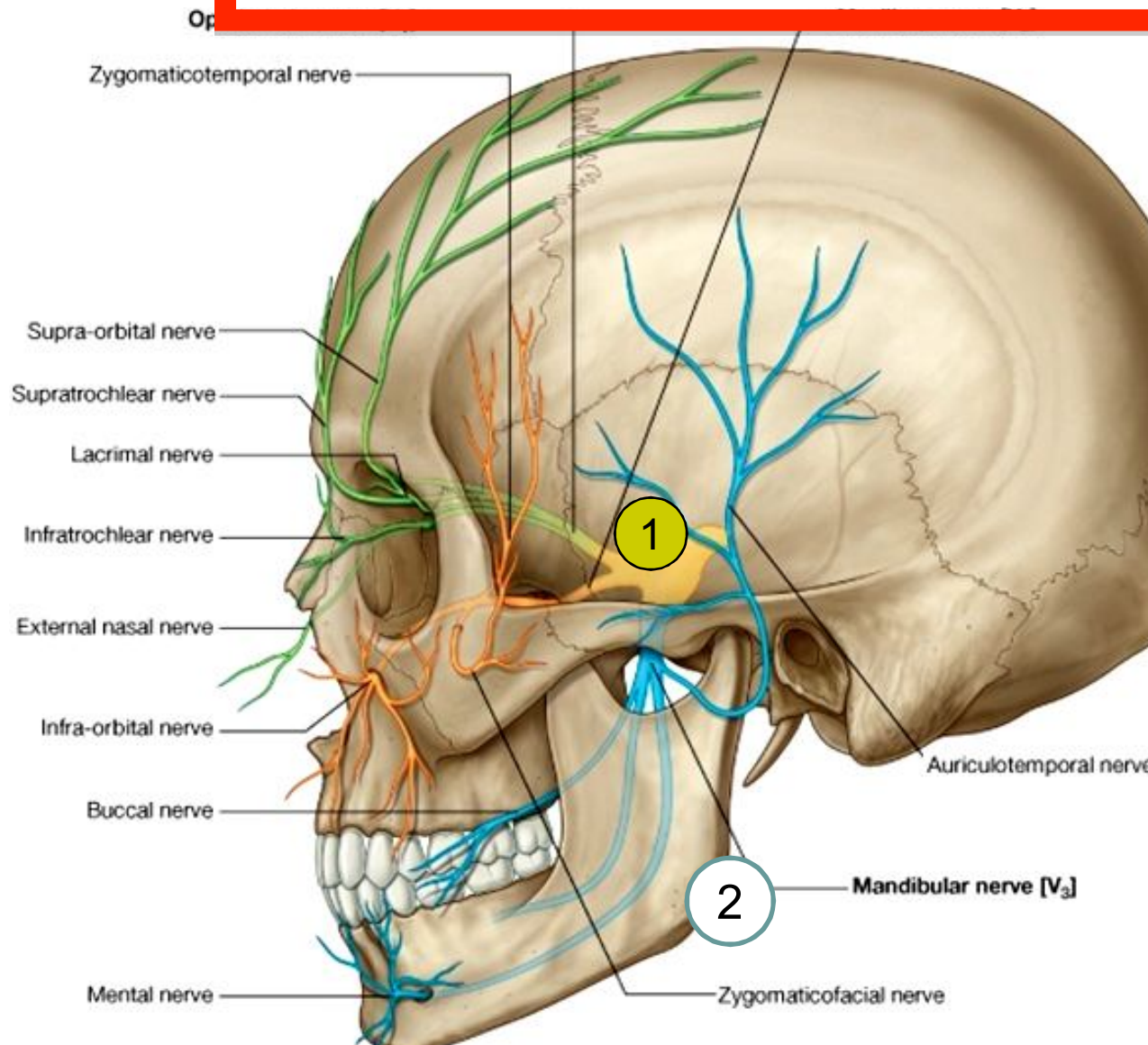

- **Superior ophthalmic vein** – communicates anteriorly with the **facial (angular) vein**
- **Inferior ophthalmic vein** – communicates through the inferior orbital fissure with the **pterygoid plexus** of veins
- ❖ **Both veins** pass posteriorly through the superior orbital fissure and **drain into the Cavernous sinus**

76. Layers of the scalp



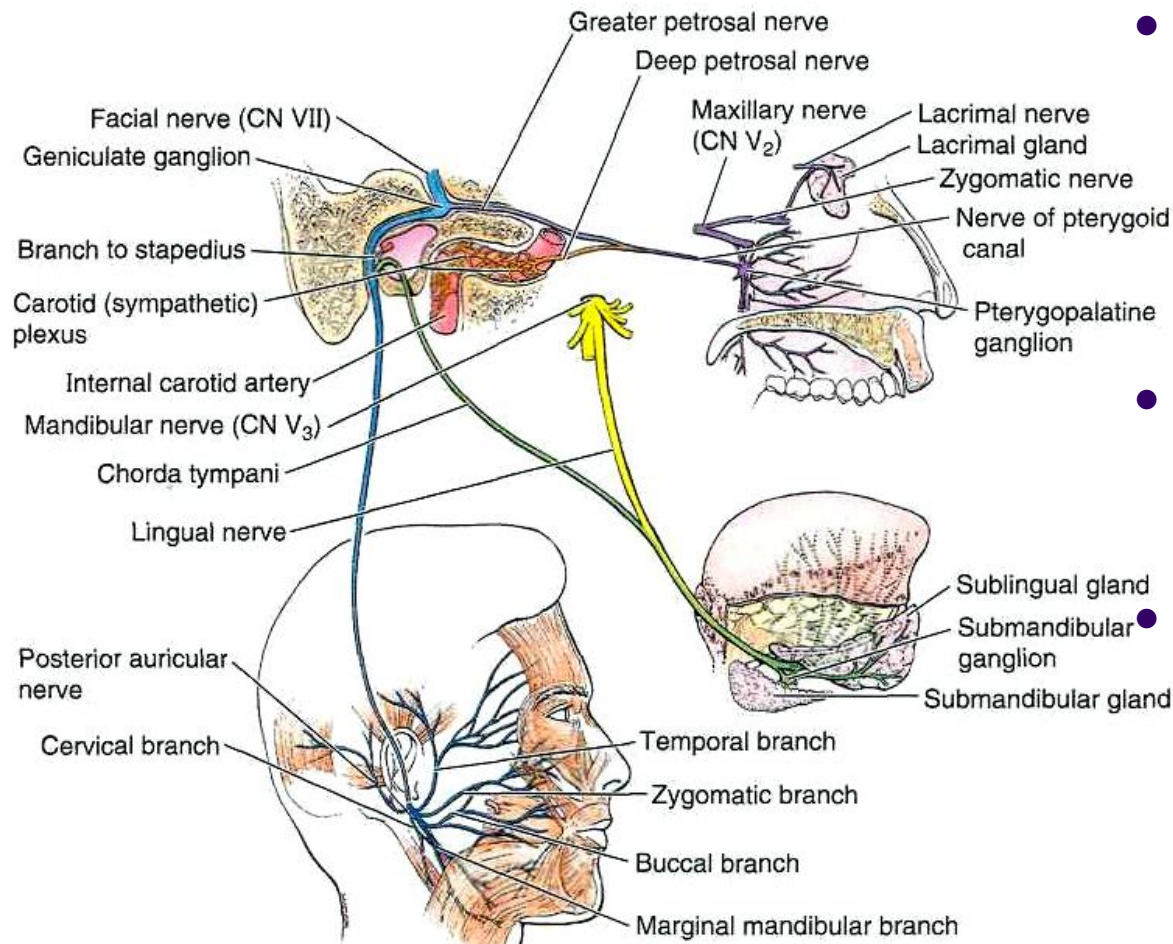
1. **Skin** - contains numerous sweat glands, **sebaceous glands**, and hair follicles
2. **Connective tissue- Dense** superficial fascia containing nerves and **blood vessels**
3. **Aponeurosis** (Epicranial) -Fibrous epicranial aponeurosis connecting frontalis and occipitalis parts of **occipitofrontalis** muscle
4. **Loose areolar tissue** -Allows 3 more superficial layers **to move** over skull surface; somewhat like a sponge because it contains innumerable **potential spaces** capable of being distended with fluid resulting from **injury or infection**
5. **Pericranium -periosteum** covering the outer surface of the skull bones

77 Innervation skin of the face



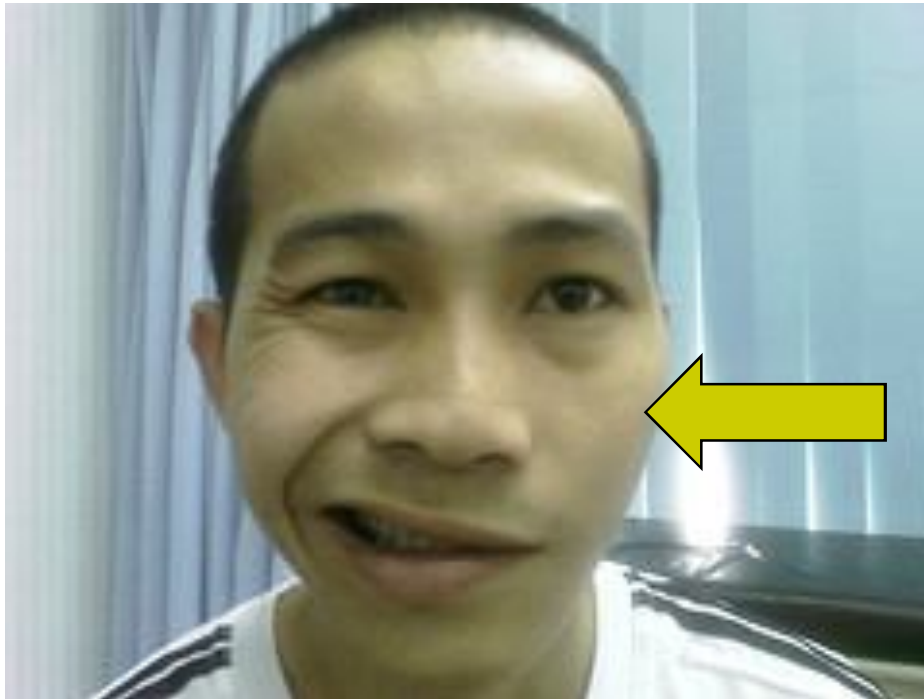- Skin of face supplied by branches of the three divisions of the **[1] TRIGEMINAL NERVE (CN V)**
- **Except** for a small area over the **angle of the mandible** which is supplied by the **[2] great auricular nerve (C2-C3) – cervical plexus**

78. Facial nerve (CN VII)



- **FACIAL NERVE (CN VII)** - sole **motor supply** to the **muscles of facial expression** and certain other muscles derived from the embryonic 2nd pharyngeal arch
- **Sensory to the taste** buds in **anterior 2/3 of the tongue** through the **chorda tympani**
- **Secretomotor** (parasympathetic) to the **submandibular, sublingual, palatine** salivary glands, glands of nasal cavity and **lacrimal gland**

Bell's palsy



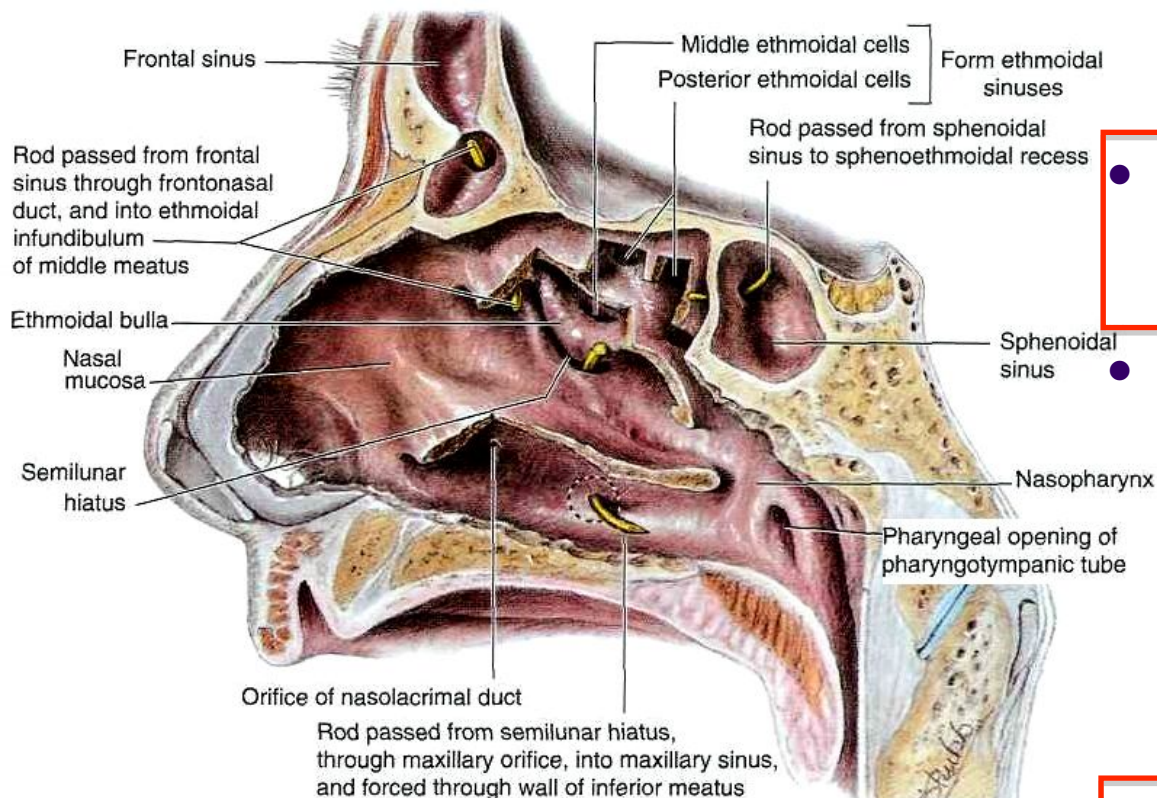
- It is idiopathic **unilateral facial paralysis** (constitutes **75%** of all facial nerve lesions)
- Terminal branches of **CN VII** may be injured by **parotid cancer** or by **surgery** to remove a **parotid tumor**.
- An **infant's** facial nerve may be injured during a **forceps delivery** because the **mastoid** process has **not yet** developed and the stylomastoid foramen is relatively superficial.



Lesions of CN VII

- Symptoms associated with **lesions of CN VII** are determined by the **location** of the lesion in the nerve.
- **Bels Manifestations:**
 - unable to **close** lips and eyelids on affected side
 - eye on affected side is **not lubricated (dry eye)**
 - unable to **whistle**, blow a wind instrument, or chew effectively
 - facial distortion due to contractions of **unopposed** contralateral facial muscles
- A lesion within the facial canal will also affect **taste** from the **anterior 2/3 of the tongue** carried by the **chorda tympani** and **loss of secretion** from **submandibular** and **sublingual** glands ipsilateral to the lesion

79. Communication of the paranasal sinuses



- **Sphenoethmoidal recess**

- receives the opening of the **sphenoidal** air sinus

- **Superior meatus**

- Receives opening of **posterior ethmoidal** air cells

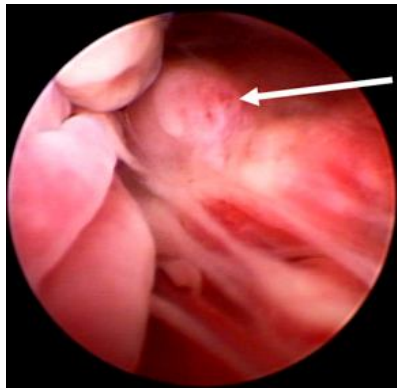
- **Middle meatus**

- Infundibulum, ethmoidal bulla and semilunar hiatus
- Receives openings of **frontal** and **maxillary** sinuses and **anterior** and **middle ethmoidal** air cells

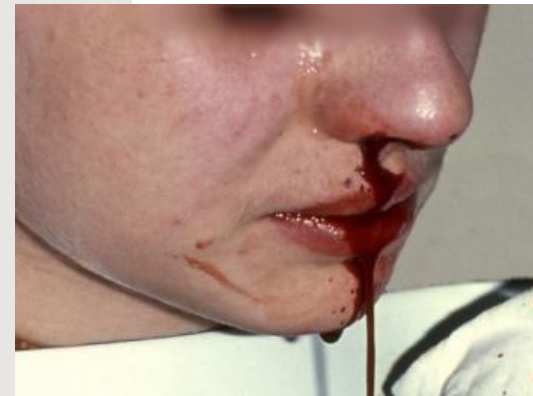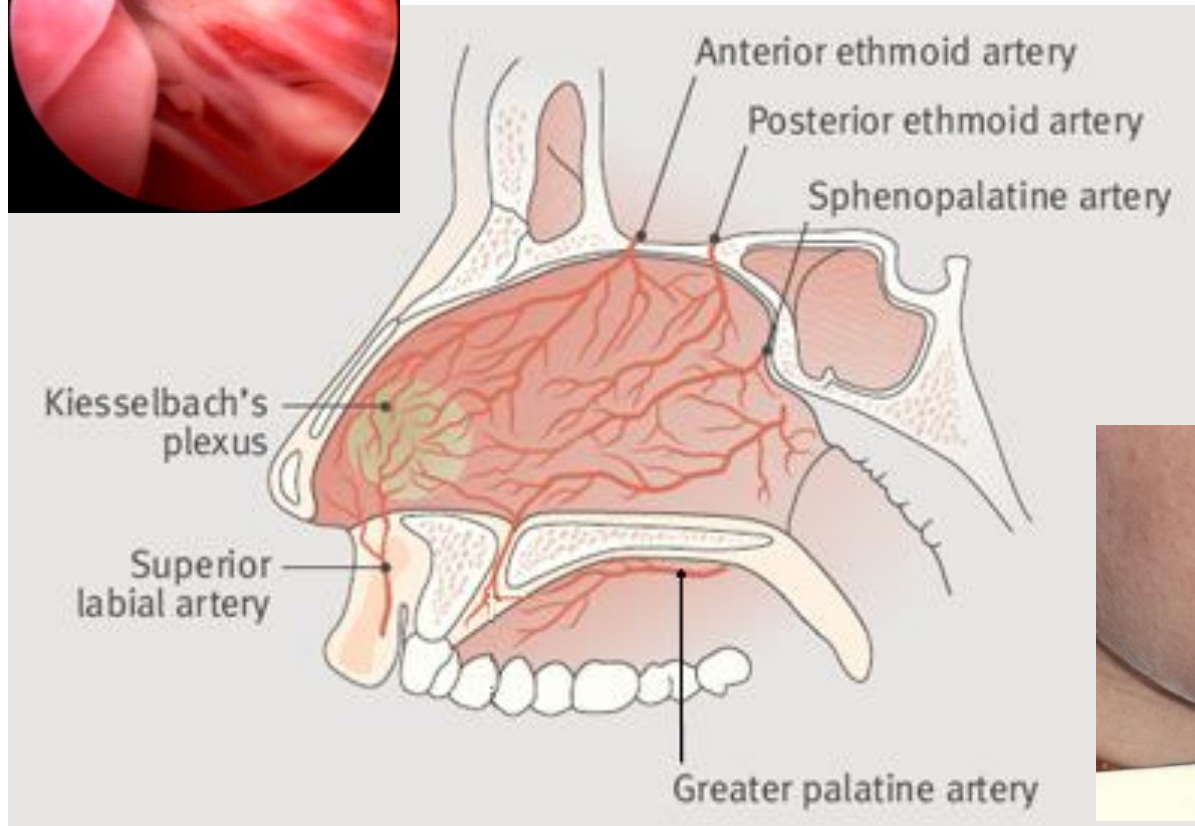
- **Inferior meatus**

- Receives opening of **nasolacrimal** duct

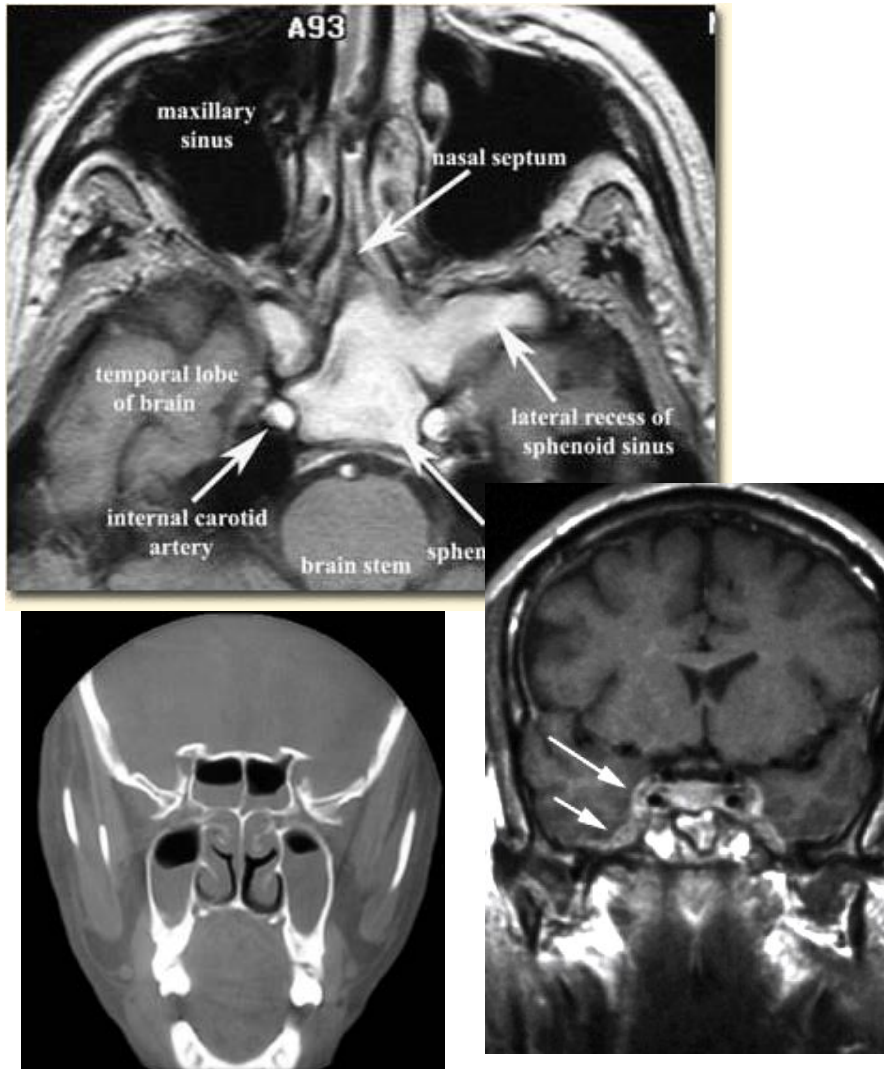
80. Epistaxis



- **Epistaxis** (nosebleed) most often occurs from the anterior nasal septum (**Kiesselbach's area**), where branches of the **sphenopalatine**, **anterior ethmoidal**, **greater palatine**, and **superior labial** (from facial) arteries converge.

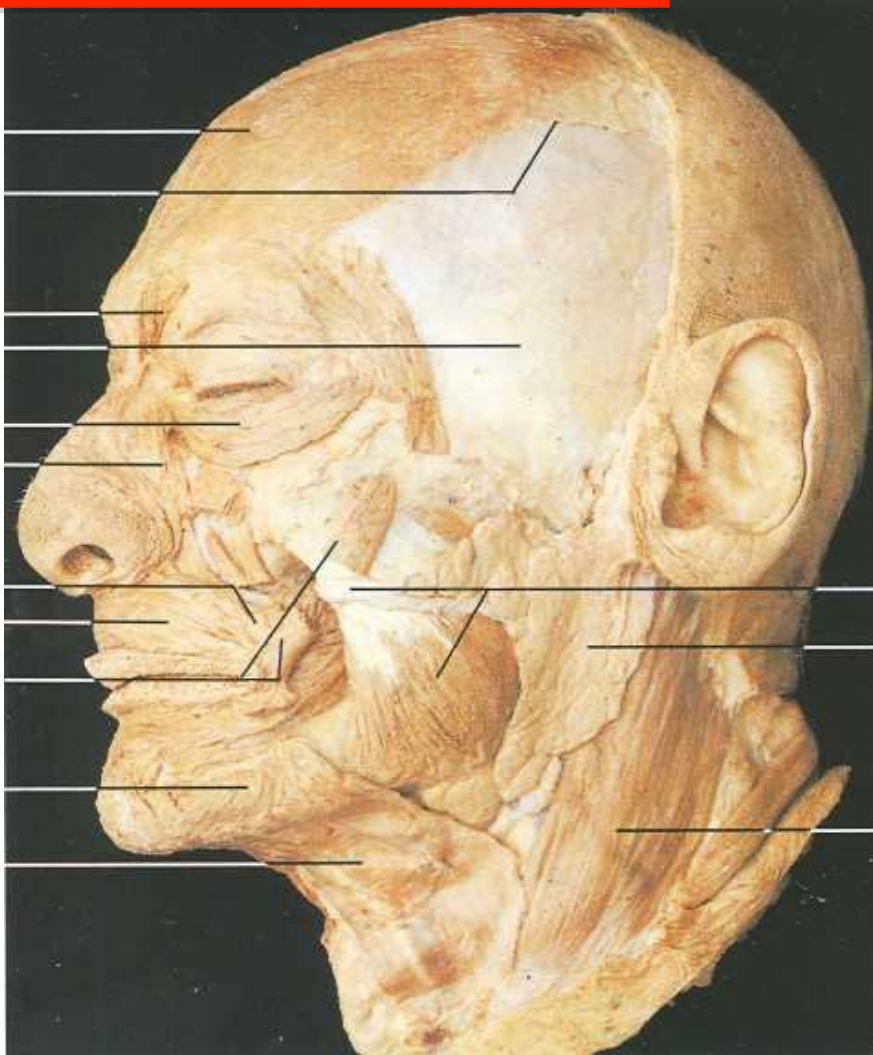


81. Sphenoiditis



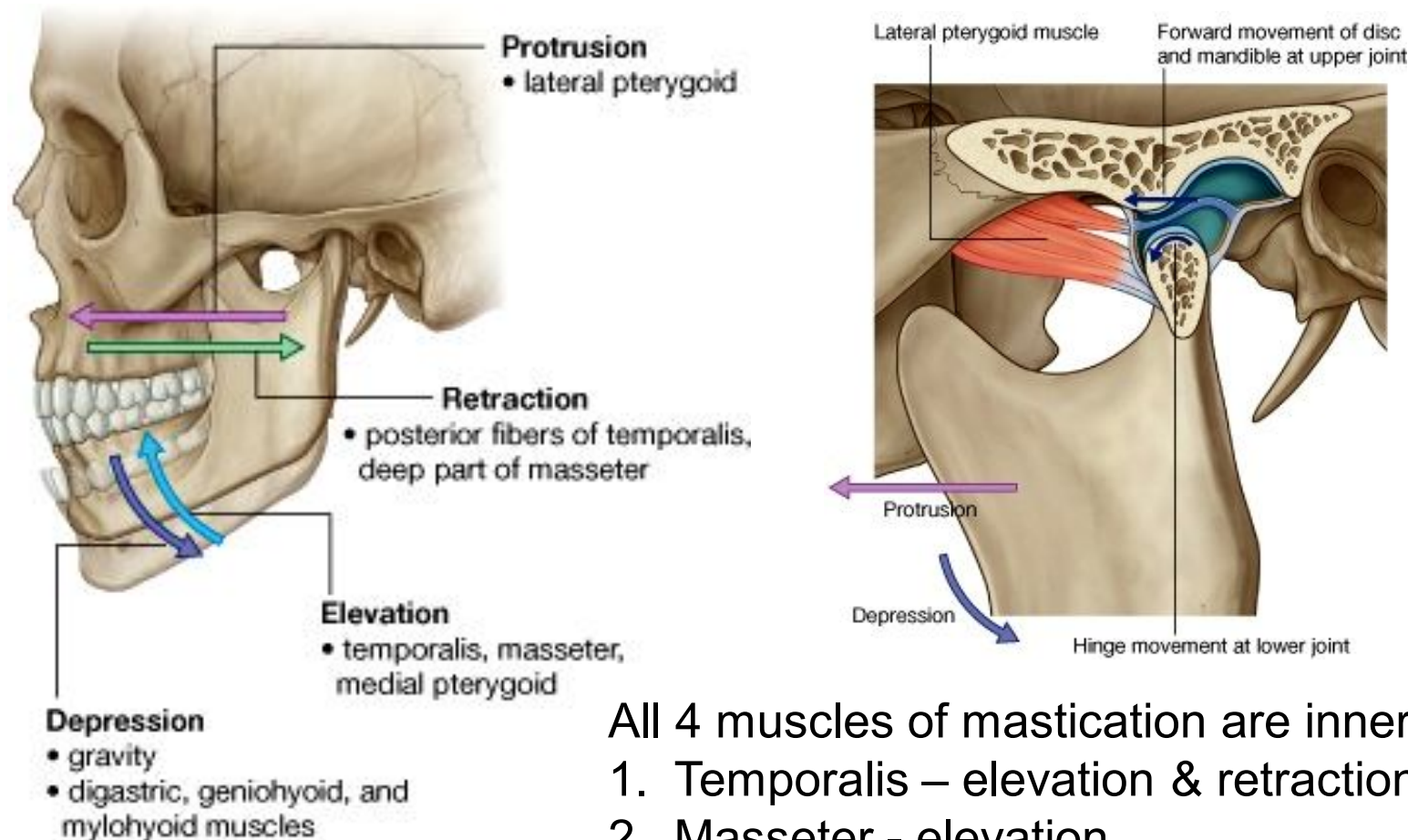
- Relationships of the **sphenoidal sinus** are clinically important ; because of potential **injury during pituitary surgery** and the possible **spread of infection**.
- Infection can reach the sinuses through their ostia from the **nasal cavity** or through their floor from the **nasopharynx**.
- Infection may erode the walls to reach the cavernous sinuses, **pituitary gland**, **optic nerves**, or **optic chiasma**

82. Cheeks



- Form the **lateral, movable walls** of the oral cavity and the zygomatic prominences of the cheeks over the **zygomatic** bones
- **Buccinator** – principal muscle of the cheek
- **Buccal pad of fat** – encapsulated collection of fat superficial to buccinator
- **Parotid duct** opens in inner surface of the cheek right **opposite 2nd upper molar** tooth

83. Movements at the TMJs

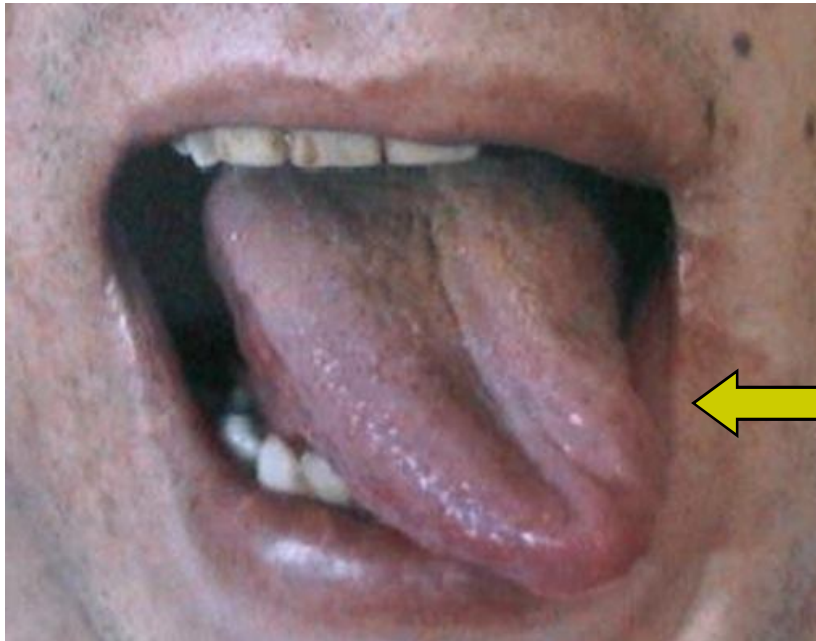

All 4 muscles of mastication are innervated by **V3**:

1. Temporalis – elevation & retraction
2. Masseter - elevation
3. Medial pterygoid - elevation
4. **Lateral pterygoid - protrusion**

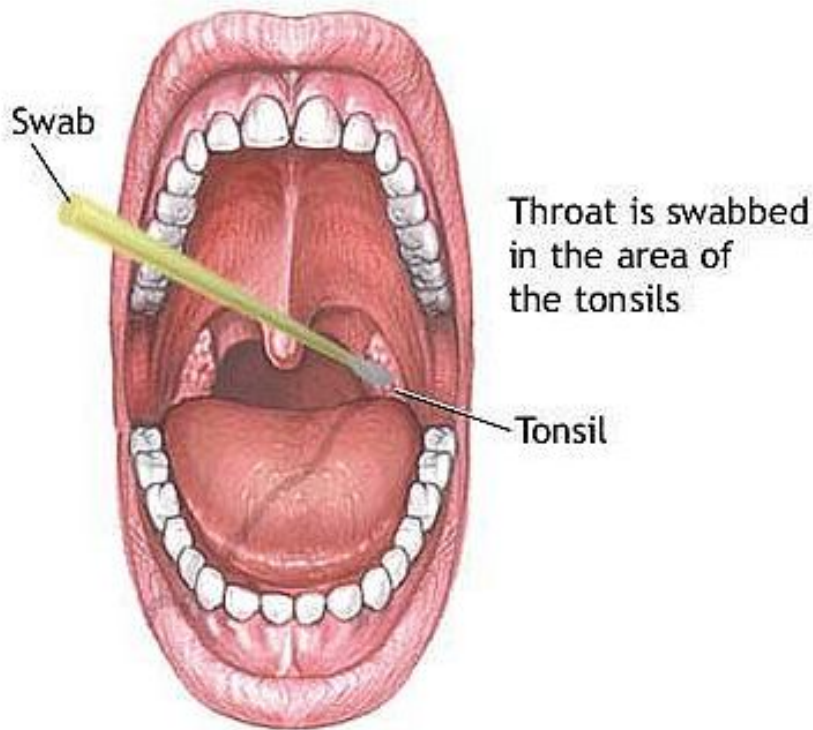


84. Lesion of CN XII



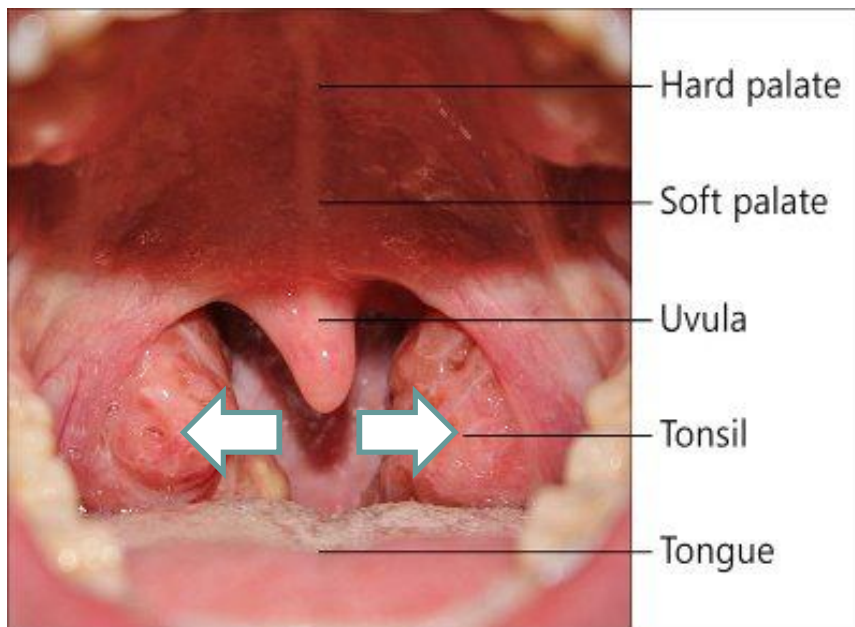
- A **lesion of CN XII** allows the contralateral, unparalyzed **genioglossus muscle** to pull the protruded tongue **toward** the paralyzed side (deviation of the tongue).

83. Gag reflex



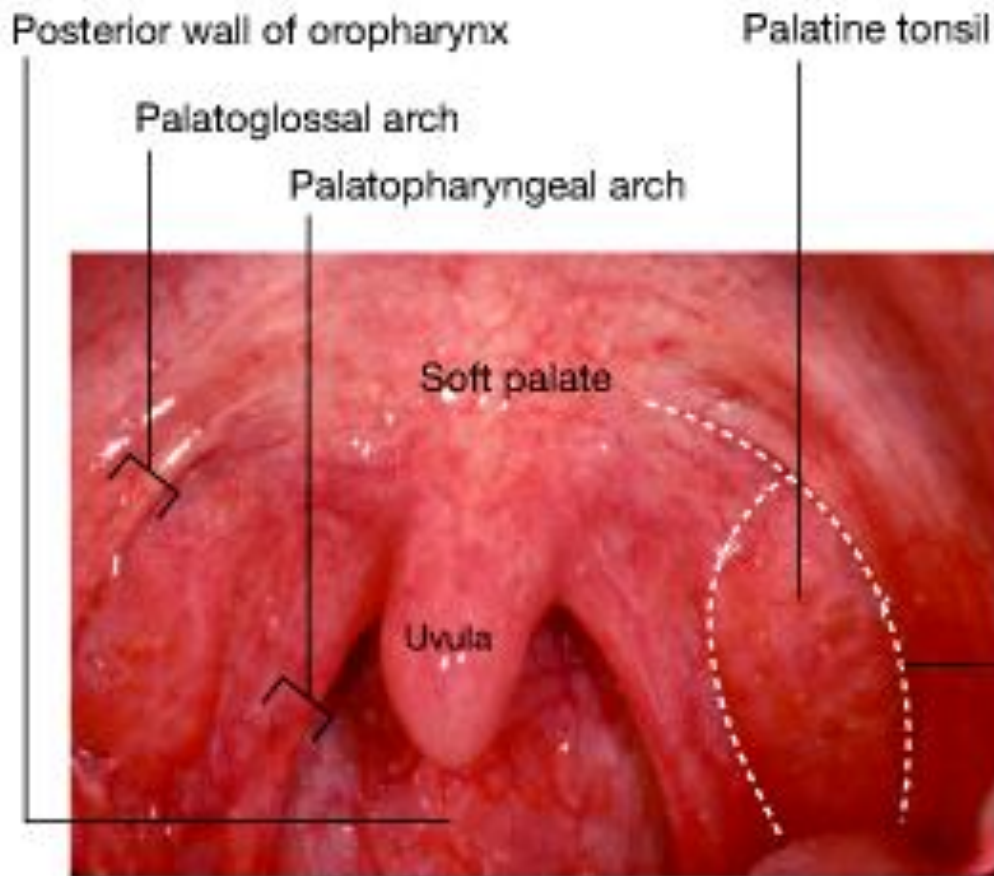
- Touching the posterior part of the pharynx results in muscular contraction of each side of the pharynx - **gag reflex**:
 - **Afferent limb: CN IX**
 - **Efferent limb: CN X**
- Injury to the **glossopharyngeal nerve (CN IX)** will result in a **negative gag reflex**

84. Tonsillitis



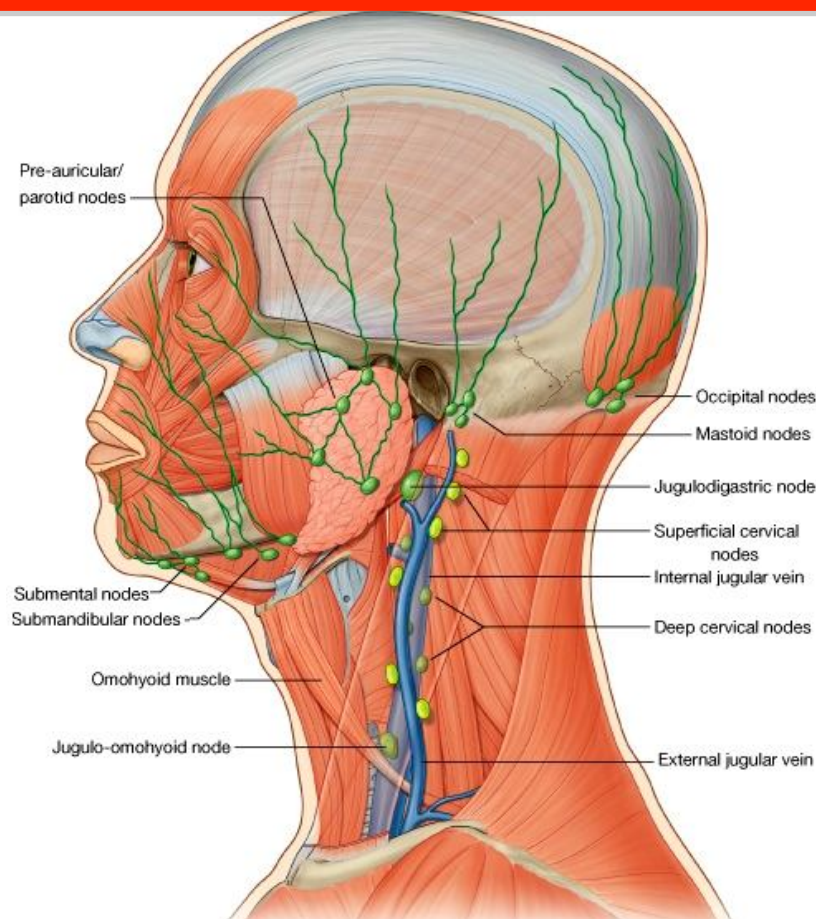
- During **palatine tonsillectomy**, the peritonsillar space facilitates tonsil removal, except after capsular adhesion to the superior constrictor.
- If the **glossopharyngeal nerve** is injured, **taste and general sensation** from the posterior 1/3 of the tongue are lost.
- **Hemorrhage** may occur, usually from the **tonsillar branch of the facial artery**; if the superior constrictor is penetrated, a high **facial artery** or tortuous **internal carotid artery** may be injured.

Palatine tonsils



- Receives **main blood supply** from **tonsillar branch of facial artery**
- Drained by **lymph vessels** mainly to **jugulodigastric lymph node**, which is **body's most frequently** enlarged lymph node
- **Nerve supply:** tonsillar plexus of nerves formed by branches of **CN IX** and CN X

85. Lymph drainage from face structures



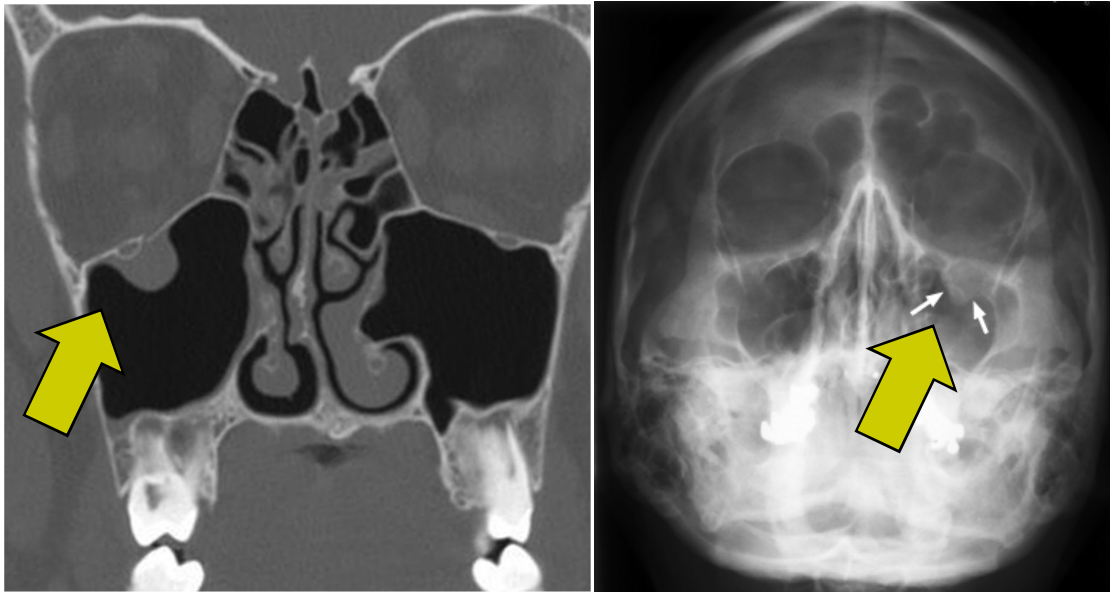
After **submandibular & submental** →
drain lymph to **Deep cervical**

Submandibular lymph nodes
receive lymph from:

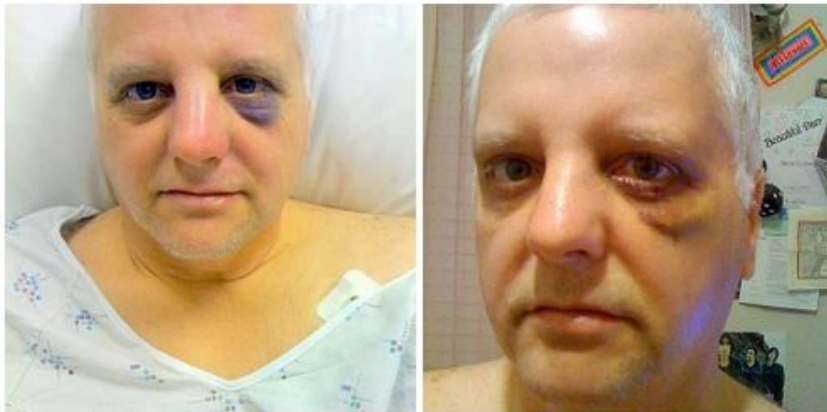- front of scalp
- nose and adjacent cheek
- upper lip and lower lip (**except central part***)
- frontal, maxillary, and ethmoid air sinuses
- upper and lower teeth (**except lower incisors***)
- anterior 2/3 of tongue (**except tip***)
- floor of mouth, gums and vestibule

***to Submental lymph nodes**

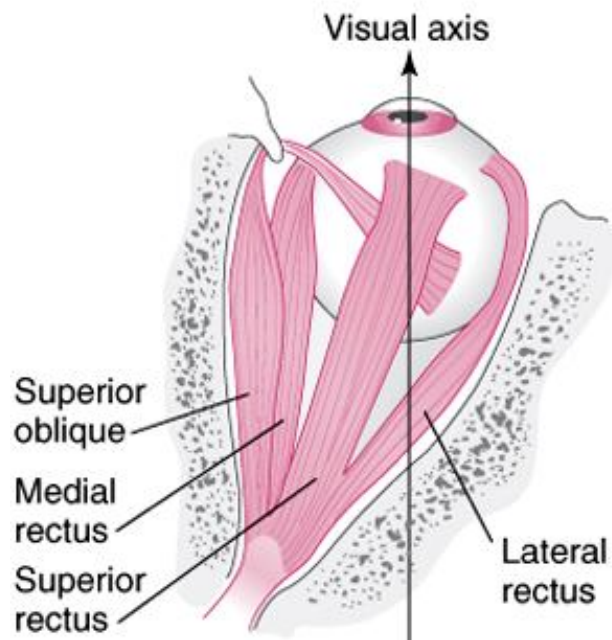
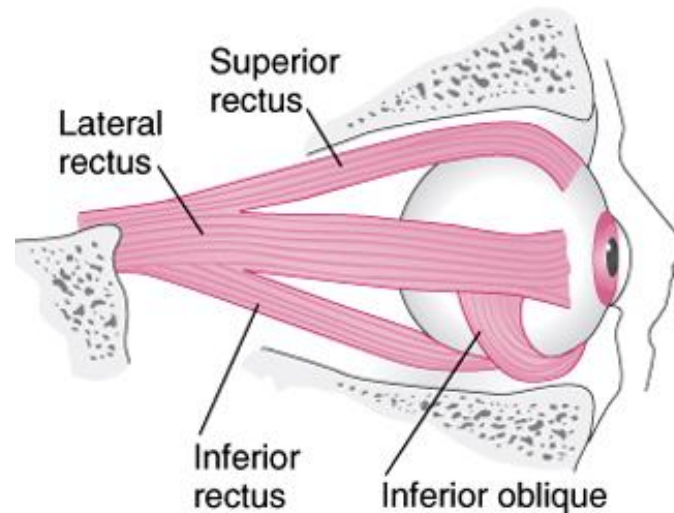
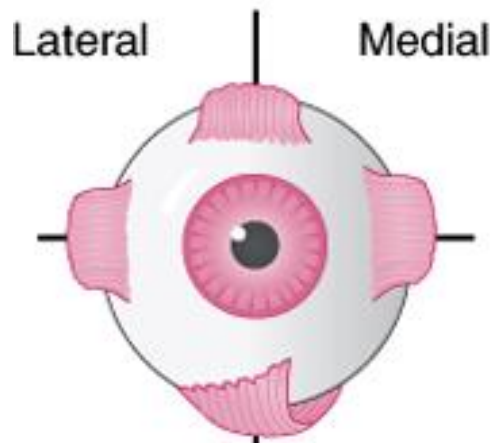
86. Blow-out fracture



- A blow-out fracture of the orbital floor typically is not involve the orbital rim and is caused by blunt trauma to the orbital contents (e.g., by a handball).
- Blow-out fractures may damage: inferior rectus muscle, infraorbital nerve and artery (hemorrhaging).
- Blow-out fractures are rare in **young children** because the maxillary sinus is small and the orbital floor is not a weak point.




87. Muscles of the orbit









Muscle	Action	Innervation
Superior rectus	Elevates and adducts pupil	CN III
Inferior rectus	Depresses and adducts pupil	CN III
Medial rectus	Adducts pupil	CN III
Lateral rectus	Abducts pupil	CN VI
Superior oblique	Depresses and abducts pupil	CN IV
Inferior oblique	Elevates and abducts pupil	CN III
Levator palpebra superior	Elevates upper eyelid	CN III

Clinical Testing Actions of Extraocular Muscles



isolate first, then test direction

Muscle tested		Direction to move eye when testing muscle
Superior rectus		Look laterally and upward
Inferior rectus		Look laterally and downward
Lateral rectus		Look laterally
Medial rectus		Look medially
Inferior oblique		Look medially and upward
Superior oblique		Look medially and downward

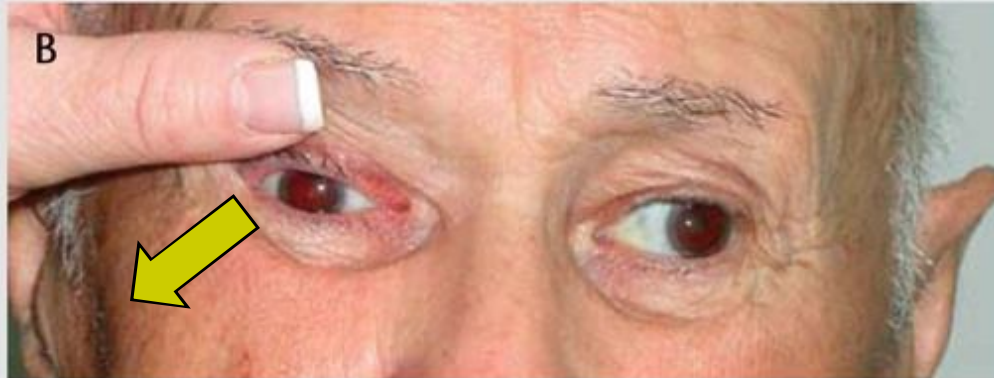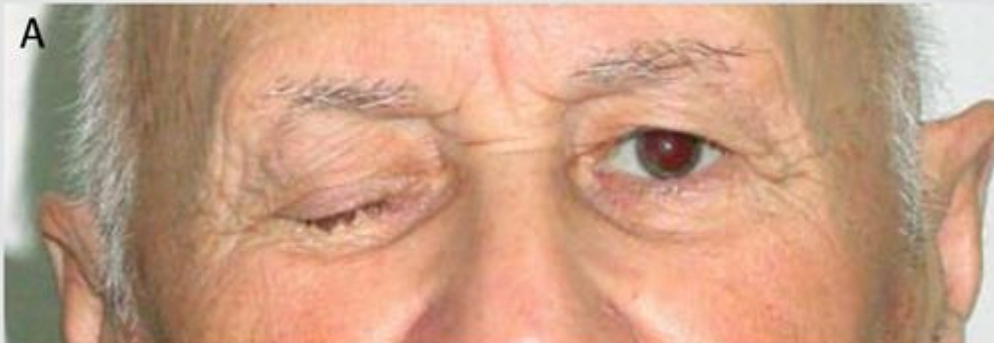- **Medial rectus** – ask the patient to look directly medially
- **Lateral rectus** – ask the patient to look directly laterally
- **Superior rectus** – ask the patient to look laterally, then superiorly
- **Inferior rectus** – ask the patient to look laterally, then inferiorly
- **Superior oblique** – ask the patient to look medially, then inferiorly
- **Inferior oblique** – ask the patient to look medially, then superiorly

❖ testing for eye movements where the single action of each muscle predominates

88. Oculomotor Nerve Palsy (external squint)

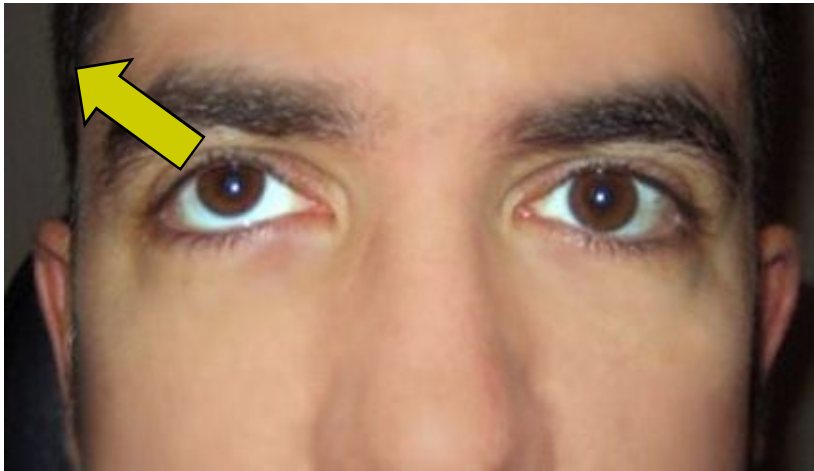


Symptoms consistent with palsy of third cranial nerve:
A) Complete right upper lid ptosis in primary position and B) complete limitation of adduction of the right eye on left gaze.



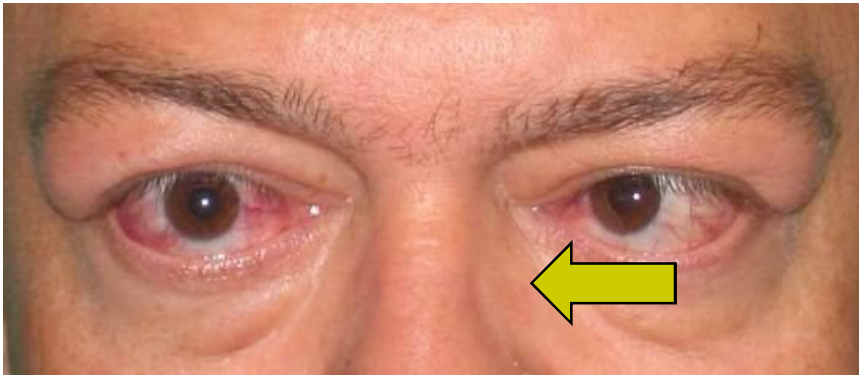- It affects **most** of the **extraocular** muscles
- **Manifestations:**
 - **ptosis**,
 - fully **dilated** pupil,
 - and eye is fully depressed and abducted (“**down and out**”) due to unopposed actions of superior oblique and lateral rectus, respectively.

89. Trochlear Nerve Palsy



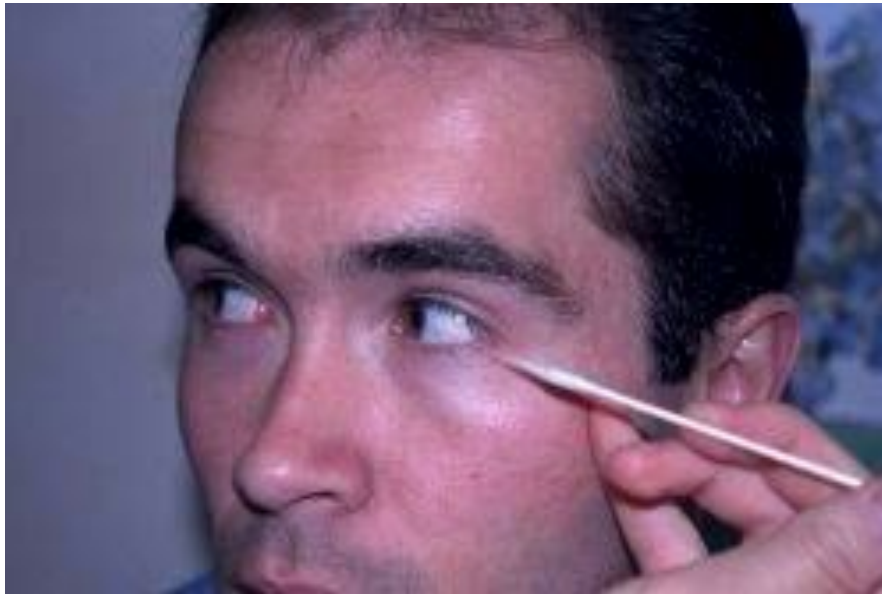- Lesions of this nerve or its nucleus cause paralysis of the **superior oblique** and impair the ability to turn the affected eyeball infero-medially (pupil look **superio-laterally**)
- The characteristic sign of trochlear nerve injury is **diplopia** (double vision) when looking down (e.g., when **going down stairs**)
 - The person can compensate for the diplopia by inclining the head anteriorly and laterally toward the side of the normal eye.

90. Abducens Nerve Palsy (internal squint)



- Injury to abducens nerve → paralysis of **lateral rectus** → inability to abduct the affected eye
- Affected eye is fully **adducted** by the unopposed action of the medial rectus that is supplied by CN III

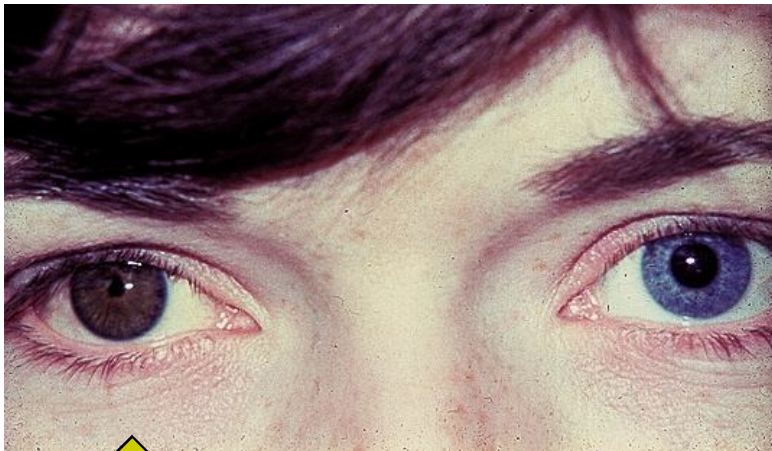91. Corneal reflex



- **Corneal reflex** (blinking) in response to touching the cornea
- It involves reflex connections between sensory **afferent fibers** in the **ophthalmic nerve (CN V1)** that make synaptic connections with **motor fibers** of **facial nerve (CN VII)** which supply orbicularis oculis muscle.

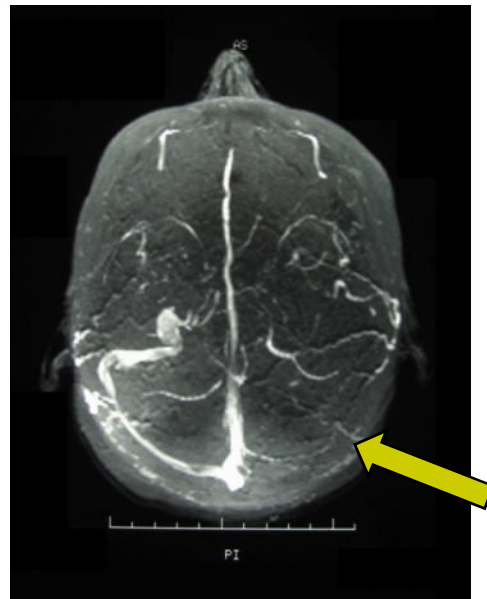
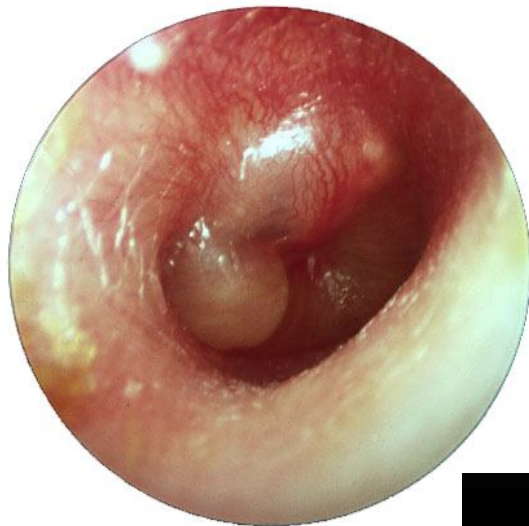
92. Horner syndrome



- Penetrating injury to the neck, **Pancoast tumor**, or **thyroid carcinoma** may cause **Horner syndrome** by interrupting ascending preganglionic sympathetic fibers anywhere between their origin in the upper thoracic spinal cord and their synapse in the superior cervical ganglion.
- It includes the following signs:
 - Constriction of the pupil (**miosis**)
 - Drooping of the superior eyelid (**ptosis**),
 - Redness and increased temperature of the skin (**vasodilation**)
 - Absence of sweating (**anhidrosis**)

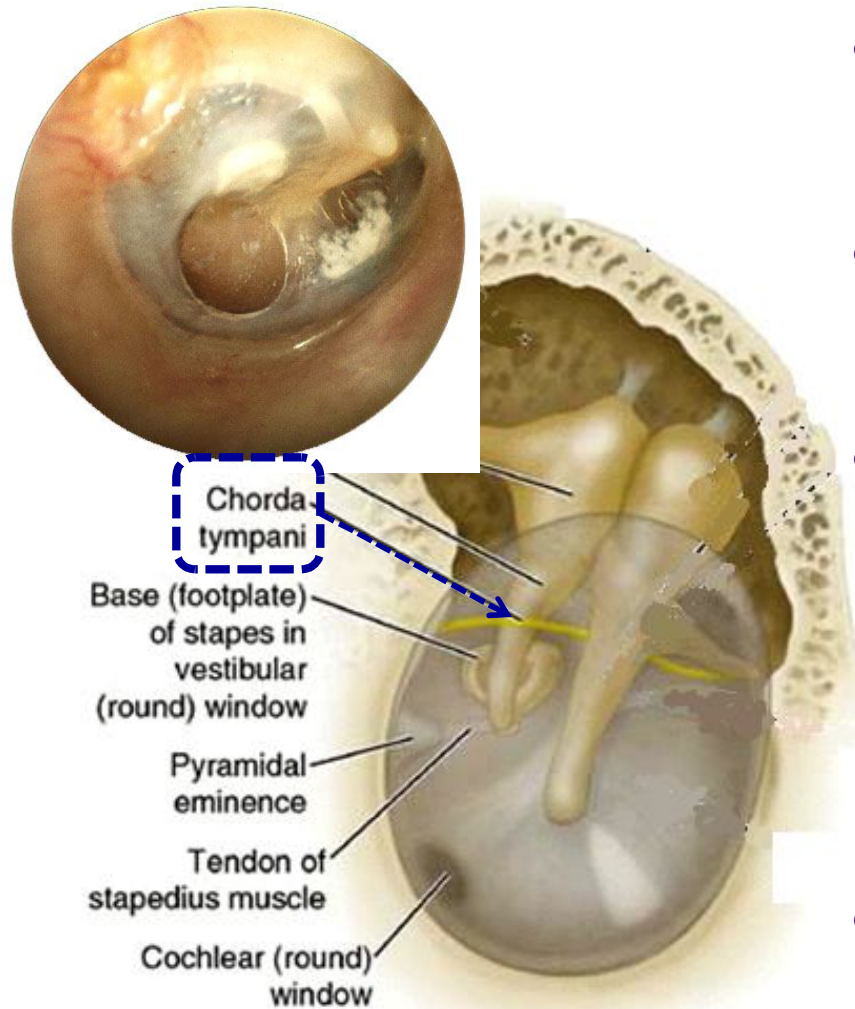
93. Otitis Media



- **Hearing is diminished** because of pressure on the eardrum and reduced movement of the ossicles.
- **Taste** may be **altered** because the **chorda tympani** is affected.
- **Infection** spreading **posteriorly** cause **mastoiditis**.
- **Infection** that spreads to the **middle cranial fossa** can cause **meningitis** or temporal lobe abscess, and **infection** moving through the **floor** may produce **sigmoid sinus thrombosis**.

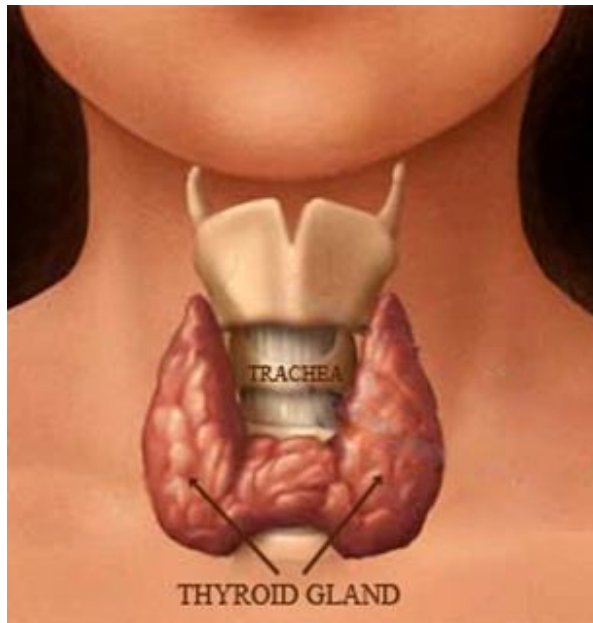


Perforation of the Tympanic Membrane



- May result from **otitis media** and is one of several causes of middle ear (conduction) **deafness**
- Causes: **foreign bodies** in external acoustic meatus, excessive pressure (as in diving), **trauma**
- Because **chorda tympani** directly relates to the posterior surface of the **tympanic membrane** it **may be damaged** and resulting in loss of **taste** over **anterior 2/3** of the tongue and secretion of the **sublingual** and **submandibular glands**
- Minor perforation heal spontaneously; large ones require surgical repair

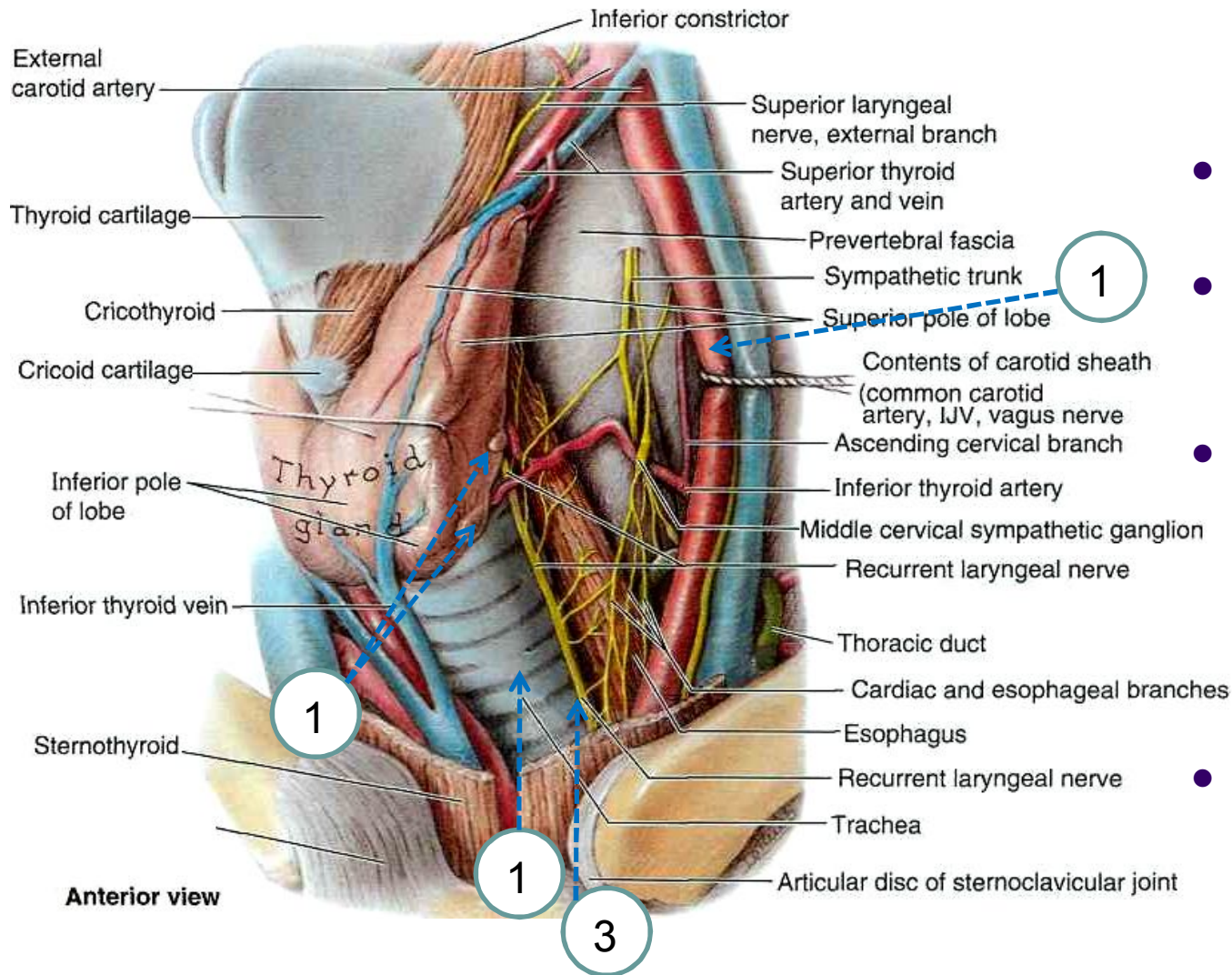
94. Thyroid and parathyroid glands



Hormones:

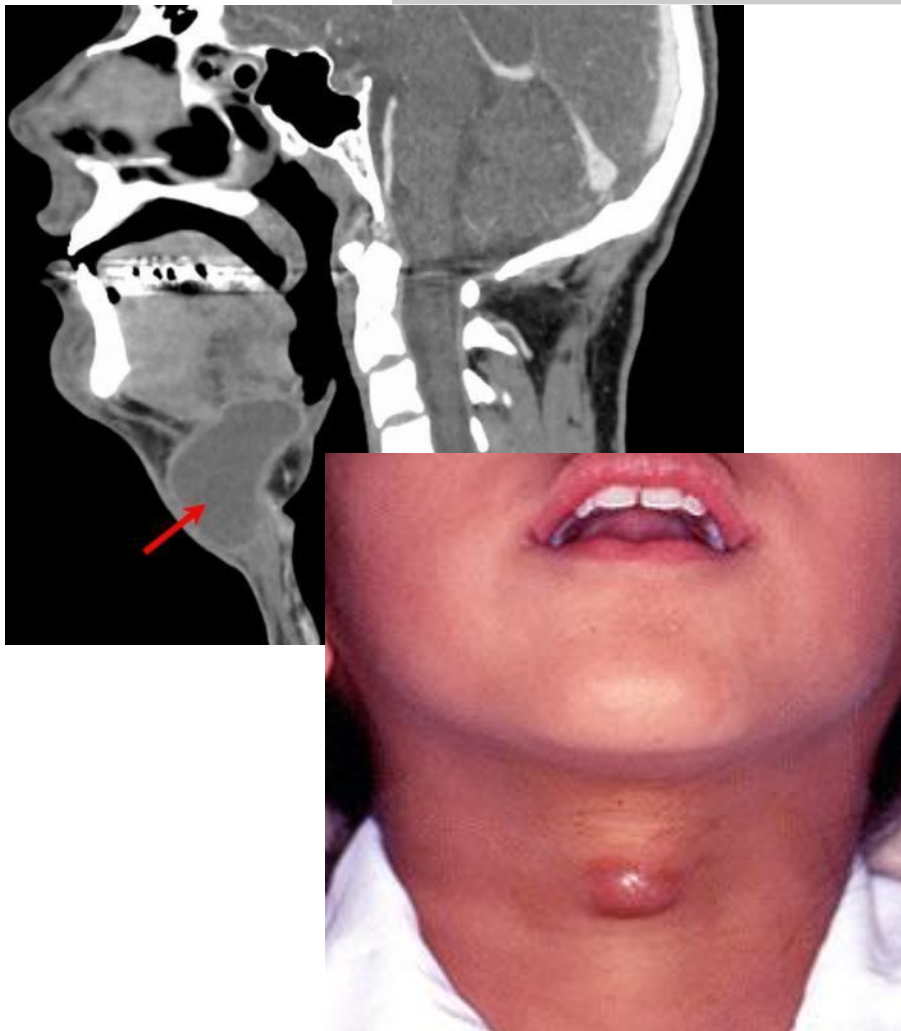
- The **thyroid gland** is the body's largest endocrine gland. It produces **thyroid hormone**, which controls the **rate of metabolism** (increase the temperature of the body), and **calcitonin**, a hormone controlling calcium metabolism (reduce blood calcium Ca^{2+}). The thyroid gland affects all areas of the body except itself and the spleen, testes, and uterus.
- The hormone produced by the **parathyroid glands**, **parathormone (PTH)**, controls the metabolism of phosphorus and calcium in the blood (increase Ca^{2+} level). The parathyroid glands target the skeleton, kidneys, and intestine.

Anatomical relations of the thyroid gland



- **Anterolateral** – infrahyoid muscles
- **Posterolateral** – common carotid artery [1]
- **Medial** – larynx, trachea [2], pharynx, esophagus, cricothyroid muscle, **recurrent laryngeal nerve** [3]
- **Posterior** – parathyroid glands [4]

Median cervical cyst

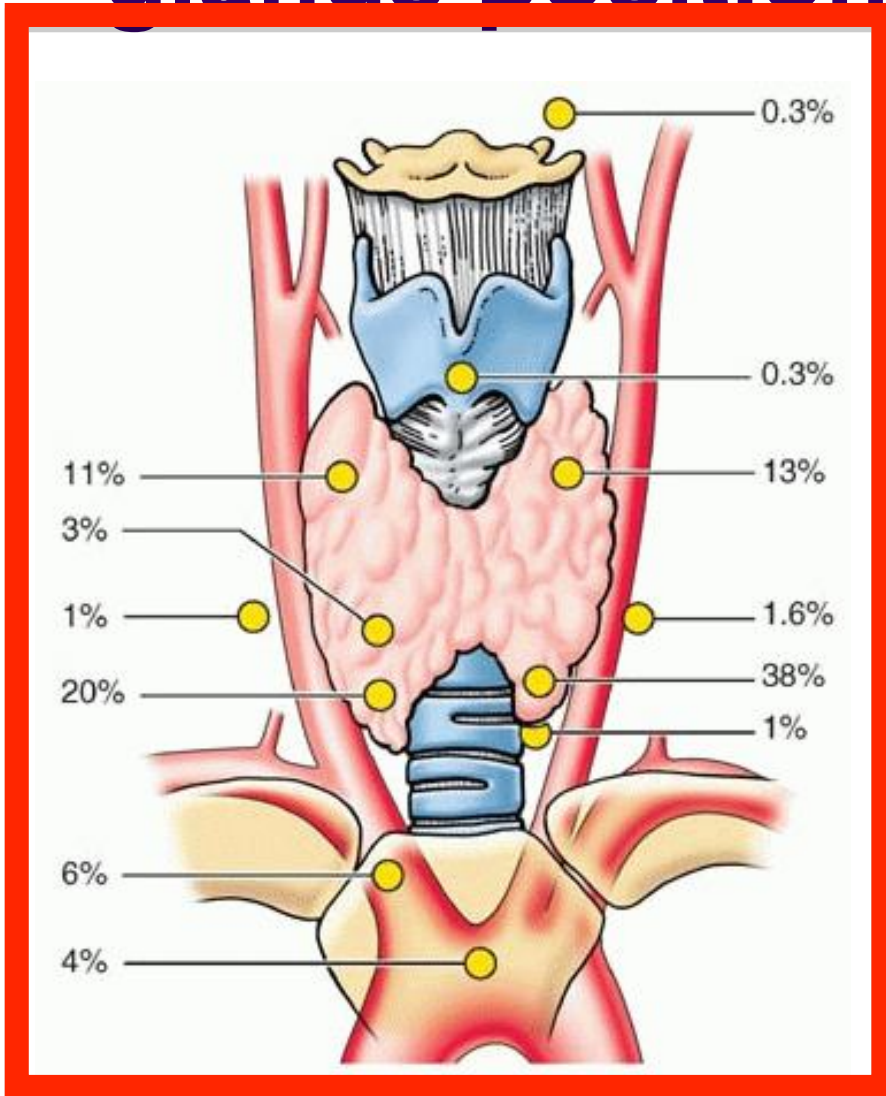


- Usually presents as a **painless midline mass** on the anterior aspect of the neck at the level of the hyoid bone and **moves during swallowing**.
- Remanent of the **thyroglossal canal** (thyroid gland originally from epithelium of the tongue).
- Must be differentiated from a thyroid mass
- Treatment: **surgical excision**

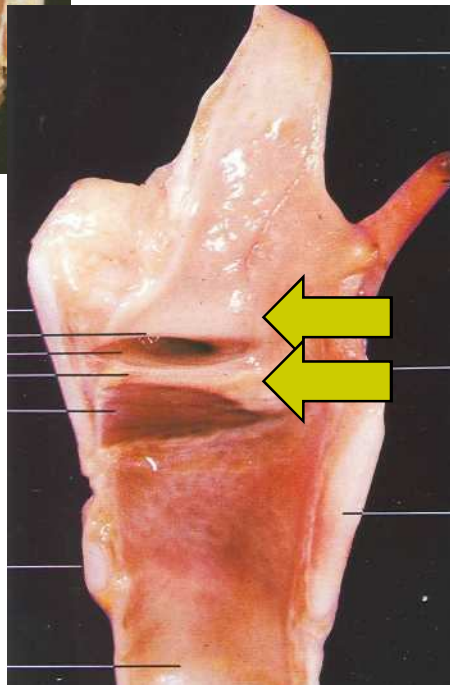
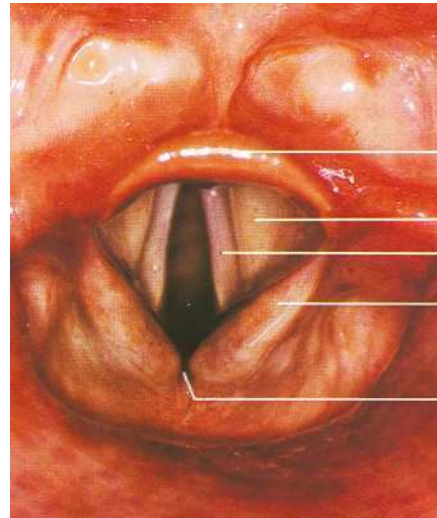
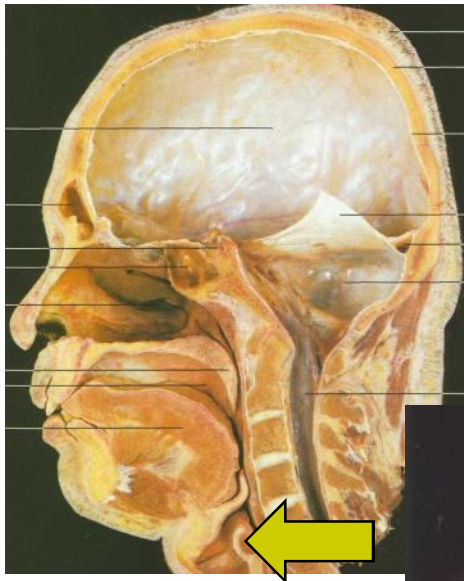
Variation of parathyroid glands position



- The **superior parathyroid** glands, more constant in position than the inferior ones.
- The **inferior parathyroid** glands are usually near the inferior poles of the thyroid gland, but they may lie in various positions
- In 1-5% of people, an **inferior parathyroid** gland is deep in the superior mediastinum **within the thymus** because of **common embryonic origin**.

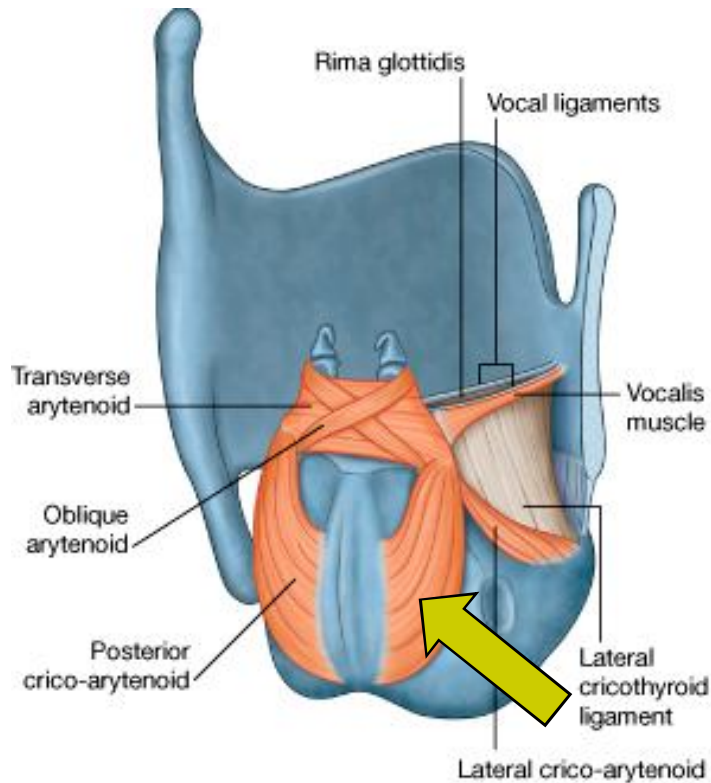


95. Larynx:



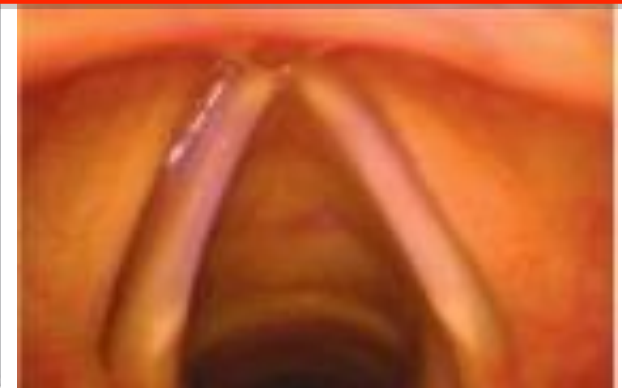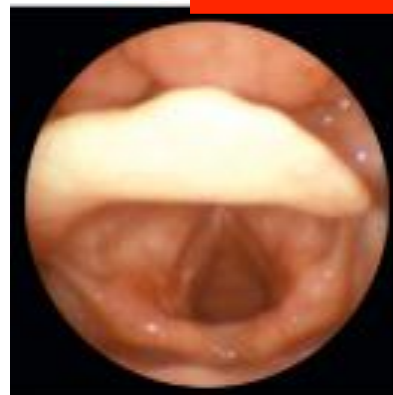
- Cavity of the Larynx - 2 Folds:
- **Vestibular folds** (false vocal cords)
- **Vocal folds** (true vocal cords)
- **Rima vestibuli** – gap between the vestibular folds
- **Rima glottidis** – gap between the vocal folds anteriorly and vocal processes of the arytenoid cartilages posteriorly

Muscles of the Larynx

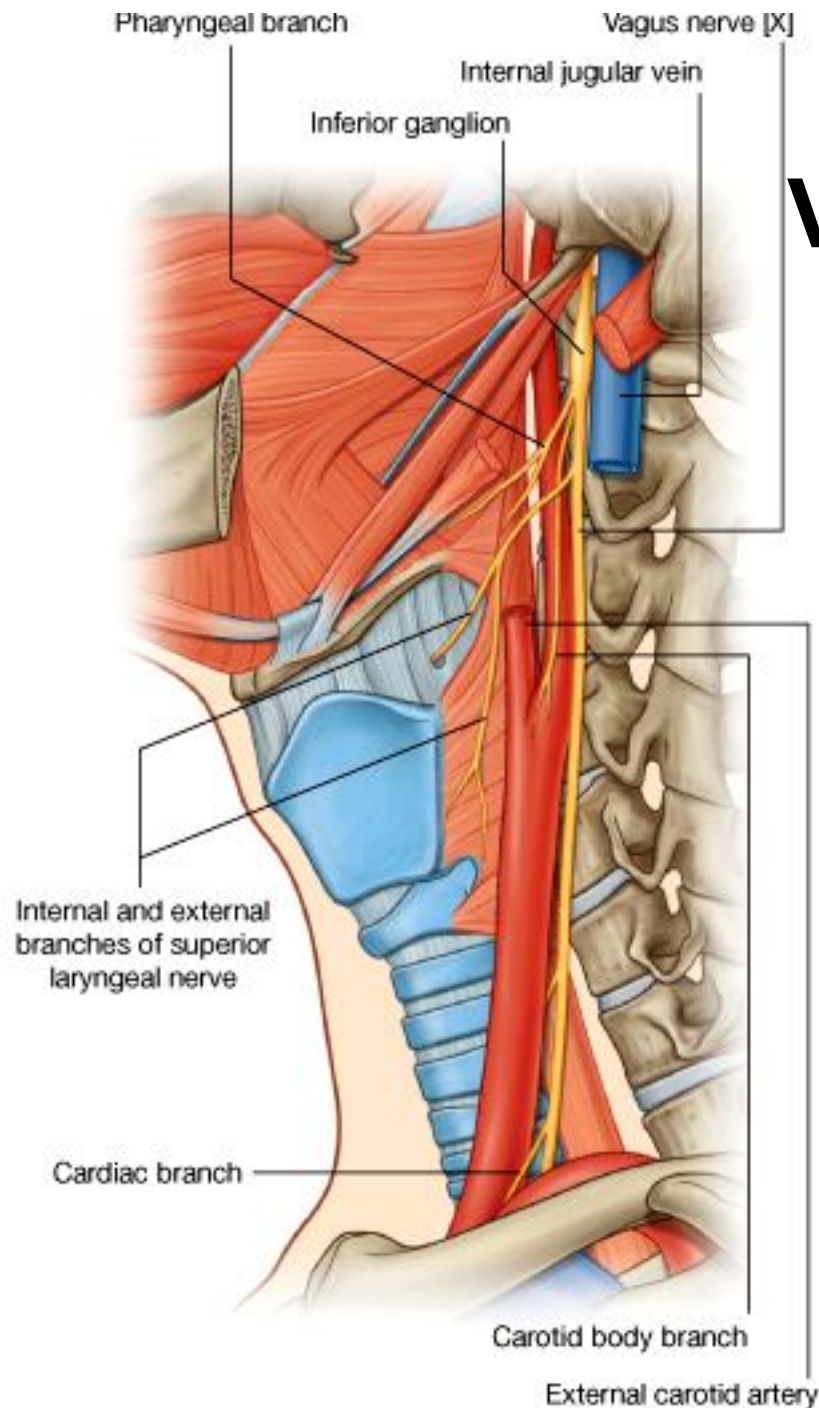


Abductors

- **Posterior cricoarytenoid** – abducts vocal folds (the only abductors of the vocal folds)



Vagus Nerve (CN X)



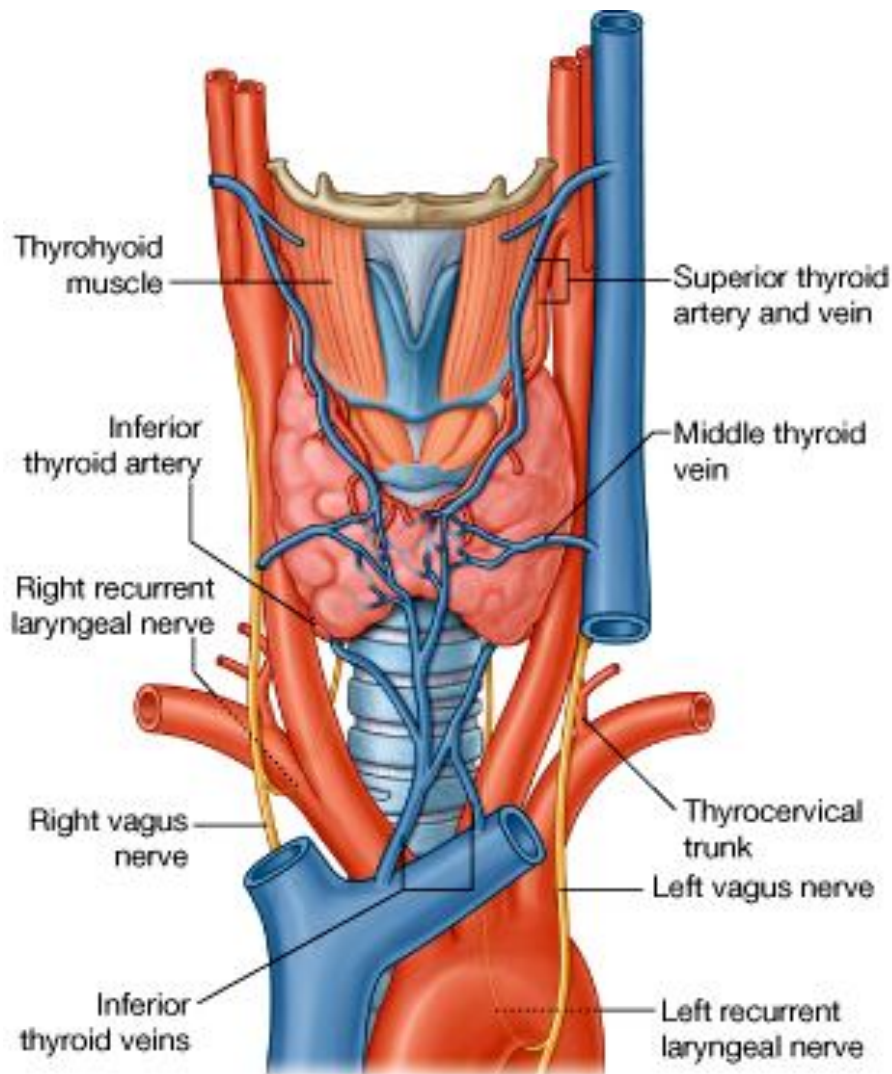
Superior laryngeal nerve:

divides into internal and external laryngeal nerves

- **Internal laryngeal nerve** – sensory; supplies floor of piriform recess and mucous membrane of larynx **above** of the **vocal folds**
- **External laryngeal nerve** – motor; supplies the **cricothyroid** muscle



Vagus Nerve (CN X)

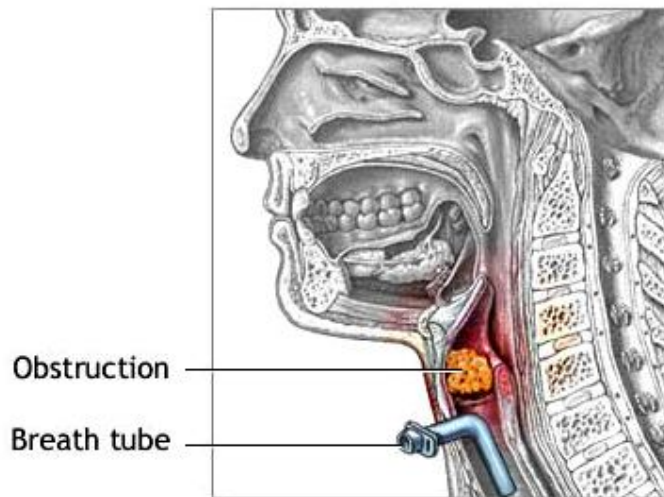
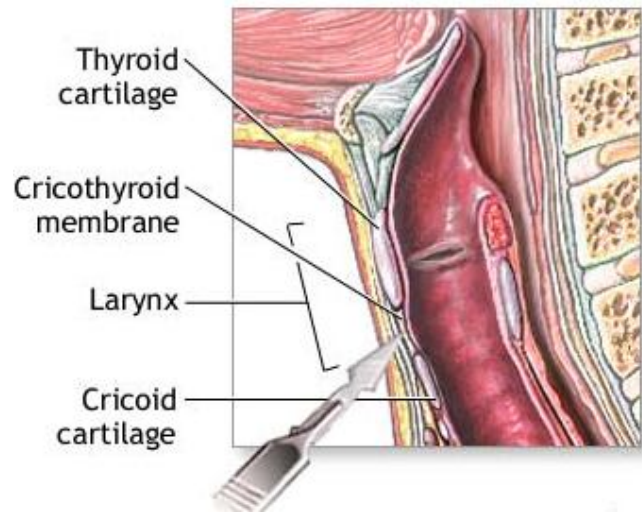


Recurrent laryngeal nerve:

- supplies **all muscles of larynx**, **except** cricothyroid; **mucous membrane** of larynx **below vocal fold**; mucous membrane of upper trachea
- **right recurrent laryngeal nerve** → hooks around the **right subclavian artery**
- **left recurrent laryngeal nerve** → hooks around the **arch of the aorta** posterior to the ligamentum arteriosum
- ascends in the neck in a **groove** between the trachea and esophagus

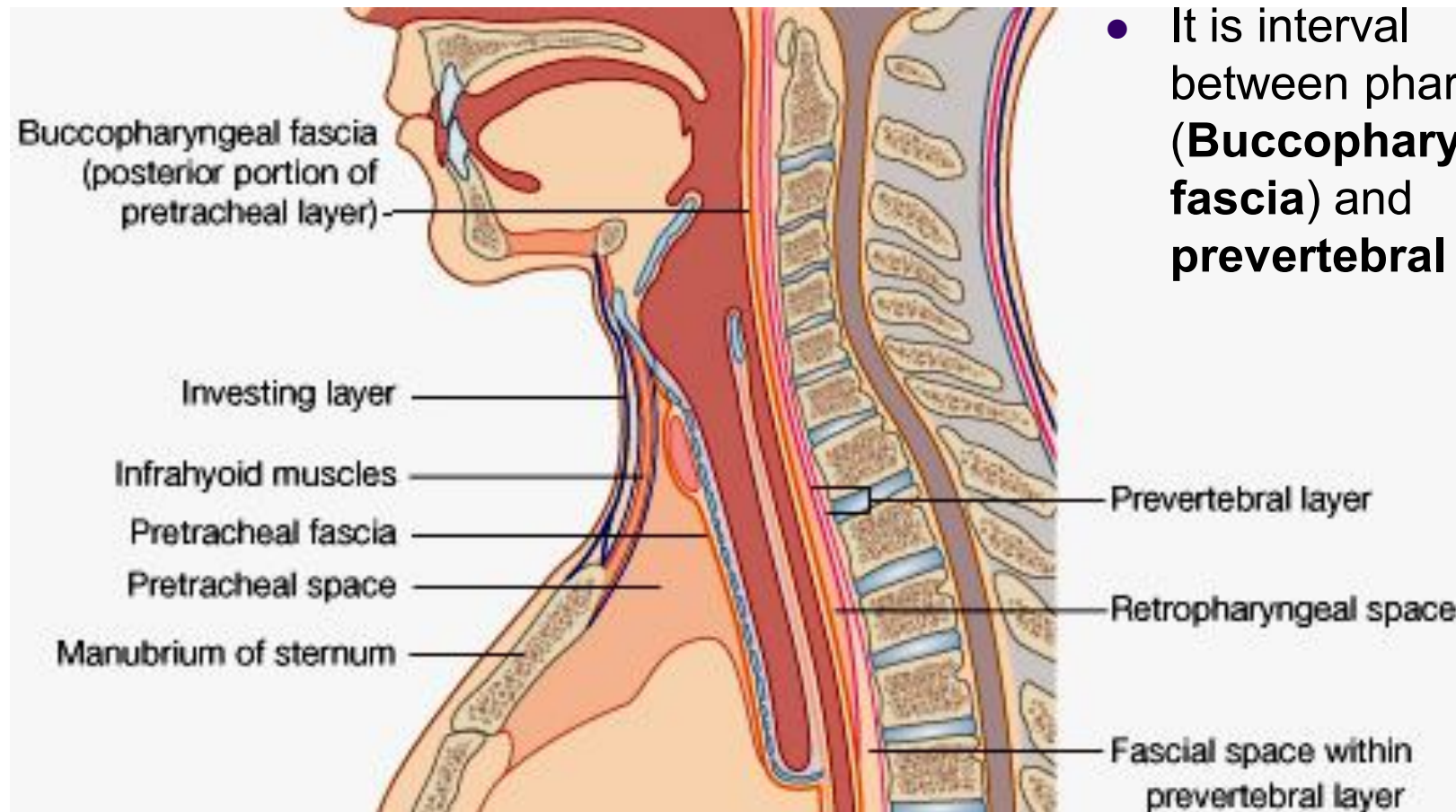


96. Cricothyrotomy



- A **cricothyrotomy** is an emergency procedure that relieves an **airway obstruction**.
- In case of swallowed **foreign bodies** or **abnormal tissue growths**.
- A hollow needle is inserted into the midline of the neck, **just below the thyroid cartilage** (needle cricothyrotomy).
- More frequently, a small incision is made in the skin over the **cricothyroid membrane**, and another one is made through the membrane **between the cricoid and thyroid cartilage**. A **tube** that enables breathing is inserted through the incision.
- Cricothyrotomy is generally followed by a surgical **tracheostomy**, if there is need for a prolonged use of a breathing tube.

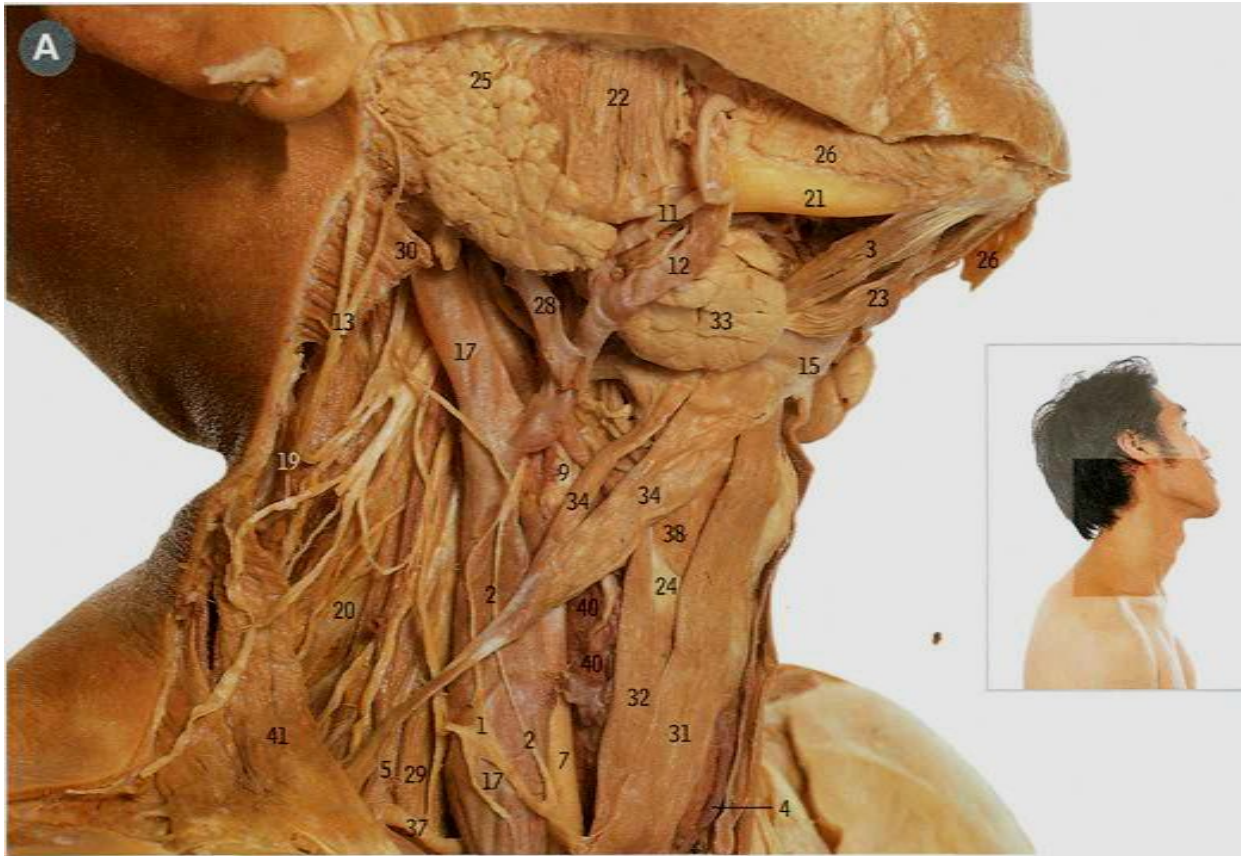
97. Retropharyngeal space



above thyroid, it is only
internal carotid, and
below is common carotid



98. Carotid sheath



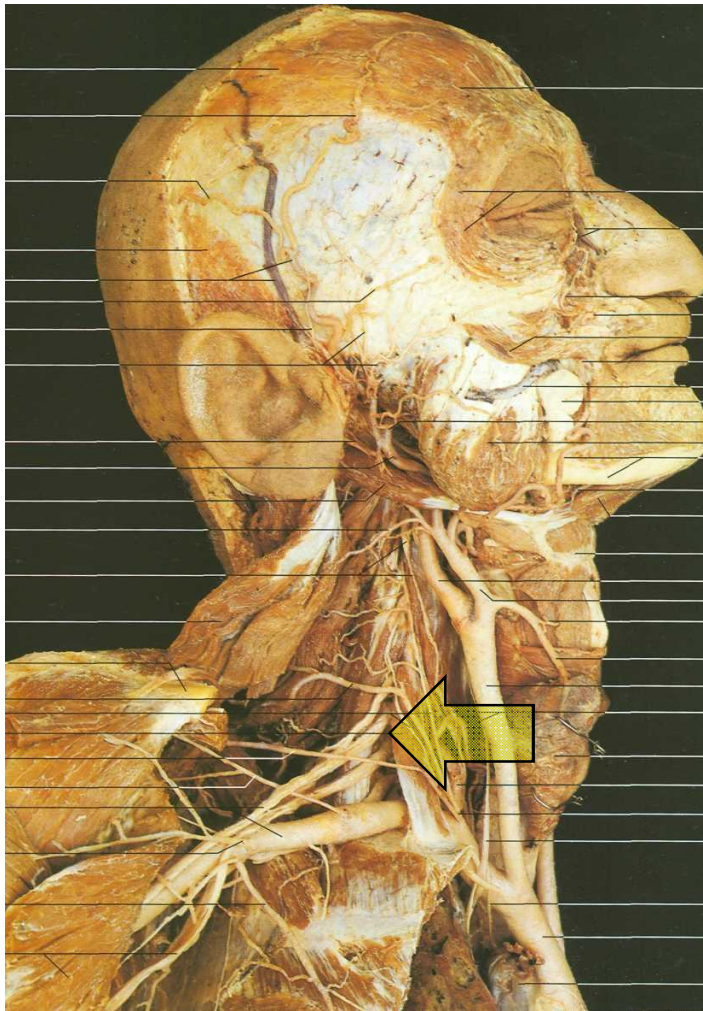
- Derived from all 3 layers.
- Encloses :
 1. **Common and internal carotid arteries**,
 2. **Internal jugular vein**
 3. **Vagus nerve**
- some deep cervical lymph nodes, carotid sinus nerve, sympathetic nerve fibers (carotid periarterial plexuses)

internal laryngeal accompany superior laryngeal artery

external laryngeal nerve accompaniyes superior thyroid artery

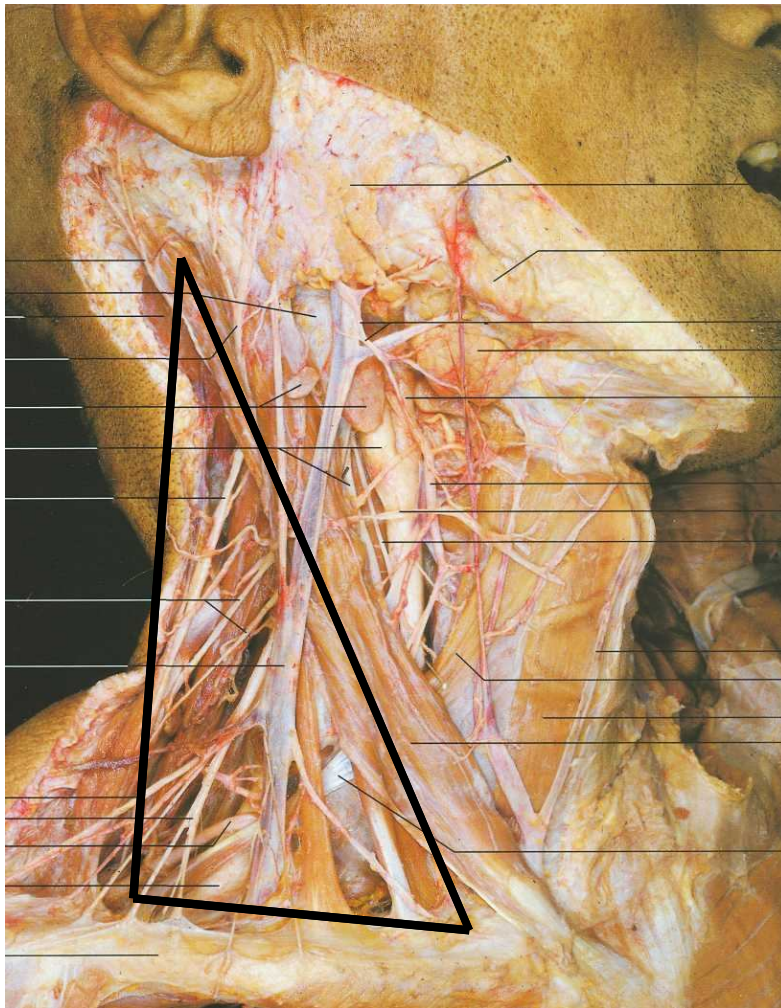

99. Axillary sheath



- Derived from the **prevertebral fascia**
- Encloses the **axillary vessels** and **brachial plexus** as they emerge in the interval between the scalenus anterior and medius muscles – **Interscalenus space**
- Extends into the axilla

100. Posterior Triangle of the Neck



Summary:

- **Scalene muscles**
- Veins – **external jugular vein**, **subclavian vein**
- **Arteries** – occipital artery
- Nerves – **accessory nerve (XI)**, **trunks of the brachial plexus**, branches of cervical plexus, **phrenic nerve**
- Lymph nodes – **superficial cervical** nodes along external jugular vein



Good Luck!



Dr. Mavrych, MD, PhD, DSc prof.mavrych@gmail.com